West Virginia University Libraries
3 0802 102296341 2

DENTAL INFECTIONS
AND THE
DEGENERATIVE DISEASES

WESTON·A·PRICE

The Library
Dental School
West Virginia University
A GIFT FROM
Dr. Claude H. Layman
Fairmont, West Virginia
DATE 1957

chap 21 - 34

DO NOT CIRCULATE

Digitized by the Internet Archive
in 2012 with funding from
LYRASIS Members and Sloan Foundation

http://archive.org/details/dentalin02pric

VOLUME II

RESEARCHES ON CLINICAL EXPRESSIONS OF DENTAL INFECTIONS

LIBRARY
DENTAL SCHOOL
W.V.U.

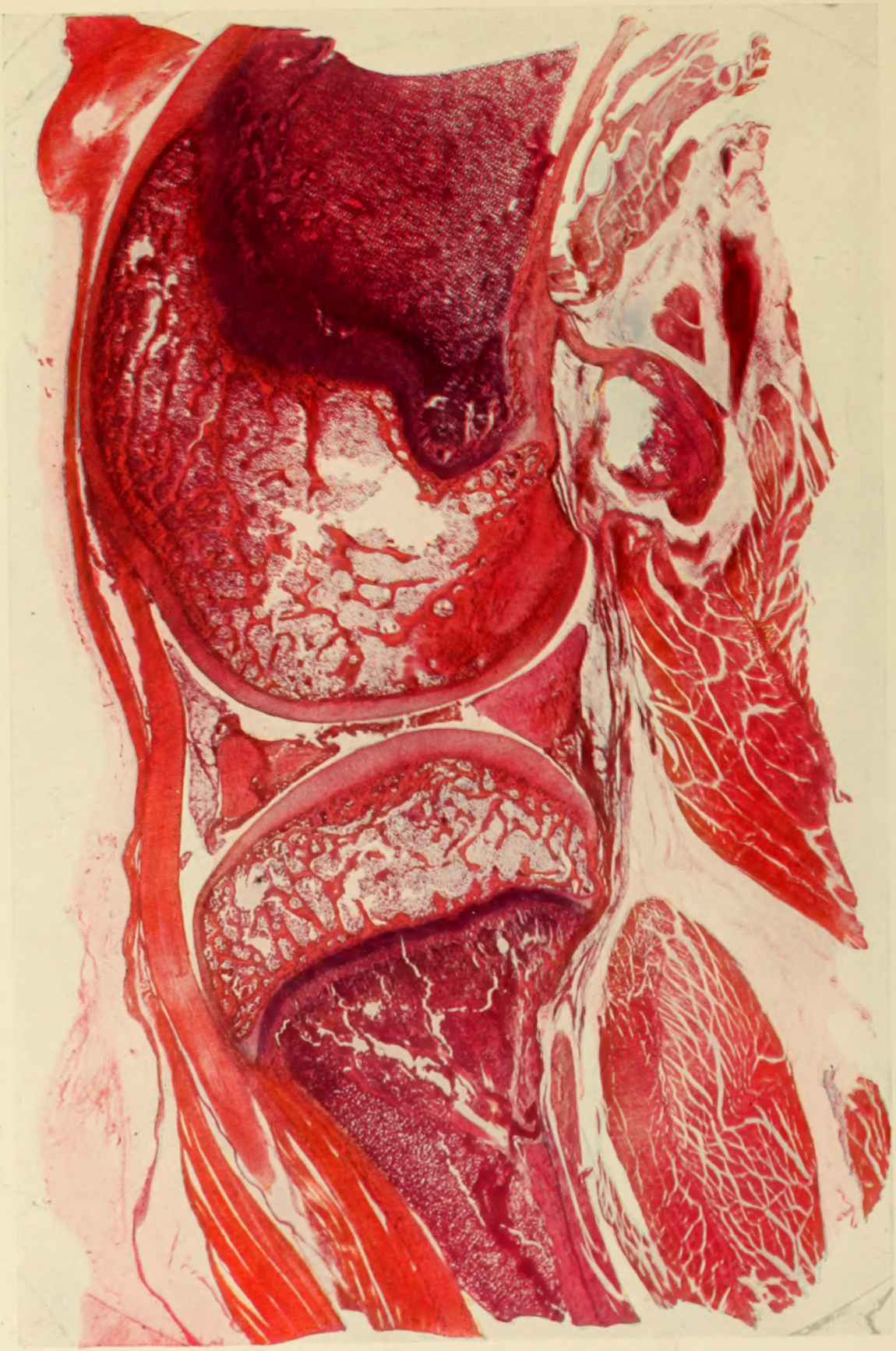

A—Cross section of normal knee joint of rabbit No. 1234.

Frontispiece Vol. II.

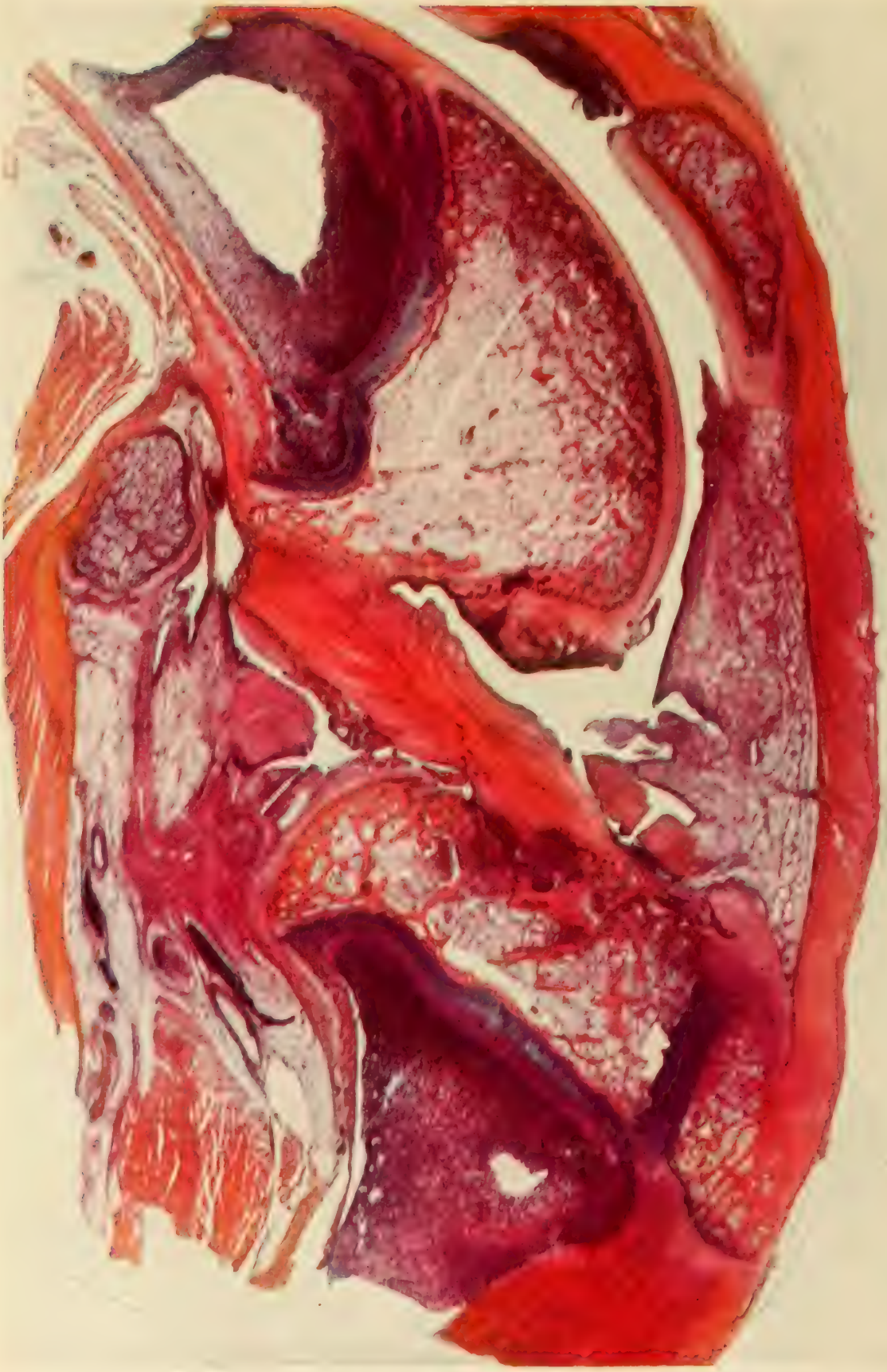

B—Cross section of arthritic knee joint of rabbit No. 1234

Frontispiece Vol. II.

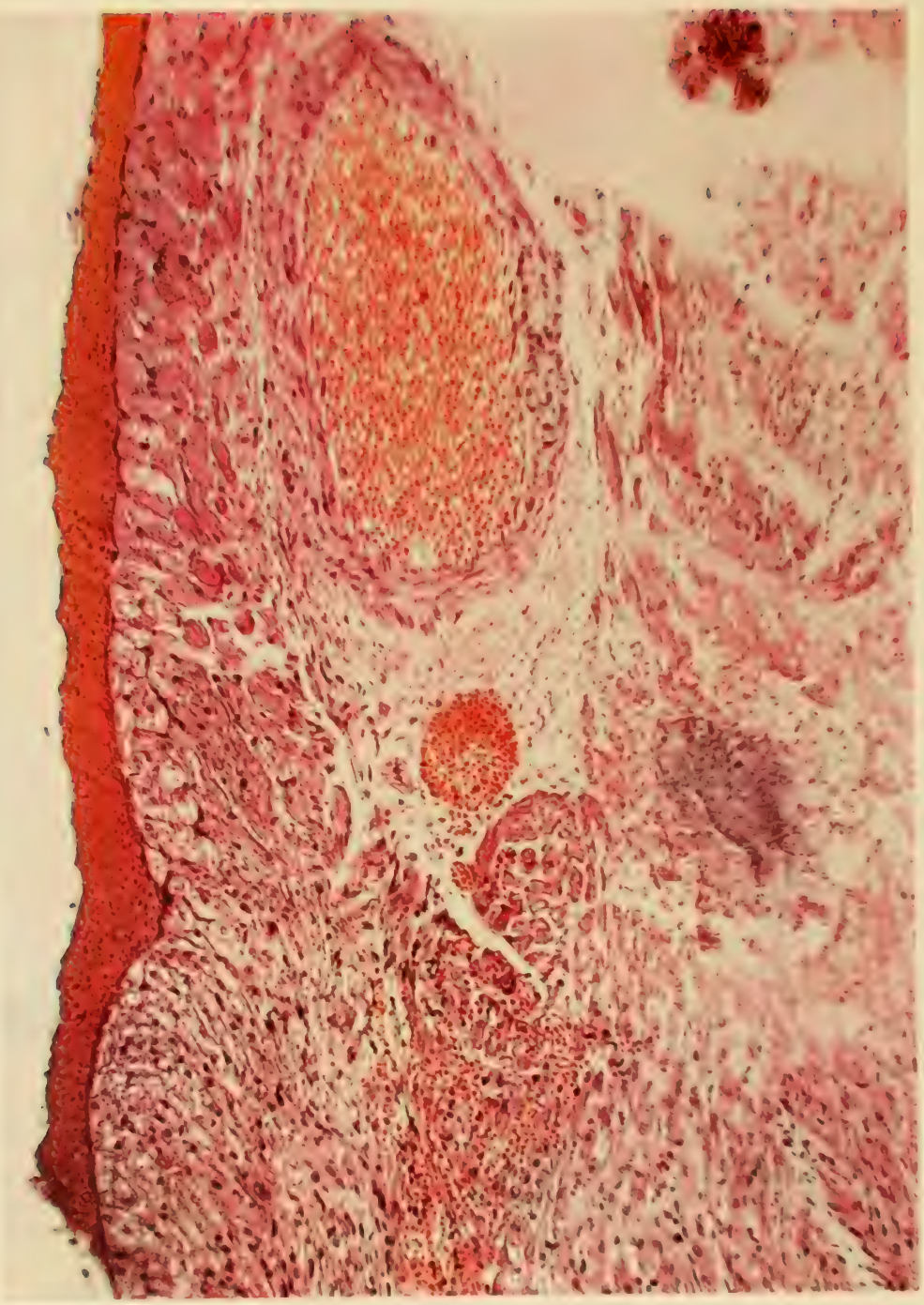

C—Spontaneous interstitial hemorrhage into heart muscle of rabbit, with death in twelve hours from dental culture. Case No. 1346.

Frontispiece Vol. II.

EXPLANATORY NOTES FOR FRONTISPIECES FOR VOLUME II.

A AND B, NORMAL AND ARTHRITIC KNEES.

In Volume I, I have illustrated two quite different types of arthritis, one the ***proliferative*** *type, characterized by marked proliferation, deformity, and ankylosis, the other, the* ***degenerative*** *tybe, characterized by degeneration without fixation but with deformity. Both types tend to destroy the joint cartilages, the first by proliferation changes, chiefly in the synovial membrane and perichondrium, and the second chiefly by degeneration of the body of the cartilage. In Frontispiece A, I have shown a section of a normal knee joint of a rabbit, in which will be seen the normal condition and arrangement of the various joint structures. In B will be seen the other knee of the same rabbit approximately two weeks after the development of an arthritic process resulting from injection into the ear vein of about two-thousandths of a gram of organisms, grown from a tooth. While this magnification is not high enough to show the minute tissue changes, it does demonstrate the gross structural changes. The plane is slightly different from that of the normal shown in A, as it includes the posterior cruciate ligament. The joint capsule was ruptured and the pus had extended into the fascia. The fixed film of congealed pus fell out of the section at the time of sectioning and was lost. There is marked destruction with necrosis of the joint capsule. The articulating cartilages have been practically destroyed, and it would be difficult, if not quite impossible, for this joint ever to return again completely to normal. This is a typical case of suppurative arthritis in the acute stage. (For detailed discussion, see Chapter 64 on Skeletal and Muscular System.)*

C. HEMORRHAGE INTO HEART MUSCLE.

In Volume I, in the chapter on Changes in the Blood Stream, I have demonstrated the ease with which cultures from dental infections may produce marked hematological and serological changes in the blood. These may involve marked change in clotting function of the blood, or produce changes in the walls of the blood vessels re-

sulting in multiple hemorrhages either in special tissues or throughout the body. In Frontispiece C, I have shown in color a section of the heart muscle of a rabbit which died in twelve hours from spontaneous hemorrhages following inoculation with a culture from the teeth of a patient suffering from both myocarditis and secondary hemorrhages. In the upper part of the illustration will be seen an artery in cross section normally filled with blood, the small spheres being blood cells, chiefly red. Note the three layers of the artery wall, the intima, media, and adventitia. Just below it will be seen an arteriole, or capillary, the wall of which has only a single coat, the intima, corresponding with the inner coat of the artery. At the lower part of this it will be noted that this membrane is ruptured and the blood cells are percolating through the tissues and between the muscle fibers as an interstitial hemorrhage. The patient was changed from a distressed invalid to a comparatively normal man by the removal of the dental infections. (*For further details, see Chapter 60 on Circulatory System.*)

DENTAL INFECTIONS
AND THE
DEGENERATIVE DISEASES

(VOLUME II)

BEING A CONTRIBUTION TO THE PATHOLOGY OF FUNCTIONAL AND DEGENERATIVE ORGAN AND TISSUE LESIONS

By

WESTON A. PRICE, D. D. S., M. S., F. A. C. D.

Specialist in Dental Research and the Diagnosis, Prognosis, and Treatment of Dental Infections.
Chairman Research Section of The American Dental Association, 1914 to present.
Organizer of The Research Commission of The American Dental Association. Organizer of The Research Institute of The American Dental Association
(Discontinued)

THIS IS THE CLINICAL ASPECT OF VOLUME I
"DENTAL INFECTIONS, ORAL AND SYSTEMIC"

VOLUME I PRESENTS
RESEARCHES ON FUNDAMENTALS OF ORAL AND SYSTEMIC EXPRESSIONS OF DENTAL INFECTIONS

VOLUME II PRESENTS
RESEARCHES ON CLINICAL EXPRESSIONS OF DENTAL INFECTIONS

From the Author's Private Research Laboratories
8926 Euclid Avenue, Cleveland, Ohio

THE PENTON PUBLISHING COMPANY
Scientific Publishers
PENTON BUILDING CLEVELAND, OHIO

Copyrighted 1923

WESTON A. PRICE, D. D. S., M. S., F. A. C. D.

CLEVELAND, OHIO

Printed in the United States of America

Printed by
THE PENTON PRESS CO.
Cleveland

With Deepest Gratitude and Sense of Indebtedness
for the Devoted and Loving Coöperation and Cheerful Sacrifices
of

My Wife and of Our Deceased Son, Donald,

Who, at Sixteen, Paid with His Life
the Price of Humanity's Delayed Knowledge
Regarding These Heart and Rheumatic Involvements
This Volume is Lovingly Dedicated

Etiology

"In Full Fair Tide Let Information Flow—
That Evil Is Half Cured Whose Cause We Know."

—*CHURCHILL: Gotham,*
B. 1. 2. 652.

TABLE OF CONTENTS—VOLUME II

PAGE

CHAPTER LVIII

INTRODUCTION TO CLINICAL APPLICATIONS OF NEW INTERPRETATIONS 19

CHAPTER LIX

APPLICATION OF PRECEDING EXPERIMENTAL DATA IN CLINICAL PRACTICE 43

CHAPTER LX

CIRCULATORY SYSTEM 54
- Endocarditis 55
- Bacteremia 62
- Raynaud's Disease 69
- Angina Pectoris 71
- Heart Block 73
- Hemophilia 73
- Chronic Carditis 79
- Myocarditis 83
- Carditis 104
- Phlebitis 108
- High blood pressure 111

CHAPTER LXI

RESPIRATORY SYSTEM 113
- Tuberculosis 113
- Dental Infections and Tuberculosis 118
- Streptococcal Pneumonia 124
- Head Colds 131
- Asthma 132

CHAPTER LXII

PRIMARY AND SECONDARY SEX ORGANS 135

CHAPTER LXIII

KIDNEYS AND RELATED EXCRETORY ORGANS 155
- Kidney 155
- Bladder 163

CHAPTER LXIV

SKELETAL AND MUSCULAR SYSTEM 172
- Deforming arthritis 175
- Osteomyelitis 200
- Myositis 203
- Cyst and muscle spasm 217
- Retained granuloma and rheumatism 222
- Osteomyelitis 227
- Spinal lesions 237
- Osteomalacia 240

CHAPTER LXV

PAGE

ALIMENTARY TRACT AND ASSOCIATED ORGANS 246
Stomach 246
Gall-bladder 252
Gall-stones 257
Intestines 258
Stomach 259
Intestines 263
Appendix 264
Stomach 266
Cancer of the stomach 267

CHAPTER LXVI

NERVOUS SYSTEM AND SENSE ORGANS 270
Neuritis 270
Central nervous system 273
Rheumatic neuritis 280
Mental cloud 283
Sleepiness 298
Sleeplessness 299
Neuritis 311
Nervous breakdown 312
Chorea 312
Nervous exhaustion 315
Loss of memory 321
Epidemic lethargic encephalitis 323
Eye 327
Exophthalmos and retinal hemorrhage 335
Ears 345
Obscure neuralgia 347

CHAPTER LXVII

SKIN 352

CHAPTER LXVIII

ENDOCRINE SYSTEM 357
Goiter 357
Pancreas 362

CHAPTER LXIX

OTHER TISSUES 364
Xerostomia 364
Oral herpes 375
Dental cysts 377
Apicoectomy 387
The repair of dentin and cementum 391

CHAPTER LXX

GENERAL DISCUSSION 396

CHAPTER LXXI

GENERAL SUMMARY 399

CHAPTER LXXII

GENERAL CONCLUSIONS 404

CHAPTER LXXIII

RESEARCH INSTITUTES FOR DENTAL DISEASES 406

LIST OF ILLUSTRATIONS—VOLUME II

PAGE

262-B. Granuloma-like defensive membrane constructed about the root of an infected tooth, implanted beneath the skin of a rat. Note its high vascularity and intimate contact with the root, which is being absorbed by it. Rats have relatively high defense for streptococcal infections 22

262-C. High powers of defensive reactions of the rat. A shows absorption of the cementum by cells with an osteoclastic and defensive function; B, these cells penetrating two foramina by chemotaxis 23

262-D. High power of one of the foramina of previous figure. Note the evidence of a common response to a general force—namely, chemotaxis—by which these cells are attracted to the toxins and the bacteria producing them. They are also able to function as osteoclasts. Each cell is a floating gland carrying antibody and antitoxin to neutralize the antigens and toxins produced by the bacteria. High defense in humans or animals, as demonstrated by this rat, is dependent upon the development and delivery of a large enough quantity of these defensive substances to carry the aggressive warfare to the immediate zone of the streptococcal invader, or as close as is physically possible, the limitation being the physical protection in the mechanical environment which is provided by an infected tooth structure, for the dentin of a single-rooted tooth contains approximately three miles of closed channels suitable for bacterial growth . 24

263 Roentgenographic appearance of teeth of Case No. 385 . 46

264 Photographic appearance of extracted teeth of Case No. 385. (See Figure 263).

265 Resistance and susceptibility history chart of Case No. 385. Note nine cases of heart disease in family, with four deaths . 49

266 Acute endocarditis in two rabbits from 1 cc. culture from deciduous teeth shown, from child with endocarditis . . 56

267 Fatal endocarditis in a rabbit inoculated with about one-millionth of a gram of organisms from the washings of crushed teeth from a patient with endocarditis. Heart shown in A; the teeth in C and D; B, an aortic arch involvement from another rabbit inoculated from two other teeth from same patient, shown in E and F 58

268 Two rabbits with endocarditis from the culture of the apparently normal tooth in the insert. Patient was prostrated by acute endocarditis 60

269 Streptococcal bacteremia: A, a degenerating granuloma of unusually large size, from the second molar shown in B. E, F, and G show organisms grown from the blood taken from the median basilic vein on three different occasions. C, organisms in the blood aspirated from the neck; and C, organisms in a phagocyting leucocyte 63

LIST OF ILLUSTRATIONS—*Continued*

		PAGE
270	Old Patrick. This rabbit lived for twenty-five and one-half months after one inoculation from culture from tooth, Figure 269. He developed first acute rheumatism, then deforming arthritis, had bowed legs, and walked on the sides of his feet	64
271	Other views of Old Patrick with his deforming arthritis. Notwithstanding his permanent deformity, he grew very large and heavy	65
272	Multiple lesions produced in rabbits from a case of recurring streptococcal bacteremia, Case 987	66
273	Others of the multiple lesions produced by the dental cultures from Case 987 with streptococcal bacteremia	67
274	Source of culture for inoculations from Case 987	68
275	Roentgenographic appearance of teeth, Case 1241 with angina pectoris. Patient apparently improved	70
276	Effect of implanting a tooth from Case 1241 beneath the skin of a rabbit. B, photograph of the encapsulated tooth. C, a photograph of this rabbit's heart. D, section of the heart muscle showing fatty degeneration. A, a section of the kidney, parenchymatous nephritis	72
277	Hemophilia. Case No. 1024. Roentgenographic appearance of the teeth. Note the absence of local reaction. Patient nearly dead from spontaneous hemorrhage, chiefly from gums, for three months, and most severe about root-filled teeth. See text	74
278	Spontaneous hemorrhage in rabbit, causing death in twenty hours, from culture from tooth, upper right third molar. See Figure 277	75
279	Spontaneous hemorrhages in rabbit's kidney and thigh. Case 1024. Many rabbits developed delayed clotting of blood from this culture. Patient greatly improved	76
280	Susceptibility history of patient and family. Case No. 1118	78
281	Roentgenographic view of teeth of Case No. 1118 with recurring heart involvement	80
282	Roentgenographic appearance of teeth of patient with myocarditis. Case No. 1346	80
283	High angle view of upper right cuspid shown in Figure 282. Note difference in periapical appearance	85
284	Section of heart wall of a rabbit which died in twelve hours from spontaneous hemorrhage from tooth culture of Case No. 1346. See also Frontispiece C	86
285	Spontaneous hemorrhages in thigh of one rabbit and psoas muscles of another rabbit. Tooth culture from Case No. 1346	88
286	Smear from the urine of Case No. 1346, showing many pus cells which entirely disappeared after the removal of dental infections	89
287	Roentgenographic appearance of teeth of Case 1335 with history of severe heart involvement	90

LIST OF ILLUSTRATIONS—*Continued*

		PAGE
288	Resistance and susceptibility record of family and patient of Case No. 1335. Note five deaths on father's side	91
289	Roentgenographic appearance of teeth of Case 1009, a severely suffering invalid with degenerative arthritis. Note difference in local structural change	94
290	A very severe myocarditis produced in the heart of a rabbit inoculated with culture from Case 1414. A, low power; B, medium power of focalization	98
291	High power of severe myocarditis produced in the heart of a rabbit inoculated with culture from Case 1414. Shows extensive necrosis, fibrosis, and vacuolization, which was not yet fatal when chloroformed	99
292	Dental conditions of Case No. 1415 with high defense shown in Figure 294	101
293	Dental conditions of Case No. 1414 with low defense shown in Figure 294	101
294	Comparison of bactericidal properties of two bloods: Case 1414, very low; Case 1415, very high. See difference in dental pathology in Figures 292 and 293	102
295	Two severe heart lesions produced in rabbits inoculated with culture from Case No. 1067: A, myocarditis with hypertrophy; B, endocarditis	105
296	Roentgenographic appearance of dental conditions of Case No. 1057, suffering from severe acidosis, with heart, stomach, and rheumatic involvements	106
297	Defensive reaction: A, encapsulated tooth chips; B, organisms in same; C, fibrous encapsulation tissue, very vascular	109
298	A severe case of phlebitis, produced in a rabbit's ear by inoculation with a culture from a tooth of a patient who had recently suffered from a severe attack	110
299	A dental cyst which produced a high blood pressure reaching above 220, completely relieved by its removal	111
300	Dental infections which produced a condition diagnosed as pulmonary tuberculosis. After their removal the patient gained fifty-four pounds	115
301	Roentgenographic appearance of teeth of Case 1153. Note absence of periapical absorption	117
302	Roentgenographic appearance of the dental infection producing a severe neuritis. Case 1120. Second molar has putrescent pulp	117
303	Streptococcal pneumonia. Upper view—lungs of rabbit with influenza, not fatal to rabbits. Lower view—lungs of rabbit with influenza plus inoculation with small amount of dental culture, causing death from pneumonia	127
304	A pneumonic lung with streptococcal pneumonia from the implanting of an infected tooth beneath the skin, shown also in position in this figure	130
305	Roentgenographic appearance of the teeth producing a sensitization reaction as acute recurring colds. Note extensive absorptions of both teeth and bone	131

LIST OF ILLUSTRATIONS—*Continued*

		PAGE
306	Roentgenographic appearance of teeth, a culture from which produced the ovarian and tubal infections in the next two figures	136
307	Acute ovarian infections produced in rabbits inoculated with cultures from teeth of patients suffering from same	137
308	Other ovarian involvements in rabbits from same culture. Case No. 1085	138
309	Several ovarian cysts produced from culture from teeth of a patient recently operated for ovarian cyst, shown in B, and cysts on the vas deferens from same culture	140
310	A very large ovarian cyst produced in a rabbit from a dental culture	141
311	Roentgenographic appearance of teeth of Case 1224, the culture from which produced the ovarian cyst shown in Figure 312. The patient had recently been operated for removal of large ovarian cyst	142
312	The sections of two rabbits showing ovarian cysts produced in from two to four days after inoculation with a culture from the teeth of Case No. 1224	143
313	A very purulent uterine and tubal infection produced in a rabbit from the dental culture from a patient suffering from a purulent uterine discharge which entirely disappeared after the removal of her dental infection	144
314	A deep indurated ulcer on the inner surface of the fallopian tube of the rabbit shown in Figure 313	145
315	The highly inflamed fallopian tubes, ovaries, and uterus of a rabbit inoculated with a culture from the teeth of a patient with syphilis	146
316	Acutely inflamed testicles, one from each of three rabbits inoculated from the cultures of three different teeth of a patient suffering from acute swelling and pain in testicles. He had previously had gonorrheal or syphilitic infection	147
317	The teeth from which the cultures were taken producing results shown in Figure 316	148
318	A helpless casting of multiple arthritis. She can scarcely move a joint in her body	148
319	Roentgenographic appearance of the teeth of the patient, Case No. 1269. This woman is a helpless bedridden cripple and severe sufferer, probably largely brought on by the overload of six pregnancies in seven years together with dental infections	151
320	A helpless bedridden arthritic cripple, with bed sores as large as half an orange. Her condition started during pregnancy late in life when she had chronic dental infections	153
321	Susceptibility study showing marked susceptibility to kidney involvement, including patient and four members of father's family. Case No. 692	156
322	Rabbit reactions to tooth implantations of case in previous figure. A and B, implanted teeth. C, cast in the rabbit's urine. D, organisms in the rabbit's blood. E, casts in the patient's urine. F and G, nephritic kidney sections	157

LIST OF ILLUSTRATIONS *Continued*

		PAGE
323	Tooth from patient with nephritis. See next figure	158
324	Tooth of previous figure beneath the skin of a rabbit produced a slight local reaction but rabbit developed acute nephritis, as shown in next figure	159
325	Section of nephritic kidney with pus cells	160
326	Acute interstitial nephritis produced in a rabbit. A and B, tissue sections showing cellular necrosis and edema. D, both kidneys of injected rabbit, five times normal size. See normal kidney to right, also hypertrophy of adrenals. C, casts from patient's urine. Case No. 573	162
327	Two of the teeth of previous case producing kidney involvement. Note condensing osteitis, not rarefying	163
328	Susceptibility of previous case, No. 573. Note four cases of death from heart involvement on mother's side	164
329	Teeth which produced acute and chronic cystitis, which promptly disappeared after their extraction	165
330	Paralysis of the bladder with retention, produced in a rabbit by dental infection. Bladder is twenty times its normal size, as shown in B. A shows deep ulcer on inner surface of distended bladder	166
331	Susceptibility chart of apparently normal patient. Note eight cases of death from Bright's disease on mother's side. Examination of patient showed same acutely developed, though unsuspected, at age twenty-eight	167
332	Hypertrophied kidney and casts from urine of a rabbit which developed severe nephritis in sixteen days from the implanted tooth shown, well encapsulated	169
333	Casts from urine of a rabbit dying in two days with kidney involvement, from the planting of an infected tooth beneath the skin	171
334	Typical illustration of streptococci and diplococci in joint fluids of animals inoculated with a dental culture	173
335	Chronic deforming polyarthritis. This woman was a bedridden cripple, completely helpless for six years. She now walks about her house without even a cane and does beautiful fancywork. Note condensing osteitis, not rarefying, about tooth. Case No. 709	174
336	Some of teeth of previous case of deforming arthritis, extracted seven years ago	176
337	Histological studies of periapical bone. A, photograph of trephined cylinder. B, histological section. Note density. C, roentgenographic appearance. Case No. 709	177
338	Acute purulent arthritis produced in rabbit from culture from tooth shown in C of previous figure. Case No. 709	178
339	Arthritis of the spine and hips of patient shown in A, and in spines and hips of rabbits inoculated with cultures from his tooth. Case No. 1125	179
340	Putrescent unfilled root of cuspid. Tooth had but slight apical absorption and no fistula	180

LIST OF ILLUSTRATIONS—*Continued*

		PAGE
341	Shows improvement in the movement of this man's spine in three months' time after extraction. A, limit of lateral movement at beginning. B, in three months. C, limit of forward and backward movement at beginning; and D, after three months	181
342	Susceptibility record of previous case, No. 1125. Note good inheritance; also in columns to right, duration of chief affection was less than that of the dental infection. Spinal disturbance followed an injury plus his focal infection	182
343	Extreme deforming arthritis produced in a rabbit inoculated with culture from the tooth shown in Figure 340, previous case, No. 1125	184
344	Case of deforming arthritis, bedridden for five years, progressively getting worse. So greatly relieved by removal of her dental infection and use of a vaccine that she now does her own housework and has for several years. Case No. 896	186
345	Roentgenographic appearance of teeth of previous case. This patient had the degenerative type of arthritis, not proliferative. Note difference in alveolar changes. An overgrown segment of mesial root of lower left first molar was uncovered by trephining. The bone changes are shown in the next figure	187
346	B, the overgrown root referred to in previous figure. A, section of bone showing original outline of trabeculae. C and D, concentric lamination obliterating a blood vessel	188
347	Various views of a rabbit paralyzed by an inoculation from dental culture from previous case, No. 896	189
348	Lesions of spine of rabbit shown in Figure 347. A and B, photographs showing diseased vertebrae. C, degenerative necrosis of vertebrae adjoining the spinal cord. D and E, roentgenographic appearance	190
349	Degenerative arthritis of hand of patient, Case No. 896, with dislocation due to shortening of flexor and adductor muscles	193
350	Acute deforming arthritis in boy seventeen years of age, bedridden much of the time for four years and crying by the hour with pain. Almost complete absence of alveolar absorption about putrescent teeth. Case No. 381	194
351	Same boy and some of his handiwork, now greatly improved but deformed for life. Is he happy?	195
352	Rabbit with acute rheumatism, inoculated with a culture from a putrescent lateral shown in B. Note the nearly complete absence of apical absorption	197
353	Susceptibility of the preceding case, No. 381. Note dominance of rheumatism on both sides of family	198
354	Roentgenographic view showing the free movement of mandible which before dental extractions was ankylosed closed	199
355	Extreme excementosis. Case 311 with carditis	201
356	Overgrown bicuspid root of Case 311	201
357	Osteomyelitis in a rabbit's hip, produced by the culture from the overgrown root tip shown in Figure 356	202

LIST OF ILLUSTRATIONS—*Continued*

PAGE

359 Roentgenographic appearance of a tooth with caries beneath a bridge which two years later produced torticollis on opposite side of neck of Case 455 207

360 About two years later, patient again suffered from torticollis and rheumatism. B shows putrescent lateral incisor apparently producing same; A, the patient's swollen wrist joints; D and E, rabbits with swollen feet and joints with acute rheumatism, inoculated with culture from putrescent lateral. C shows a lead bar in the tooth socket. Note the deceptive appearance of apical area of lateral in B 207

361 Osteomyelitis produced in rabbits from culture from tooth in previous figure: A, normal; B, pathological; C, section normal; D, section pathological 208

362 Susceptibility study of Case 1081. Note absence of inherited susceptibility factors 210

363 Roentgenographic appearance of teeth of Case 1081. Note zone of condensing osteitis surrounding rarefying, particularly of upper right second bicuspid, characteristic of a history of a broken high defense. Patient suffering from acute pain and lameness in right shoulder. 212

364 Four views of a rabbit inoculated with culture from the teeth of Case No. 1081. When under anesthesia these neck muscles relaxed. At right, section of the cord and cervical nerves. 214

365 Chronic degenerative myelitis of the spinal cord of rabbit of previous figure 216

366 Three sections of muscle tissue from neck of another rabbit suffering from torticollis 218

367 An acute involvement of the muscles of the neck and shoulders shown in D, related to the cyst shown in C and B. Operation followed by rapid and marked improvement. A, a paralyzed rabbit inoculated from culture of same 219

368 A section from the cyst wall of previous figure. Note osteoclastic activity 220

369 A photograph of the contents of the cyst shown in Figure 367. Large crystals are cholesterol 222

370 A small dental cyst before and after operation, possibly originally a dental granuloma 223

371 Roentgenographic appearance of an osteomyelitis of the maxilla following an extraction. See Chapter 43, Volume One . 228

372 Normal articulating surfaces of rabbit's knee. Note excellent condition of cartilages, capsule, and joint structures . . 232

373 Pathological articulating surfaces of rabbit's knee with acute rheumatism. Slightly different plane from previous figure. Note necrosis of posterior cruciate ligament and cartilages 233

374 Comparison of normal and arthritic knee joints of rabbits in nearly corresponding planes and different planes from the preceding figures: upper, pathological; lower, normal . 234

375 Severe spinal lesions produced in rabbits by the injection of cultures from dental infections 237

LIST OF ILLUSTRATIONS—*Continued*

		PAGE
376	Progressive development of a spinal disease resembling Pott's from inoculation of a dental culture	239
377	Three types of ossification: B, normal; A, proliferative arthritis; C, osteomalacia	241
378	Extreme tendency to periodontoclasia of patient suffering with osteomalacia. The systemic background makes this condition easily progressive and, therefore, resistant to treatment.	243
379	Two opposite types of reaction in cementum: A, hypocementosis with destruction of cementum in osteomalacia and severe periodontoclasia; B, hypercementosis with extreme excementosis in patient with broken defense	244
380	Susceptibility study showing marked inherited susceptibility from mother's side for neuritis, nervous breakdown, and stomach trouble. Case No. 965	247
381	Roentgenographic appearance of teeth of Case No. 965 with stomach and nervous disturbance	248
382	Acute stomach ulcer with near perforation, of a rabbit inoculated with culture from a tooth of Case No. 965 with stomach involvement	248
383	Postings from three rabbits inoculated with a culture from the teeth of a patient suffering from spontaneous hemorrhages. A, shows a complete perforation of a rabbit's stomach; B, a stomach just ready to perforate; C, a near perforation of colon	251
385	Digestive tract involvements of rabbit of previous figure: A, non-vital molar; B, gall-bladder involvement; C, acute appendicitis; D, an inflammatory invagination of the cecum into the colon	255
386	Serious dental infections with little local evidence, which contributed to a very severe cholecystitis. Case No. 445	256
387	Roentgenographic appearance of dental infections of a patient suffering from chronic cholecystitis. Following extractions, patient passed fifty-two gall-stones	258
388	Dental infections related to intestinal stasis and neuritis. Case No. 752	259
389	Susceptibility study of previous case, No. 752. Note five cases of acute stomach involvement on father's side, with two deaths	260
390	An enormous mandibular cyst with marked displacement of third molar, nearly to neck of condyloid process, producing colitis. Case No. 1019	262
391	Acute appendicitis produced in two rabbits in succession by planting of same tooth beneath the skin, taken from patient suffering from pain in vicinity of previous appendix operation	265
392	Internal and external appearances of acutely involved appendix of a rabbit with tooth implanted beneath its skin, from Case No. 1346 suffering from a digestive disturbance	266
393	Stomach ulcer produced in rabbit by tooth implantation, Case No. 1346 with stomach involvement	267

LIST OF ILLUSTRATIONS—*Continued*

		PAGE
394	A remarkable instance of inherited susceptibility for stomach involvement. Note six of patient's immediate relatives suffered from same, with three deaths	268
395	A dental infection which produced a tipping of the head, completely relieved by the extraction of the bicuspid. Case No. 110	270
396	Four rabbits were inoculated with the culture from the tooth shown in D, three of which were completely paralyzed from the centers of their spines backward, as shown in A, B, and C. Patient suffered from spasms. Case No. 1001	271
397	Paralyzed rabbit, A and B. C, an ulcer on inner surface of its bladder, shown in next figure	272
398	Site of lesion in spinal nerves in D. E, the paralyzed bladder twenty times normal size	274
399	Photographic appearance of ventral surface of spine, with one destroyed cartilage	275
400	Another paralyzed rabbit of this series. A, roentgenographic appearance of spine. Note condensing osteitis. B, compression of spinal cord by proliferative osteitis. C, external appearance of rabbit	276
401	Lesions in the cortex of the brain, rabbit which developed acute choreic nervous symptoms, shown in Figure 347	278
402	Roentgenographic appearance of the teeth of Case No. 484; patient suffering with rheumatic neuritis and heart, with extreme muscle atrophy	281
403	Susceptibility record, Case No. 484. Note the strongly inherited susceptibility for heart and rheumatism, with four deaths from stroke	284
404	Susceptibility record of Case 1178. Note strongly inherited susceptibility for stomach involvement and neuritis	286
405	Roentgenographic appearance of teeth of Case 1178. Note limited periapical absorption about lower first molars. Patient suffered from extreme nervousness	288
406	This Rabbit 716 carried or dragged its hind leg from a culture from the tooth shown on opposite page. See next figure	289
407	A series of roentgenographic views of progressive development of hip disease in Rabbit 716, shown in previous figure. Culture from tooth in Case 1178	290
408	Photographic appearance of heads of femurs on posting, Rabbit 716	291
409	Enlarged views of normal and diseased femurs of Rabbit 716 from Case No. 1178	291
410	A smear showing diplococci in pus from hip joint of Rabbit 716	292
411	Rabbit 710, which developed paralysis of hind legs from dental culture from Case 1178	292
412	Roentgenographic appearance of lesion in the spine of paralyzed rabbit, 710. Case 1178. A, lateral view while living. Note condensing osteitis. D, C, and B, ventral and lateral views. Note condensing osteitis	293

LIST OF ILLUSTRATIONS—*Continued*

		PAGE
113	Smear from kidney of rabbit with nephritis from dental infection, showing pus cells and streptococci	294
114	Central nervous system changes in Rabbit 632 with chorea, nystagmus, torticollis and gyratory movements: A, a focalization in cerebellum of brain; B, fatty degeneration in gray matter of cord	295
115	Lesions in the aortic arch of Rabbit 422	297
116	Typical degenerative arthritis of joint capsule of Rabbit 624	298
117	Roentgenographic appearance of teeth of Case 1273 with extreme sleepiness	300
118	Dental conditions of Case No. 557, with violent spells of insanity coming on as sleeplessness	300
119	Susceptibility record of Case No. 557, with insanity and marked inherited susceptibility to nervous breakdown, and mental cloud	302
120	Dental conditions of Case No. 402, with nervous disturbance as crying	304
121	Roentgenographic appearance of teeth of Case 1139	304
122	Dental condition of Case No. 1082. Mild insanity greatly improved by removal of dental pathological condition	307
123	Susceptibility record of Case 785, with sciatic rheumatism and heart. Note marked hereditary susceptibility, with five deaths from heart involvement on father's side and one case on mother's side	308
124	Dental conditions of Case No. 1139, suffering with acute neuritis, completely relieved by removal of dental infections	310
125	Dental condition of Case No. 805, booked for an insane asylum as a bedridden invalid with palsy. Remarkable relief from removal of her dental infections	310
126	Infected deciduous molars, without roentgenographic evidence of same, which were producing chorea in a child. Case No. 1402	315
127	Roentgenographic appearance of teeth of Case No. 335, with hysteria and lassitude. See next figure	316
128	Susceptibility record of Case No. 335. Suffered acute lassitude, hysteria, heart, and rheumatism. Note ten cases of heart involvement in family	318
129	Dental condition of Case No. 1365, suffering with attacks of extreme loss of memory. These were occurring with increasing severity and frequency. Very marked relief upon removal of dental infections	320
130	Dental conditions of Case No. 1317. Patient suffering from lethargic encephalitis	324
131	Dental conditions of Case No. 904, with acute inflammation of the sclera and retina of the right eye	326
132	Dental conditions of Case No. 1087, with complete blindness in right eye, left eye one-fifth normal	326
133	Progressive involvement in rabbit's eye, from dental culture from Case 904 with retinitis	328

LIST OF ILLUSTRATIONS—*Continued*

PAGE

434 Of five rabbits inoculated with culture from teeth of Case 904, four developed acute eye involvement. Two shown below have ulcers, and two above acute infection of musculature. 329

435 Very extreme excementosis of a molar root, Case No. 1087, with a history of glaucoma resulting in complete blindness of one eye and one-fifth vision in the other. Vision progressively diminishing. Marked improvement following removal of dental infection 330

436 Acute conjunctivitis in rabbit, produced by culture from infected tooth in D, from Case No. 899 with chronic eye irritation and hip involvement 332

437 Extreme eye involvement of Case No. 861. B, C, and D, dental conditions. E and F, progressive stages of acute involvement in rabbit's eye, inoculated with culture from these teeth 334

438 Marked bulging of the eyes, Case No. 1008, as seen in A. Eyes returned to normal in a few weeks' time, as shown in B . 336

439 Roentgenographic appearance of teeth of previous case, No. 1008 337

440 Very marked pulp degeneration, with multiple pulp stones of pyorrhetic teeth of previous figure. Case No. 1008 . . 338

441 Three rabbits which developed acute exophthalmos following inoculations with dental cultures from preceding case, No. 1008 339

442 A ruptured blood vessel in patient's eye, shown in A, with hemorrhage into sclera. B, a hemorrhage into the eyeball of a rabbit from culture of tooth. C, hemorrhage into periosteum and muscles 340

443 An acute involvement of both eyes of patient shown in C. A, normal eye of rabbit. B, same eye the day following the inoculation with culture from teeth shown in D. Case No. 987 342

444 Dental condition of Case No. 1111, with attacks of temporary complete blindness. No return of attacks at last report, two years after removal of dental infections 346

445 Dental condition of patient with acute pain in both ears, chiefly left. Relieved by removal of dental infections 346

446 Obscure neuralgia of dental origin: E, crowned vital tooth; D, without crown; A, degenerating pulp with calcifications; B, cross section of degenerating pulp with calcifications; C, high power showing hyperemia and dilation of vessels with calcification 348

447 Radiographic appearance of dental lesions related to an acute herpes zoster, which promptly disappeared after their removal. Case No. 841 353

448 Upper lateral which, when removed, completely relieved a distressing itching of the skin. Case No. 1114 . . . 354

449 Dental condition related to a case of hyperthyroidism in a young woman, aged twenty. Conditions returned rapidly to normal following their removal. Case 628 358

LIST OF ILLUSTRATIONS—*Continued*

		PAGE
450	Roentgenographic appearance of dental conditions of very severe case of exophthalmic goiter with heart involvement. Patient very rapidly recovered after removal of the dental infections. Case 471	359
451	Susceptibility record of Case No. 471, with heart and goiter involvement and nervous breakdown. Note marked hereditary susceptibility for nervous system and heart, with six deaths from the latter	360
452	An enormously hypertrophied thymus which developed in a rabbit inoculated with a dental culture	362
453	Upper, normal sublingual gland showing lobe and duct and numerous normally functioning lobules or acini; lower, pathological sublingual gland of Case No. 955, showing degenerated lobe. The lobules, or acini, are nearly all destroyed, a few intact but breaking down	366
455	Typical degenerative necrosis of sublingual glands of different cases of xerostomia	369
456	Xerostomia. Case No. 955. A, roentgenographic appearance of left mandibular second molar; B, photographic appearance of bifurcated mesial root; C, hypertrophied lobules of patient's sublingual gland	370
457	Sublingual, submaxillary, and parotid glands: In A, from a normal rabbit; in B, from a rabbit inoculated with a culture from a tooth shown in 456	372
458	B, a pair of greatly hypertrophied sublingual glands produced in a rabbit from cultures from Case No. 955 with xerostomia and rheumatism. A, an acute suppurative arthritis in same rabbit	373
459	Section of sublingual gland from Case No. 1136, suffering from xerostomia. Note marked degeneration of acinus and secreting lobule	374
460	A suppurative and hypertrophied sublingual gland of a rabbit inoculated from Case No. 1136	375
461	Section of sublingual gland of Case No. 1185, suffering from xerostomia. Shows a degenerative lobule with fibrosis	376
462	Oral herpes. An acute streptococcal abscess beneath the epithelial layer of the mucous membrane	377
463	A dental cyst which produced a very acute heart involvement in a boy of fifteen. Pulse rate dropped from 160 to 80 in a few hours after evacuation of cyst, with rapid and complete recovery	378
464	A dental cyst which started with the left mandibular bicuspids and extended to the right cuspid, shown in A and B. C shows the absorbed root apices of the lower incisors and left cuspid. Patient, suffering from heart block and symptoms of stroke, had a remarkable recovery	380
465	A huge cyst bulging the cheek and eye. B, roentgenogram of enormous cyst chamber filled with opaque. The maxillary sinus had been entirely obliterated	381
466	Oral appearance of cyst shown in A. B, entrance made to the cyst in the oral cavity. Case No. 1098	382

LIST OF ILLUSTRATIONS—*Concluded*

PAGE

467 A, a roentgenographic view; B, artificial denture and splint to support the destroyed cheek bone and permit oral mucous membrane to extend and displace all cyst tissues. Results excellent. C, section of bone adjoining advancing cyst. Note the active osteoclastic process. Case No. 1098 . 384

468 Heart of a rabbit with endocarditis produced by the inoculation of culture from Case No. 1098 386

469 Reactions on a resected tooth: A, low power view of stump; B, absorptive membrane, medium power; C, osteoclastic activity absorbing tooth. 388

470 An apparent repair of dentin of an overgrown third molar root left by a previous extraction: A, roentgenographic appearance of root in mandible; B, roentgenographic appearance of imbedded root; C, section through mesial and buccal roots 392

471 Higher power of areas of Figure 470. A shows filling in of the pulp chamber with an osteoid bone through which a blood vessel was passing; B, an osteoid bone built upon the fractured surface of dentin, over which is a layer of cementum; C, a high power of the osteoid bone of A; and D, a high power of the osteoid bone of B 394

LIST OF FOUR-COLOR ILLUSTRATIONS—VOL. II

FRONTISPIECE A. PAGE

Cross section of normal knee joint of rabbit No. 1234.

FRONTISPIECE B.

Cross section of arthritic knee joint of rabbit No. 1234.

FRONTISPIECE C.

Spontaneous interstitial hemorrhage into heart muscle of rabbit, with death in twelve hours from dental culture. Case No. 1346.

FIGURE

358 A cross section of muscle fibers which was dissected from the trapezius muscle of the neck of a patient with acute torticollis, which shows the streptococci and diplococci within the sheath of the muscle fiber. Case No. 455 . . . 205

384 Multiple abscesses in the wall of the gall-bladder of a rabbit, produced by inoculation with the culture from a tooth of a patient scheduled for gall-bladder operation. Symptoms entirely disappeared after removal of dental infection. No return of symptoms in two and one-half years. Case No. 1048 253

454 Xerostoma (Dry mouth) section of sublingual gland of patient, Case No. 955, showing a chronic proliferative interstitial inflammation, with necrotic destruction of acini. The infection is with diplo- and streptococci 367

PREFACE

SINCE *this Volume is an analysis of the clinical expressions of systemic dental infections, it is primarily a discussion of their broader symptomatology. I have not, therefore, deemed it needful that I discuss these problems here from the standpoint of furnishing more data in substantiation of the systemic expressions and effects produced by dental infections, since Volume I furnished abundant data to that end. The data, which these researches have developed, are so ample and convincing to me that I see no escape from the conclusion that many of the degenerative diseases—as nephritis, myocarditis, endocarditis, arthritis, neuritis, gastric ulcer, cholecystitis, appendicitis, neurasthenia, psychoneurosis, iritis, retinitis, myositis, pancreatitis, etc., etc.,—have as one of their important, and in many cases their chief causative factor, dental infections.*

The researches recorded in Volume I, on the oral and systemic expressions, make clear why nearly all have been misled by the mistaken premise that absorption of bone is an effect of infection and its extent its measure, confusing activity of the host as being activity of the invader. We mistook reaction for invasion. Potentially, various infected teeth are more nearly comparable than we have thought, the difference being in the reactive defense of the host; and when an adequate defensive reaction does not occur close to the source of infection, it only means that that combat must take place somewhere else. Every individual with an infected tooth, therefore, must have either an efficient quarantine station immediately about that tooth, as a granuloma, or have, as the result of that warfare taking place elsewhere, some systemic effect, which effect will appear in the weakest tissue, not the strongest. The weak tissue will be determined, as I have shown in Volume I, by inheritance in part and by overloaded or injured tissue in part. It is probably seldom, if ever, the case that the dental infection is the only contributing factor.

I have not repeated over and over, out of fear of being misunderstood, that I do not believe dental infections to be the only sources of these systemic troubles because of my confidence in the good sense of the readers. This is not a work on the systemic expressions of focal

infections of other types, as, for example, the genito-urinary tract. It is, however, applicable to all forms of focal infections of streptococcal origin, especially when existing in bone, for the same laws of susceptibility, defense, overloads, etc., will obtain; and a streptococcal (or staphylococcal) infection will finally contaminate and assist that infection which will finally take the lives of nine out of ten of us as we go out with some one or more of the degenerative diseases. Where will the streptococcal culture come from? In many cases from infected teeth and the secondary lesions planted by them throughout the body. In nine out of ten of us that final combat may come as a premature so-called old age or degenerative disease, and many years before it should, not only because of needless dental infections, but also because of other overloads, one of the most important of which is faulty nutrition and diet. I have shown, for example, that a normal rat will exfoliate an infected tooth, when planted beneath the skin, in an average of six days, while it will take over forty days for rats on a deficiency diet to do so. As I see it now, the diet deficient in mineral bases produces many organ and tissue lesions, such as those of the kidney and blood vessels, which weakened structures readily become infected if a source, such as an infected tooth, exist, and together they produce a grave nephritis. Time after time, however, we have seen the albumin disappear from the urine after the removal of the dental infection without changing the diet. It is better, of course, to do both. Similarly, this volume will detail many cases of heart involvements relieved so completely as to justify a new prognosis for many of these heretofore grave cases.

The importance, if not grave necessity, for these intensive researches is suggested by the following facts:

(1) In the statistical areas of the United States, as also of England and Wales, the percentage of deaths of all ages attributed to premature failure of the heart function exceeds 10 per cent.

(2) The percentage increases very rapidly above forty years of age, and at sixty-five being above 20 per cent.

(3) It is estimated that subacute endocarditis is caused in 95 per cent of cases by Streptococcus Viridans. (Libman: J.A.M.A., Vol. 80, No. 12: Characterization of various forms of endocarditis.)

(4) In the culturing of several thousand teeth with pulp involvements more than 99 per cent have been found to be infected with diplococci or streptococci (mostly green-producing or viridans).

(5) Statistics of the United States Public Health and Census Departments indicate that while the death rate from infectious

diseases is decreasing, it is increasing for heart involvements, kidney involvements, and other degenerative diseases.

(6) The great majority of adult individuals are carrying seriously infected teeth, potentially capable of producing degenerative diseases if the local and systemic quarantine breaks down.

(7) The great majority of adults and children are, therefore, carrying as dental foci, the strains of organisms which are found in a great majority of heart, kidney, joint and muscle, and nerve lesions, and which are potentially capable of producing these in the absence of an adequate defense.

If mankind be now passing through the third great transition forward—the first being the development of the thumb, perfecting the hand; the second, the development of the stone implements, and this, the third, his mastery over his parasitic enemies—an opportunity has come to the members of the medical and dental professions, infinitely greater than to any other of the sciences of mankind, to contribute to man's upward march to the position of a superman. Could any compensation compare with this aristocracy, the members of which have been selected for the unique service of lengthening days and wiping away the tears from many eyes? How the words of Christ "Ye shall know the truth and the truth shall make you free" are being fulfilled over and over these days by the ridding of the world of the great devastating infective plagues! May it not be that likewise the chief remaining plague—the degenerative diseases—shall likewise be reduced and ultimately banished from civilized society as it is from the simply living animal world and some of the simply living human tribes?

In the Journal of the American Medical Association (September 15, 1923) there is a report from the London correspondent, under the subtitle "The Dental Condition of the Population," calling attention to a report from a government committee as follows: "It was now known, on the authority of a government committee's report that one-third of all the diseases in the country was due, directly or indirectly, to dental disease." If that be true, and I believe it is in many communities, that third of human misery can be, and will be largely banished: first, by proper nutrition and mastication; second, by proper prophylaxis; and third, by proper dental surgery, the latter being unnecessary in proportion as the other two are efficient.

This volume contains a review of cases which are typically illustrative of their classes. They have been selected from many thousand, most of whom have been benefited, and many very greatly. The

chief messages, therefore, of this volume are first to demonstrate the types of degenerative disease that may be benefited by removal of dental infections; second, to demonstrate the types of cases that may be prevented and, therefore, never require to be corrected, and third, to demonstrate the conditions, which, when established, may never be relieved and may constitute a living death more horrible than any inquisitor's rack, and, at present, preventable only by an adequate preventative program.

I am profoundly indebted to these patients for their complete and helpful cooperation, without which these researches could not have been carried foward and recorded; and the testimony of their extended years of life and comfort constitutes the only answer that is needed to the question of the relation of dental infection to the degenerative diseases.

Weston A. Price

September, 1923
8926 Euclid Avenue
Cleveland, Ohio

CHAPTER LVIII.

INTRODUCTION TO CLINICAL APPLICATIONS OF NEW INTERPRETATIONS.

DISCUSSION.

In the following chapters we will review the results of applying these principles in approximately two thousand cases with systemic involvements, and from these we will select typical illustrations of various types of lesions and outline, in more or less complete detail, our methods of study and the clinical results, and in a large number of cases will present the results of animal experimentation with the cultures taken from the case in question. The basis on which the cases have been selected, to illustrate the applications, has been quite largely the degree of completeness of the data. For example, in cases where we could not secure quite complete family histories, we have excluded these charts from the records included on susceptibility, or where individuals have gone out of our direct observation. We have endeavored to show exceptions to rules in order that we might explain our interpretations for them; and, particularly, we have tried to select typical failures as being quite as helpful as successes.

Our basis of classification has been that suggested by Raymond Pearl,* and is based upon the biological classification of tissues. It has the advantage, that lesions in associated tissues may be considered consecutively and in more intimate relationship, than would be possible with the ordinary anatomical classifications.

It should be noted that the patients coming to a diagnostic clinic would tend to be quite dissimilar from those presenting in an ordinary dental practice. It, therefore, will not be possible for general practitioners and specialists to make direct comparisons of general data, though they may of special, for there is constant danger that the specialist seeing, as the majority of his patients, those in the breaking class, will tend to read into pathology of lesions a much greater danger, than the general practitioner who is dealing largely with well people rather than ill, and who sees

*From Proceedings of National Academy of Sciences, Dec. 1919, Vol. 5, No. 12

such large proportions of his clientele without apparent injury. This latter operator must keep in mind that whereas the former, the diagnostic specialist, is quizzing every patient in detail and therefore disclosing many affections which the patient was not associating, although important and definitely established, the general practitioner will usually have no knowledge of such conditions if they exist, both because he is used to seeing so large a proportion of his patients free from such lesions and because he makes no special and adequate effort to disclose the conditions, even when present.

We will, accordingly, take up the study of these problems in the order implied by the following classification of tissues on the basis of their biological characteristics:

1. Circulatory system.
2. Respiratory system.
3. Primary and secondary sex organs.
4. Kidneys and related excretory organs.
5. Skeletal and muscular system.
6. Alimentary tract and associated organs.
7. Nervous system and sense organs.
8. Skin.
9. Endocrine system.
10. All other tissues.

As I proceed in the following chapters to make an application of the data developed in the preceding researches, I shall be compelled to leave out of this report detailed statements involving methods of procedure. Laboratory methods are of great importance and, of course, fundamental for the individuals making the particular determinations. It is not feasible, however, to combine in a single book a manual of laboratory technic with a discussion of clinical and structural pathology. I am, accordingly, accumulating for a separate publication, various data that will be most helpful in diagnosis, prognosis, treatment, and prevention. This text will be too voluminous without that extensive discussion All biological chemists will be familiar with the literature and methods for the various chemical procedures involved in the determinations herewith presented. As a further assistance to them I am presenting as an appendix to this, a bibliography of the reference literature involved.

In Volume I, I have presented a quantity of new data which has indicated the necessity for important new interpretations of fundamentals, one of the most urgent of which is a complete change in conception and understanding of the meaning and significance of the various types of reaction about infected teeth. Much of the present diagnosis is based upon a misconception of the nature of the defensive reactions about an infected tooth. I have shown that that individual or animal is most safe that can carry on the most vigorous reaction immediately about the infected tooth and that the structural changes that take place are primarily an indication of the activity of the host rather than of the invading organism. To impress further this point I am showing here four views of the reaction produced by a rat, which animal has a higher defense for streptococcal infections than either humans or rabbits.

In Figure 262-B will be seen a granulomatous type of tissue which is the defensive structure produced by this animal. This surrounds completely the apex of the infected tooth. This rat with its high defense is able to carry his warfare up to and into intimate contact with the tooth's surface. The no-man's-land between these two engaging forces is somewhere in the tooth structure, whereas in most humans on some parts of the tooth it is some distance away from the tooth structure. Only those individuals are able to absorb an infected tooth who can carry their attacking forces completely up to the tooth surface and as the host's defense goes down this point of contact moves back away from the tooth until in broken defense it is distributed all through the body. In A of Figure 262-C, it will be noted that this warfare of the host is actually busy tearing down the infected tooth to dismantle it. These cells have as their primary function the defending of the host. In B two foramina are shown, which penetrate the cementum, and it will be noted that these defensive cells have penetrated deeply into these minute chambers in search of the enemy by a process of chemotaxis. In Figure 262-D will be seen a higher magnification of this process, which shows in a most graphic and striking way their effort seemingly to crowd each other away in order that they may be able to get at the enemy.

In Volume I, I have shown these cells passing into glass tubes in search of the enemy by this same fundamental law of chemical attraction of these defensive cells toward attacking in-



FIGURE 707 B.—GRANULOMA-LIKE DEFENSIVE MEMBRANE CONSTRUCTED ABOUT THE ROOT OF AN INFECTED TOOTH IMPLANTED BENEATH THE SKIN OF A RAT. NOTE ITS HIGH VASCULARITY AND INTIMATE CONTACT WITH THE ROOT, WHICH IS BEING ABSORBED BY IT. RATS HAVE RELATIVELY HIGH DEFENSE FOR STREPTOCOCCAL INFECTIONS.



FIGURE 262-C. HIGH POWERS OF DEFENSIVE REACTIONS OF THE RAT. A SHOWS ABSORPTION OF THE CEMENTUM BY CELLS WITH AN OSTEOCLASTIC AND DEFENSIVE FUNCTION; B, THESE CELLS PENETRATING TWO FORAMINA BY CHEMOTAXIS.



FIGURE 262-D. HIGH POWER OF ONE OF THE FORAMINA OF PREVIOUS FIGURE. NOTE THE EVIDENCE OF A COMMON RESPONSE TO A GENERAL FORCE—NAMELY, CHEMOTAXIS—BY WHICH THESE CELLS ARE ATTRACTED TO THE TOXINS AND THE BACTERIA PRODUCING THEM. THEY ARE ALSO ABLE TO FUNCTION AS OSTEOCLASTS. EACH CELL IS A FLOATING GLAND CARRYING ANTIBODY AND ANTITOXIN TO NEUTRALIZE THE ANTIGENS AND TOXINS PRODUCED BY THE BACTERIA. HIGH DEFENSE IN HUMANS OR ANIMALS, AS DEMONSTRATED BY THIS RAT, IS DEPENDENT UPON THE DEVELOPMENT AND DELIVERY OF A LARGE ENOUGH QUANTITY OF THESE DEFENSIVE SUBSTANCES TO CARRY THE AGGRESSIVE WARFARE TO THE IMMEDIATE ZONE OF THE STREPTOCOCCAL INVADER, OR AS CLOSE AS IS PHYSICALLY POSSIBLE, THE LIMITATION BEING THE PHYSICAL PROTECTION IN THE MECHANICAL ENVIRONMENT WHICH IS PROVIDED BY AN INFECTED TOOTH STRUCTURE, FOR THE DENTIN OF A SINGLE-ROOTED TOOTH CONTAINS APPROXIMATELY THREE MILES OF CLOSED CHANNELS SUITABLE FOR BACTERIAL GROWTH.

fections, provided that (and herein lie the tragedies that constitute this volume) the individual does not have these defensive forces, either lacking by inheritance or by overload, or overwhelmed by the presence of the infection through the instrumentality of its toxins. If we will keep this important interpretation in mind as we study the successive illustrations of the clinical expressions, which accompany and are the result of a broken defense, it will, in a most important way, help to clarify the involved problems.

Since the clinical data and procedures recorded in this volume are the result of the application of the data developed in Volume I, I am repeating herewith for ready reference and guidance the *New Interpretations* along with the *Old*, from which they were developed but have not given here the data on which the new are based. These will be found in the various research chapters, 1 to 44, in Volume I, and in the twelve chapters on interpretation, 45 to 56 inclusive. Problems 1 to 17 are current or old fundamentals for diagnosis, prognosis, and treatment, for which I have given new interpretations. In Chapters 18 to 44 I have presented new problems which I consider to be additional fundamentals.

OLD INTERPRETATIONS	NEW INTERPRETATIONS
NO. 1. ROENTGEN-RAY LIMITATIONS	
(a) Roentgenograms of teeth will reveal the presence of infection. *(b) The apparent extent of the absorption is the extent of the infection.* *(c) An area of absorption, if present, can be disclosed by the roentgenogram.*	**(a) Roentgenograms do not reveal infection, and may or may not reveal its effects.** **(b) The extent of the absorption does not express the extent of the infection, except in part as that individual's reaction to the infection is understood.** **(c) An area of absorption of the supporting tissue at the apex of a tooth, or laterally, may not be disclosed because of any of the following conditions; (1) Being hidden by a part of that tooth, such as another root; (2) A heavy mass of bone, such as the malar bone; (3) A layer of condensing osteitis obscuring the rarefying osteitis.**
NO. 2. BACTERIAL CAUSE.	
If dental infections produce disturbance in other parts of the body, it is because the organism that has chanced to invade that tissue is one having the specific qualities for that invasion and localization regardless of the host, much as the organisms of erysipelas and mumps will respectively select the skin and parotid gland.	**Dental infections involving root canals and their apices and supporting structures practically always contain streptococci, of which, biologically, there are many types or strains, any one of which may be the important causative factor for any of the various types of rheumatic group lesions, regardless of biological classification. The elective localization and attacking qualities are developed by the environment and are, consequently, a factor of the soil or host.**

OLD INTERPRETATIONS | NEW INTERPRETATIONS

NO. 3. LOCAL-ORAL-STRUCTURAL CHANGES.

a) Dental infection in bone will express itself as absorption.

b) A given dental infection will express itself in the local tissues of the mouth approximately the same in all people.

a) Dental infection in bone may express itself as absorption, even extensive absorption, or may be attended by very little or no absorption, or may even produce a marked increase in the density of the bone.

b) A given dental infection will not express itself in the local tissues of the mouth approximately the same in all people. People tend to divide into groups with regard to this matter of local reaction, which groups are very dissimilar.

NO. 4. SYSTEMIC REACTIONS. ARE HUMAN BEINGS COMPARABLE?

Human beings are similar in their susceptibility to reactions to dental infections, or sufficiently so, that they may be considered comparable and be judged by the same standards.

Human beings do not react with sufficiently uniform similarity to justify the premise that they can all be judged by the same standards and, therefore, may be considered comparable in their susceptibility to systemic involvement from dental infections. They can, however, be divided into groups, the members of which are sufficiently similar to be judged by the same general standards, and they of that group may, therefore, be considered comparable. On the basis of this quality of susceptibility, they readily classify into three groups; namely, those with an *inherited* susceptibility, those with an *acquired* susceptibility, and those *without* a susceptibility to rheumatic group lesions.

NO. 5. RELATIONSHIPS BETWEEN LOCAL AND SYSTEMIC EXPRESSIONS.

Since, according to the presumption all individuals are similar, and since dental infections are entirely dependent for their characteristics upon the type of organism which has chanced to secure access, therefore there are no characteristics of the local tissue pathology which are related to the degree of susceptibility or nature of systemic involvement.

Local dental pathology about an infected tooth has variations which make grouping and classification easily possible on this basis, which groups have a direct relationship with similar groupings that can be made on the basis of susceptibility to rheumatic group lesions. The local and systemic expressions are not only related, but are both symptoms of the same controlling forces and conditions.

OLD INTERPRETATIONS	NEW INTERPRETATIONS
NO. 6. VISIBLE ABSORPTION AND TOOTH INFECTION.	
(a) A tooth without visible absorption at its apex is not infected. *(b) A tooth with visible absorption at its apex is infected.*	(a) Teeth without absorption at their apices can be, and frequently are, infected in the pulp, dentin, and apical tissue. (b) Teeth with periapical absorption can have the same produced by irritating medication or trauma.
NO. 7. CARIES AND PULP INFECTION.	
Pulps of teeth not exposed by caries are not infected.	Teeth with moderate caries frequently, and with deep caries generally, have their pulps already infected to some extent through this channel.
NO. 8. PERIODONTOCLASIA AND PULP INFECTION.	
Pulps of teeth with pockets from periodontoclasia not involving the apex are not infected.	Teeth with shallow or moderate pockets from periodontoclasia frequently, and with deep pockets from periodontoclasia usually, have their pulps already infected to some extent from that source.
NO. 9. CARIES. AND SYSTEMIC INVOLVEMENT.	
There is no relationship between caries and systemic involvements.	Susceptibility to dental caries and systemic involvements from dental lesions are proportional, both as cause and effect and as related symptoms.
NO. 10. PERIODONTOCLASIA AND SYSTEMIC INVOLVEMENT.	
With an increase of susceptibility to periodontoclasia, there is a marked increase in susceptibility to rheumatic group lesions.	Individuals with marked susceptibility to periodontoclasia have, as a group, a decreased susceptibility to the rheumatic group lesions during the period of its active development (in its secondary stages it may contribute to rheumatic group lesions); or expressed otherwise, individuals with a very marked susceptibility to rheumatic group lesions tend, in general, to be free from extensive periodontoclasia; and when rheumatic susceptibility does develop, it would generally be classed as an acquired factor.

OLD INTERPRETATIONS NEW INTERPRETATIONS

NO. 11. PERIODONTAL AND APICAL REACTIONS.

There is no relationship between the extent of apical absorption from a pulp involvement and the presence or absence of a periodontal absorption from a gingival irritation.

There is a direct relationship between tendency to absorption of alveolar bone in response to irritation, whether at the gingival border or at the root apex; and individuals with extensive periodontoclasia have, for a given dental infection, much more extensive areas of absorption at the apices of infected roots, than do patients without a tendency to periodontoclasia.

NO. 12. RELATION OF APICAL ABSORPTION TO DANGER.

The quantity or extent of the absorption is a measure of the danger; or otherwise expressed, the size or extent of the disclosed area of absorption at the apex of the root of a tooth is directly an expression of the quantity of infection and, therefore, a measure of the danger from it.

Since different people react differently, through a wide range, to a given infection, the extent of the area of absorption is not a measure of the danger; but, on the contrary it may be, and frequently is true that the patient suffering severely from a systemic reaction caused by a dental infection shows very little absorption compared with that which the same dental infection would produce in a patient with ample and high resistance.

NO. 13. NATURE OF FISTULA DISCHARGE.

Flowing pus from a fistula is, necessarily, very dangerous to the patient since it is an expression of the quantity of local infection and, therefore, a measure of the danger from it.

Since an adequately active defense against a dental infection, both locally and systemically, produces a vigorous local reaction with attending extensive absorption and the products of inflammatory reaction, namely, exudate and plasma in sufficient quantity to require an overflow, usually spoken of as pus from a fistula, this overflow may be, and usually is, evidence of an active defense and is constituted almost wholly of neutralized products and is often sterile, and such a condition is much more safe than the same infected tooth without such an active local reaction.

OLD INTERPRETATIONS NEW INTERPRETATIONS

NO. 14. ROOT CANAL MEDICATIONS.

(a) Infected teeth can be sterilized readily by medication.
(b) Usual medications do not injure the supporting structure.

(a) Infected teeth can be completely sterilized in the mouth only with great difficulty, or by the use of medicaments whose irritability readily injures the vitality of the supporting structures of the teeth.

(b) Many of the usual methods used for the sterilization of infected teeth do serious injury to the supporting structures about the teeth.

NO. 15. ROOT CANAL FILLINGS.

Root fillings fill pulp canals and continue to do so.

Root fillings rarely fill pulp canals sufficiently perfectly to shut out bacteria, completely or permanently. Root fillings usually fill the pulp canal much less perfectly some time after the operation, than at the time of the operation, due to the contraction of the root-filling material. The ultimate volume contraction of the root filling is approximately the amount of solvent used where a solvent is used with gutta-percha as a root-filling material. Infection is a relative matter, and quantity and danger are both related to defense, which defense may vary from high to exceedingly low.

NO. 16. COMFORT AS A SYMPTOM.

Local comfort and efficiency of treated teeth are an evidence and measure of the success of an operation.

Local comfort not only is not a certain index of success or safety, but may constitute both what is probably one of the greatest paradoxes and one of the costliest diagnostic mistakes through injury to health, that exists in both dental and medical practice, because it may only mean the absence of local reaction which would, if present, incidentally make the tooth sore and fundamentally destroy the infection at its source whereas, the absence of this local reaction and its consequent destruction of the infection products, permits them to pass throughout the body to irritate and break down that patient's most susceptible tissue, which tissue can be anticipated very frequently, if not generally.

OLD INTERPRETATIONS NEW INTERPRETATIONS

NO. 17. CAPACITY FOR INFECTION OF ROOT-FILLED TEETH

When infected teeth produce disturbance in other parts of the body, it is primarily because the patient is overwhelmed by a large quantity of infection.

When infected teeth produce disturbance in other parts of the body, it is not necessary that the quantity of infection be large, nor is it demonstrated that it is necessary that organisms always pass throughout the body or to the special tissues involved, but the evidence at hand strongly suggests that soluble poisons may pass from the infected teeth to the lymph or blood circulation, or both, and produce systemic disturbances entirely out of proportion to the quantity of poison involved. The evidence indicates that this toxic substance may, under certain conditions, sensitize the body or special tissues, so that very small quantities of the toxin or of the organisms which produce it, may produce very marked reactions and disturbances in that tissue.

The preceding research problems cover the fundamentals that have been in general consideration in problems of dental diagnosis, prognosis, and treatment. My researches upon them have opened up many additional problems, twenty-seven of which I have presented in the latter part of the preceding chapters. There cannot, therefore, be given for these latter problems, an old and a new interpretation. I will, accordingly, present herewith, some general interpretations growing out of the general applications and later researches, and in place of the statement of the problem as an old fundamental in the left-hand column, as in the first seventeen chapters, will simply state the problem.

NEW PROBLEMS

NO. 18. STUDIES OF PULPLESS TEETH.

Have pulpless teeth injurious contents other than microorganisms?

Infected teeth may contain in addition to microörganisms toxic substances, which produce very profound effects upon experimental animals, and which tend to prepare the tissues of the host, at least in some cases, for a more ready invasion by the organisms growing in that tooth.

NEW PROBLEMS NEW INTERPRETATIONS

NO. 19. HEMATOLOGICAL CHANGES IN THE BLOOD.

What changes are produced in the blood and sera of the body by dental infections?

Dental infections may produce very serious changes in the blood and sera of the body, some of the most frequent of which are leucopenia, erythropenia, lymphocytosis, and hemophilia.

NO. 20. CHEMICAL CHANGES OF THE BLOOD.

What are the chemical changes that are produced in the blood by acute and chronic dental focal infections?

Dental focal infections tend to produce, in many instances, one or several chemical changes in the blood, which changes tend also to be produced in animals when an infected tooth is placed beneath its skin, and, similarly, with certain methods of inoculation with the culture grown from these teeth. Some of the changes most frequently found involve:

(a) The ionic calcium of the blood.

(b) The presence of a pathologically combined quantity of calcium in the blood.

(c) A reduction of the alkali reserve of the blood.

(d) The development of acidosis.

(e) An increase in the blood sugar.

(f) An increase in the uric acid.

(g) The development of nitrogen retention.

(h) The development of products of imperfect oxidation.

NO. 21. CONTRIBUTING OVERLOADS WHICH MODIFY DEFENSIVE FACTORS.

What are the contributing factors causing a break in resistance?

Dental infections, while potentially harmful, may not be causing apparent or serious injury until the individual is subjected to some other overload, at which time a serious break may come. The chief contributing overloads are influenza, pregnancy, lactation, malnutrition, exposure, grief, worry, fear, heredity, and age.

NEW PROBLEMS NEW INTERPRETATIONS

NO. 22. ELECTIVE LOCALIZATION AND TISSUE AND ORGAN SUSCEPTIBILITY PHENOMENA.

Do the organisms of dental infections possess or acquire tissue affinity and elective localization qualities?

Dental infections may or may not contain organisms with a specific elective localization quality for certain tissues of the body. When they do so it is generally because the host is suffering, or has previously suffered, from an acute process in that tissue, which acute process frequently, entirely and permanently, disappears with the removal of the focus of infection. There is evidence to indicate that the complete removal of an organ so affected does not destroy that elective localization quality in the microörganisms of the focus. Defense and absence of defense to streptococcal infection as an organ and tissue quality, seems definitely to be related to inheritance and, as such, obeys the laws of mendelian characteristics.

NO. 23. ENVIRONMENT PRODUCED BY INFECTED PULPLESS TOOTH.

What are the characteristics of the habitat and environment furnished for bacteria in an infected pulpless tooth?

Since an infected tooth is a fortress for bacteria within the tissues of the host, and since, in accordance with the laws governing the behavior of solvents and solutes, the dissolved substances within the tooth can pass to the outside of it, and, similarly, the dissolved substances outside the tooth can pass to the inside of it, together with the fact that the defensive mechanisms of the body are quite unable to enter and reach the bacteria within the tooth except in exceedingly small numbers through the natural openings of the root, which openings will, however, permit the organisms to pass at will from within the tooth to the outside, we must conclude that an infected tooth furnishes a condition and environment that is tremendously in favor of the invading organism inhabiting it, as compared with the host, since the latter may only rid itself of the menace by exfoliating it or absorbing it.

NEW PROBLEMS	NEW INTERPRETATIONS

NO. 24. ELECTIVE LOCALIZATION AND ORGAN DEFENSE.

Do diseased organs and tissues modify bacteria growing in the distant focus, or create in them a capacity for localization for those diseased tissues?

We are led to conclude from the available data, that we do not as yet have sufficient information to draw a close distinction between the influences of the organisms on the affected organ, in contradistinction to the influences of the diseased organ upon the organisms in the focus. The available data suggest strongly, if they do not definitely indicate, that both these conditions exist, in some instances, either one acting entirely alone, and in some others there are indications that both exist at the same time.

NO. 25. RELATION OF IRRITANT TO TYPE OF REACTION.

Have we different products from dental infection?

The evidence available indicates that infected teeth elaborate two distinctly different products, one being bacteria, and the other a toxic substance or group of toxic substances, which, independently of the organisms developing them, may produce various and profound disturbances in tissues in various parts of the body, one of the important group of disturbances being that of the blood stream.

NO. 26. CHEMOTAXIS AS A MEANS FOR INCREASING DEFENSE.

Can defense for streptococcal infections be increased by introducing enterally or parenterally (by ingesting or injecting) chemicals?

These preliminary experiments would seem to suggest that, means can be developed which will effectually assist, by chemical means in the defense of the body against the invading streptococcal organisms of dental origin or from other sources which produce the rheumatic group lesions.

NO. 27. THE EFFECT OF RADIATION ON DENTAL PATHOLOGICAL LESIONS.

Can periodontoclasia and apical abscess and inflammation be cured by various types of radiation?

(a) These three forms of radiation—namely, Roentgen-ray, radium radiation, and ultraviolet as generated from mercury vapor and quartz tube—have definite effect

on cell resistance and proliferation, and thus directly upon tissue reaction expressions such as pus, bacterial invasion, and granulation.

(b) Some of these forces are apparently definitely harmful; others are apparently definitely helpful.

NO. 28. GINGIVAL INFECTIONS, THEIR PATHOLOGY AND SIGNIFICANCE.

Are the present theories regarding the etiology of periodontoclasia, or so-called pyorrhea alveolaris, correct?

(a) Inflammatory processes of the tissues about the teeth are a direct expression, and therefore a measure of the vital capacity for reaction of that individual to an irritant, during those stages of these lesions, characterized by an abnormally high vital reaction.

(b) The individual, who has had this capacity for a very active reaction to the presence of irritants, may pass into a condition or state in which he or she has lost that high defensive factor, at which time several changes develop including a cessation of the absorption of alveolar bone, a lowering of the alkalinity of the periodontoclasia pockets, a change in their bacterial flora, all of which may provide under these later conditions a focus for systemic infection of the most dangerous type, though they may have ceased to have evidence either of local inflammatory disturbance, or exudate as pus.

(c) To the ordinary observer, lay or professional, these two very dissimilar states are considered to be similar or identical though they are potentially very different.

(d) These different peridental expressions or reactions to irritations are accompanied by, and doubtless related to, changes in the ionic calcium and alkali reserve of the blood.

NO. 29. ETIOLOGICAL FACTORS IN DENTAL CARIES.

What are the dominant etiological factors in dental caries?

Dental caries is dependent upon the following factors:

NEW PROBLEMS

NEW INTERPRETATIONS

(a) A reduction in the hydrogen ion concentration of the normal environment of the tooth.

(b) An acid producing bacterium.

(c) A change in the chemical constituents of the pabulum bathing the tooth.

NO. 30. THE NATURE OF SENSITIZATION REACTIONS.

Do dental infections produce sensitizations of an anaphylactic character?

(a) Teeth contain substances other than bacteria to which the individual may become sensitized, and which substances may, in addition, have strong toxic properties.

(b) The evidence here presented suggests that dental infections are capable of producing in an individual a state of anaphylactic sensitization, which condition may entirely and apparently permanently disappear with the removal of the dental infections. These disturbances may occur in dermal tissues, mucous membranes of the nose and throat, lacrimal tissues, mucous membranes of the bronchioles and air passages, as asthma, and the mucous membranes of the digestive tract and a number of other types of tissues.

NO. 31. PRECANCEROUS SKIN IRRITATIONS.

Are there relationships between precancerous skin irritations and dental infections?

The evidence available suggests:

(a) That dental infections may produce localized anaphylactic reactions, as irritations of the skin and mucous membranes.

(b) That these sensitizations may develop into precancerous conditions.

NO. 32. DENTAL INFECTIONS AND CARBOHYDRATE METABOLISM.

What, if any, is the relationship between dental infections and carbohydrate metabolism?

Dental infections may produce marked changes in carbohydrate metabolism and probably structural and degenerative changes in the islets of Langerhans of the pancreas, with the production of hyperglycemia and glycosuria.

NEW PROBLEMS NEW INTERPRETATIONS

NO. 33. MARASMUS.

Why do people with rheumatic group lesions tend to be underweight?

Dental infections, when they affect the patient systemically, frequently, if not generally, produce a depression of the individual's weight; and marasmus, whether mild or severe, may be considered one of the diagnostic symptoms in studying the relation of dental infections to general health.

NO. 34. PREGNANCY COMPLICATIONS.

Do dental infections have a bearing on pregnancy complications?

(a) These researches have shown that in animals, infections from dental origin may have a very far-reaching effect on each the expectant mother and her fetus, which latter may be prematurely expelled or may be rendered lifeless.

(b) Inasmuch as a large number of our serious cases of rheumatism, heart, and kidney involvements, have their origin at the time of pregnancy in humans, in which cases our clinical histories show that there have been present extensive dental focal infections, it is suggested as important, if not imperative, that expectant mothers shall be free from dental focal infections, both for their own safety and efficiency and for the continued vitality of the fetus.

NO. 35. SPIROCHETE AND AMEBA INFECTIONS.

Do organisms other than streptococci enter the human system through dental infections?

While the streptococcus seems universally to be present in dental infections in practically all cases of systemic involvement, in addition to this variety the evidence seems to establish that each staphylococci and spirochetes may pass from infected teeth to other tissues and proliferate in localized areas; and, similarly, that when certain mixed strains are injected into experimental animals, localized spirochete infections may develop in their tissues. Systemic involvements from spirochete infections and their localization in experimental animals are, however, relatively rare.

NEW PROBLEMS NEW INTERPRETATIONS

NO. 36. NUTRITION AND RESISTANCE TO INFECTION.

What is the relation of nutrition to resistance to dental infection?

The data at hand suggest:

(a) That the effects of variations in the diet do not express themselves quickly in specific defense.

(b) That variations in diet by the limitation of various vitamines produces effects which, in general, are similar to those of overload.

(c) Deficiency diets, particularly disturbances resulting in a calcium hunger, tend directly to lower the defense to dental infections.

NO. 37. THE RELATION OF THE GLANDS OF INTERNAL SECRETION TO DENTAL INFECTIONS AND DEVELOPMENTAL PROCESSES.

What is the relation of the glands of internal secretion to dental infections in developmental processes?

We would summarize these studies as follows:

(a) Disfunctions of various of the glands of internal secretion are often very materially corrected, and sometimes completely so, by the removal of dental focal infections.

(b) Involvements have frequently been produced in similar endocrine tissues of the animals by inoculating them with the cultures from the teeth of the involved patients.

(c) The administration of the extracts of the glands of internal secretion, particularly of the parathyroid, is shown to be of distinct benefit in certain cases of depressed ionic calcium of the blood, due in part to dental focal infections, where this improvement has been absent or slow following the removal of the dental infections.

(d) An improvement has been produced in individuals, which we interpret to be due to a stimulation of the pituitary body, which in turn doubtless stimulates other ductless glands and together with them produces a marked change in both physical and mental states.

NEW PROBLEMS NEW INTERPRETATIONS

NO. 38. THE NATURE AND FUNCTION OF THE DENTAL GRANULOMA.

Is the dental granuloma a pus sac and its size a measure of the danger?

(a) The so-called granuloma is a misnomer, for it is a defensive membrane and not a neoplasm.

(b) A normally functioning periapical quarantine tissue is Nature's effective mechanism for protecting that individual by destroying the organisms and toxins immediately at their source, and thereby completely prevent the tissues of that individual's body from exposure to either of these agencies.

NO. 39. CHANGES IN THE SUPPORTING STRUCTURES OF THE TEETH, DUE TO INFECTION AND IRRITATION PROCESSES.

What are the changes produced in the supporting structures of the teeth, which are due to infection and irritation processes?

Characteristic localized structural changes develop in the supporting structures of teeth when the latter carry infection within their structures. These changes are, however, determined chiefly by the host and are an expression of the reacting characteristics of the host rather than an expression of the invading bacterium.

NO. 40. DENTAL INVOLVEMENTS CAUSED BY ARTHRITIS.

Can arthritic infections of the body attack and devitalize the teeth?

(a) It will be seen from these data that a systemic involvement of multiple arthritis may, while attacking various joints of the body, also attack those of the joints of the teeth; and, further, that this process of inflammation with degenerative and proliferative processes may cause the involvement and ultimate death of the pulp.

(b) The involvement of these teeth as a result of the progressive systemic arthritis may in turn, and doubtless frequently, if not generally, does aggravate the general condition, for the tooth structure when it becomes infected is even less capable of vascularization and therefore less amenable to the processes of defense than is bone. This stresses the very great importance that individuals having deforming arthritis shall have most careful dental inspection

NEW PROBLEMS NEW INTERPRETATIONS

and care, and also, since it is one of the most horrible of living deaths, every effort should be made to prevent the beginning of that process; and since the evidence is so overwhelming that the initial infection frequently, if not generally, comes from the teeth, helpless humanity deserves pity until the powers that be shall make a worthy effort to find the means that will prevent this needless catastrophe in so many lives.

NO. 41. VARIATIONS IN THE DEFENSIVE FACTORS OF THE BLOOD.

Is there a difference in the defensive factors of the blood of susceptible and non-susceptible individuals to systemic involvements from dental infections?

There is a marked difference, which is readily measurable in the bactericidal properties of the bloods of individuals of high defense, as compared with those of low defense to systemic involvements from dental infections.

NO. 42. METHODS FOR REINFORCING A DEFICIENT DEFENSE.

Can a temporarily or permanently low defense against the streptococci of dental infections be increased or enhanced either temporarily or permanently?

In some individuals a low defense may be materially strengthened by the use of vaccines and also by the use of all available means for stimulating metabolism and increasing a supply of essential nutritional factors.

NO. 43. SEROPHYTIC MICROÖRGANISMS.

What are the growth factors of microorganisms of the mouth in juices of living tissues?

When the mixed flora of the oral cavity are planted in the normal blood serum or lymph, the varieties that grow are almost entirely limited to the strains of diplo- and strepto-cocci, with occasional staphylococci, with the diplo- and strepto-cocci largely predominating.

NO. 44. CALCIUM AND ACID-ALKALI BALANCE.

What is the role of calcium to the maintenance of the acid-alkali balance of the blood, other body fluids, and tissues?

In the proper functioning of the body, the end products of metabolism are carbon dioxide, urea, and water. When metabolic functions are abnormal, resulting in the imperfect oxidation with the development of less simple acids than carbon dioxide,

NEW PROBLEMS NEW INTERPRETATIONS

these must be neutralized with bases taken from the body and its fluids. In the absence of an adequate supply of these from other sources, the demand must be met by the calcium of the body, first from the circulating ionic calcium, then from the calcified tissues. This latter is the characteristic end reaction involved in periodontoclasia, or pyorrhea alveolaris. This enters into and complicates the etiology of many, if not most, of the rheumatic group disturbances studied in detail in subsequent chapters.

NO. 45. SYMPTOMS AND DANGER.

Since individuals are similar in their reactions to dental infections, both locally and systemically, and since freedom from involvements is dependable, the danger is proportional to the quantity and to the type or virulence of the dental infection involved and the patient's symptoms.

Since patients largely determine the biological qualities of the organisms involved in dental infections by the culture medium they furnish the bacteria, and since the sufficiently high defense of certain individuals will, under ordinary conditions, protect them from systemic injury resulting from their dental infections, and since the local oral expressions of the dental infection are an indication and a measure of that individual's reaction to the dental infection rather than a measure of that infection, therefore, it becomes apparent that the operation that is indicated is an individual factor and concerns the relation of the efficiency of the patient's defense to the attacking power of the dental infections and, accordingly, operations which are strongly indicated for some individuals are as strongly contraindicated for others.

NO. 46. DIAGNOSIS.

An adequate procedure for making dental diagnosis is a roentgenographic study of the patient, for which the only requisite training is a working knowledge of the apparatus and a familiarity with dental anatomy sufficient properly to call the teeth by their names.

An adequate procedure for making a dental diagnosis will involve, as a minimum, the following:

A knowledge of the patient's systemic defense and systemic involvements, both present and past. The securing of this will involve:

(a) A knowledge of the various systemic disturbances that may be produced or ag-

NEW PROBLEMS NEW INTERPRETATIONS

gravated by the dental infection, with or without the patient's recognition of their existence. A knowledge of the systemic disturbances includes, for differentiating purposes, a knowledge of the etiological pathology of the involved tissues of most of the morbid conditions of the human body, regardless of the type of tissue or the involved nature of the functions. These are based upon a thorough knowledge of the gross and minute anatomy of the various organs and tissues of the body, and the normal functions of those tissues, with special reference to the nervous system.

(b) A roentgenographic study, with a knowledge that it is physically impossible for the Roentgen-rays to disclose much of the essential information, the roentgenogram being simply a record of relative total densities of the planes involved.

(c) A familiarity with the use of the microscope and such laboratory technique as serological study of the fluids of the body, since many of the lesions, being produced or aggravated by dental infections, are in evidence by microscopic and chemical methods long before they appear clinically as symptoms.

NO. 47. DIAGNOSTICIANS.

Dental diagnosis is so simple that any dentist or physician, osteopath, chiropractor, electrical engineer, or laboratory assistant, is competent to perform this simple service.

Dental diagnosis is so intricate and involved that it requires a greater knowledge of the human body, its structure and diseases, and of the various means for understanding the normality and abnormality of the same, than any specialty of the healing arts; and probably no specialty finds such great opportunity for doing injury to humanity, or for extending human life, as does the highest application of intelligence in this field. A competent diagnostician of the local and systemic expressions of dental infections must be familiar with the clinical and structural pathology required for a general medical diagnosis, and, in addition, be completely familiar with each dental anatomy, dental pathology, and dental operative procedure.

There are many phases of these problems that are very involved. Few dentists realize the advantage of preventing the development of a lesion over undertaking its correction or cure, not appreciating that lesions of the central nervous system, that have existed for two years or more, are generally irreparable; and similarly, many lesions of the kidneys, when once established, constitute a permanent and often progressive disfunction. It is, therefore, often too late when the psychosis, atrophy, or nephritis is discovered. This also is particularly true of heart lesions. The knowledge of these facts, then, becomes fundamental for an efficient prophylactic sense. This does not mean that in the absence of a basis for judgment, all teeth should be extracted. This constitutes one of the gravest of tragedies, since to add to a permanent deformity and handicap that of a living permanent cripple is a needless double curse and a reproach to the very name and spirit of the healing sciences. The purpose of these chapters is to illustrate not only that dental infections produce degenerative diseases, *but that the removal of only the involved teeth produces the relief being sought.*

CHAPTER LIX.

APPLICATION OF PRECEDING EXPERIMENTAL DATA IN CLINICAL PRACTICE.

DISCUSSION.

In no part of dental practice does the value and significance of these new data have so great an importance as in the nature of treatment and procedure, for an intelligent application of these fundamentals will not only conserve innumerable good teeth which are now being ruthlessly and needlessly sacrificed, but cause the removal of other innumerable teeth now being entirely overlooked or being passed as not having sufficient evidence of pathology. If, as I am personally convinced, an individual with a marked susceptibility to heart involvement will tend to have the same irritated by the presence of even a small quantity of locked dental infection, it is not safe or wise for that patient to have that small quantity unless we can find a condition in which the service of the involved tooth is so great to that individual that he or she will be done more harm by its removal than by that infection, which condition rarely exists, since a properly functioning heart is so fundamental not only to life itself but to comfort and efficiency of living, for a body cannot function without a functioning heart. And this is quite as true of kidney.

As we have shown, pulpless teeth, even when root filled, can become (and I believe ultimately generally do become) infected, because every tooth may contain approximately five per cent culture medium, even after root filling, unless something has been done, which as yet I have not had evidence can with confidence be accomplished, efficiently to establish a condition in which neither organisms nor degeneration products of tooth tissues can develop. If, then, a given patient can be shown to have an abnormally low capacity for establishing and maintaining a defensive quarantine about every root-filled tooth, and if he or she has a definite susceptibility to an involvement of a vital organ such as heart or kidney, it is my judgment that for that patient pulpless teeth should be extracted, or if filled, should be most carefully watched; and I do not know of any means for ascertaining whether a tooth

in that type of patient is approaching a condition of danger after it is treated and root-filled because of that failure to react.

If, on the other hand, the patient in question can be shown to have the ability to establish an adequately efficient defense and quarantine about even a highly infected tooth or teeth to keep that patient entirely safe, it is my opinion that if a tooth without extensive infection is valuable to that patient and if the peridental membrane has not been seriously involved but the pulp is endangered either from mechanical injury or deep caries, that pulp may be removed under certain conditions and the root fillings may be placed (if such can be done from a mechanical standpoint with very great thoroughness) and produce a condition which will be relatively safe for that patient during the time that he or she has that relatively high defense. I believe, however, that it is true that such a patient's high defense will keep him safe not only because of our dental procedure but in spite of anything that we can possibly do to that tooth. Such a safety on the part of the patient will be due almost entirely to the fact of his or her high defense and not because any operator is capable of placing that tooth in a condition in which it could never become infected. In other words, I believe practically all root-filled teeth, for this has been the result of my extensive studies, sooner or later (and with most very soon) contain organisms, though in the case of the type of patient we are considering with high defense, not in such quantities as are capable of producing toxic substances or organisms capable of invading that individual; for these, as they develop, are efficiently combated immediately surrounding the tooth. Since, however, we can never know when overload will strike even these individuals, such as influenza, grief, physical and nervous strain, etc., we must be very guarded in presuming that these individuals will always have that high defense.

And, further, the age of the patient tends largely to determine that factor of safety; for just as a cannon ball is fired out over the sea and rises higher and higher to its maximum elevation, it can be known that ultimately and soon it must start to come down, and as it starts to come down, the beginning of the end of that flight has begun. And similarly, we must look upon all individuals beyond middle life, regardless of their defense, as approaching the time when that defense must of necessity diminish, and we are not justified in taking the same chances that we could when their defense was normally high and there was a prospect of

its remaining so for some time. In other words, all root-filled teeth should, in my judgment, be considered under suspicion or at least under observation and should be checked up frequently and regularly if that patient's best interest is to be concerned; for, as we will see, there are many forms of systemic disturbance which may be aggravated, if not directly produced, by these dental infections which we have not so considered. The severity of the systemic expression and the contributing factors,—namely, dental infection and contributing overloads,—must all be considered in deciding what type of operation may be made in a given case.

I can best illustrate my interpretation of the best procedure and treatment in each of these types of cases by reviewing the case histories and applying these principles and presenting with each the research data such as elective localization of these strains in animals, serological and bacteriological studies on both the animals and patient, and the after-history, for it has not been possible for us to come to these conclusions except in the light of the fundamental results obtained in clinical practice.

Before taking up in detail the clinical study and pathological conditions of the body and their relations to dental infections under the various groupings, it will be to our advantage to review a typical case with the application of these general principles. We are coming to find by experience that a large number of heart cases may have a much better prognosis than the general experience with hearts would suggest. They seem to be in a state of very acute irritation, with the production of symptoms quite similar to, if not identical with, those of acute endocarditis. And probably in no specialty of medicine is it more important that those trusted with the chief responsibility of that part of the body shall use preventive programs; and, above all, that they shall not create, let alone maintain, the type of focal lesion which will make possible the development of the irritant for these sensitive and already injured hearts. Their sensitiveness is often, however, our fundamental danger. The injury that has already been done to a valve cusp may have been largely compensated by Nature. Such a case is the following:

Case No. 383.—The patient at the time she presented, five years ago, was twenty-three years of age. She had been incapacitated from her work by lassitude, shortness of breath, and acute rheumatism. Her net weight was 131 pounds, height 5 feet 7¼ inches. Family conditions made it necessary for her to work if at all possible.

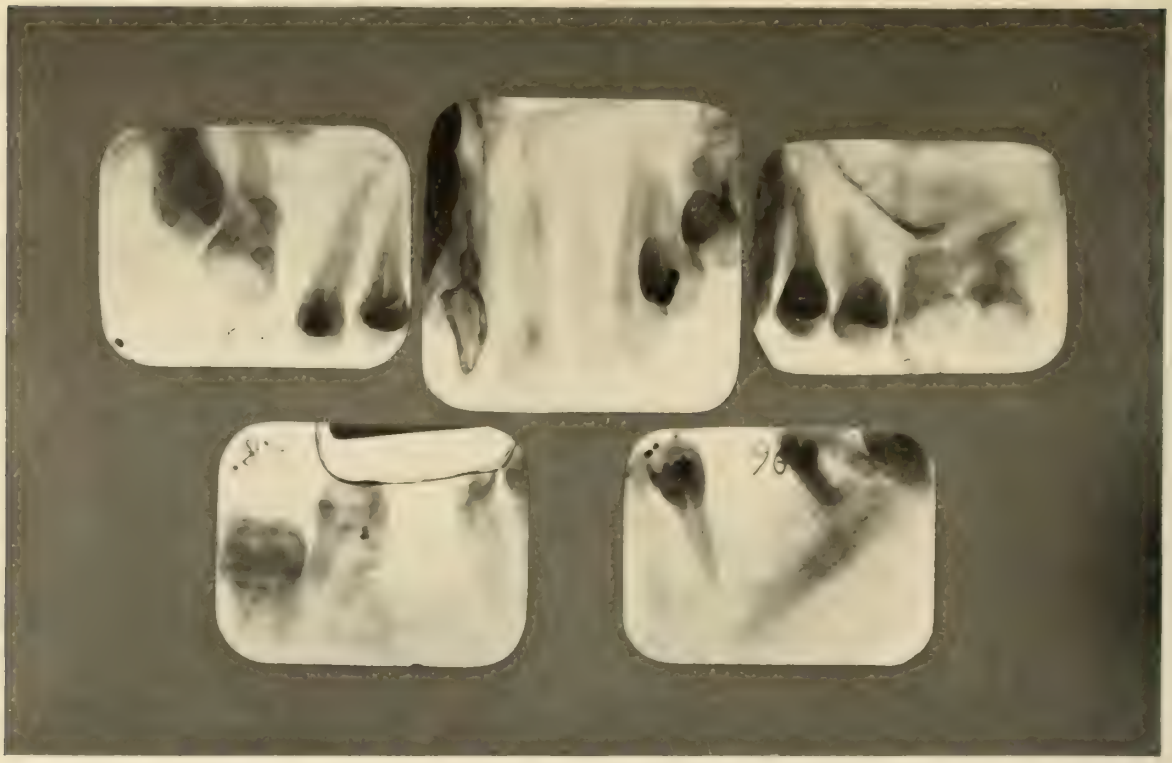

FIGURE 263. ROENTGENOGRAPHIC APPEARANCE OF TEETH OF CASE NO. 385.

Her dental conditions are shown in Figure 263. An examination of her teeth shows that the pulps are vital in the upper right first and second molars, and upper left molars; non-vital without root filling, upper right lateral; root filling with limited periapical absorption, upper left central. I hope the dental readers of this text at this point will visualize what they would do with such a case in their own practice before following my interpretation of what should be done and the description of the program carried out. Is it not true that in a person twenty-three years of age with vital pulps you would be disposed to put gold crowns on these molar teeth after removing the caries; and if the pulps were found exposed, proceed to root-fill? Since there is very little suggested trouble with the lateral, it would readily be taken care of by root filling. I will venture to guess that the great majority of the members of the dental profession would carry out a program without extraction of the above named teeth.

But let us study her case a little farther. What is the shape of the roots of these upper molars? Are you sure you could fill around the angles? Or have they angles? Figure 264 shows



FIGURE 264. PHOTOGRAPHIC APPEARANCE OF EXTRACTED TEETH OF CASE NO. 385. (SEE FIGURE 263.)

photographs of these extracted molars; and it is very certain that no dentist could, with certainty, place fillings in these molar roots that would fill in the sense that we understand root fillings should.

This reminds me that one time at a dental convention a dentist made the bold assertion that he could fill 95 per cent of molar roots perfectly to the apex. A discussion arose and his ability was questioned; not that he was less competent, but even assuming that he was more competent, than the average. It was finally decided that I should select a quantity of molars and send them to him invested in plaster-of-Paris. He was to root-fill them and send them back. That would be an interesting illustration to insert here, but it is aside from the purpose of this volume. Suffice it to say that he did not have 5 per cent of them properly filled to the apices, and in about 25 per cent he penetrated the root walls; this, notwithstanding the fact that green teeth were used and the plaster in which they were embedded was kept moistened.

But why root-fill teeth whose pulps are not definitely exposed? And, particularly in young persons, why not place gold crowns on these teeth "until they give trouble"? We have cultured a large number of pulps of teeth with deep caries and practically always find those pulps infected; and in other chapters we have illustrated the production of acute rheumatism in animals with the cultures taken from pulps of such teeth, and which patients were already suffering from acute heart involvement.

But this clearly suggests that we must have a basis of discrimination, for certainly many pulps can and will remain vital if properly, protected and such teeth may give very important serv-

ice for a long period of time. In other words, it is true that for many patients teeth like the above are more valuable in the patient's mouth than out, all interests of their lives concerned. But here we are dealing with a different type of patient from the above and I have discussed this from this viewpoint in order that I might stress the great advantage in having a resistance and susceptibility chart for every case in which we have to make so important a decision, in order that we may evaluate that patient's factor of safety, for his or her teeth are only valuable in accordance with their safety from an injury to their health, which would far outweigh the great advantage of retaining the service of the tooth in question.

Figure 265 shows the susceptibility chart for this patient. It will immediately be noted that even at twenty-three years of age she has been breaking seriously as rheumatism and heart, digestive tract and nervous system. As stated, she has been incapacitated from her work for several months because of shortening of breath, (signifying her heart irritation), lassitude, and painful rheumatism. Immediately we see that this patient must have had either a very serious overload to produce an acquired susceptibility in these various tissues, a symptom group which is very unlikely to occur since acquired lesions are so largely in the nervous system, or she must have had a very marked inherited susceptibility or naturally low defense for this type of infection.

To determine the latter we will look to her brothers and sisters who have the same sources of defense. She has two brothers and three sisters, all five of whom have had acute rheumatism; and one brother and two sisters have had heart involvement. This suggests immediately that they, too, must have had either a marked susceptibility or a very unusual overload. A study of her father and his immediate relatives shows that he was an invalid with heart involvement, with recurring attacks of rheumatism. He had not been able to do much more than half a man's work for many years and for long periods had been virtually an invalid. He has since died, at the age of fifty-seven, of acute heart involvement after a protracted bedridden illness. The father's mother died also of heart involvement with dropsy as an expression. The father's sister is an invalid at this time with heart involvement and hypertension, nephritis, and acute rheumatism, and has had one stroke at sixty-two years of age. On the other side of the ancestry we find this patient's mother died at fifty years of age of malignant endocarditis, about two years before the

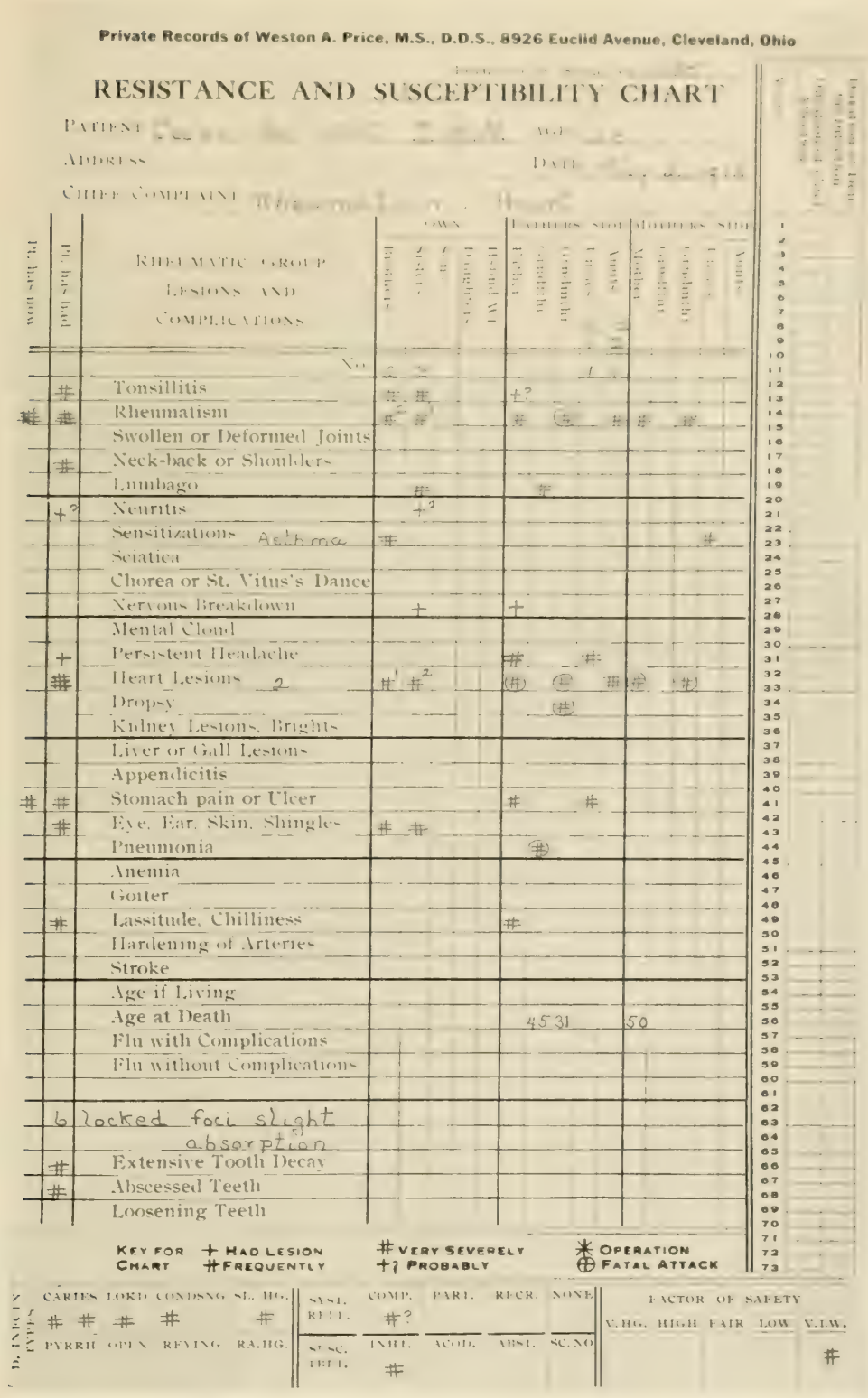

FIGURE 265. RESISTANCE AND SUSCEPTIBILITY HISTORY CHART OF CASE NO. 385. NOTE NINE CASES OF HEART DISEASE IN FAMILY, WITH FOUR DEATHS.

patient presented, after a long bedridden illness, and her mother, the patient's grandmother, died of heart involvement. Both this patient's mother and mother's mother had also suffered severely from rheumatism. The patient's father and a brother had each suffered severely from a type of nervous indigestion.

We find, then, an illustration of what we have found so many times in these studies: that when an hereditary susceptibility comes in from both sides of the ancestry, the offspring tend to break in these same tissues; and further, that while they break in the same tissues, the break tends to come much earlier than in the ancestry. We have, then, a family of six children, the oldest of whom was twenty-five, all suffering from acute rheumatism either at this time or had in previous time, and three of whom were suffering from acute heart or had in the past. This clearly establishes that this patient's best is far too low to withstand the normal overloads of life, if we would assume some dental infection as being a normal overload for a normal individual.

But there are other overloads, as we have shown so frequently, which combine with dental infection overloads greatly to aggravate them. Young people with invalid parents to sustain, having the care not only of their own maintenance but of the maintenance of the invalids, are very likely to have a capacity physical load which may easily become more than a load; or, in other words, a distinct overload. We must consider then that notwithstanding every overload that we may take from this patient, including the dental involvements, she should be expected to have to maintain a struggle throughout life to retain even comfortable health.

A physical examination of the patient revealed a mitral murmur and an accentuated pulse rate, so typical of an irritated and weakened heart. What should the dental diagnosis be in this case? And before making it, remember that as she appeared she brought all the vanity of an ignorant girl. She did not want to lose her own front teeth. She was afraid to lose any molars for fear her face would settle in. She did not wish to wear a plate for fear it would affect her expression and speech. She looked just like, so far as the ordinary dental observer would have appreciated, all the rest of the girls of her age; and this background that we have worked out was not any information that she brought to us, but was information that we had to go after. I stress this because we tend to justify our diagnoses on the presumption that we have a knowledge of the patient, adequate for making the important decisions. My fear is that this is seldom true.

The incidence of heart disease as a cause of death increases

very rapidly and constantly with age. This has been most strikingly brought out by Dr. Louis I. Dublin,[1] statistician for the Metropolitan Life Insurance Company, who, in a paper read before the Boston Association of Cardiac Clinics, Boston, May 18, 1922 (published in The Nation's Health for August, 1922), stated as follows:

"The first point that comes to view from an examination of the tables and of the graphic illustration is that the incidence of heart disease as a cause of death increases consistently with age. At the age period 35 to 44 when persons should be at the height of their productivity, one white person dies from heart disease in every thousand living and two colored persons out of each thousand. At the age period 65 to 74, the number of deaths from heart disease has increased to about 15 in each one thousand living, or to put the facts in another way, deaths from heart disease constitute 9.3 per cent of all deaths at ages 35 to 44, but, at the older period, 65 to 74, they are responsible for 21.9 per cent of the deaths. There is no exception to this rule. The rates are also very much higher for colored persons than for whites. The sex ratios of heart disease mortality are also rather interesting. The rates are usually higher for females than for males up to age 30. From that age onward, the rates for males are higher, the difference becoming regularly greater with advancing years."

These studies of the Metropolitan Life Insurance Company are particularly important in connection with the data that we have accumulated from our clinical practice and research. An analysis of the data shown in Chapter No. 4, Systemic Structural Changes, reveals the important fact that 100 per cent of the individuals suffering from heart involvement have extensive caries. This is also shown in Figure 83 of Chapter 9, The Relation of Dental Caries to Systemic Disturbance. If, then, the percentage of death from heart involvement increases very rapidly after the age of forty-five, is it simply a coincidence that these patients, in nearly 100 per cent of cases, have extensive caries and consequent apical involvement? It is too early to undertake to publish extended statistical data on this point, but the evidence at hand demonstrates that the incidence of death from heart involvements is very greatly reduced for the same age periods among the individuals with a history of heart involvement who have had their dental infections removed, as compared with those with that history who have not had their dental infections removed.

In other chapters, we have discussed and interpreted the path-

[1] See bibliography.

ology about the infected tooth in comparison with the same condition in other patients and its significance in relation to the systemic defense. We have shown that the changes in the supporting structures about a root apex are primarily records of the reactions of that individual patient to that type and quantity of infection, and that that reaction is a protective one in that it is largely Nature's effort to maintain a quarantine about the tooth, or is the effect on the one hand with a patient with high defense and relative safety, or a record of the reactions of the local irritants upon the supporting structures which are not adequately contributing in an adequate defense for the patient.

Applying that information to this patient's case, we find that the total quantity of infection involved in the lateral tooth with the putrescent pulp is sufficient in normal patients to develop a very acute inflammatory reaction about the root apex with the production of soreness, and therefore a tender tooth, and usually with a fistula. This patient's lateral tooth with a non-vital pulp not only has no fistula, but has no extensive area of absorption, has no history of soreness. What I wish to stress is that the very absence of these symptoms is a bad sign and not a good sign, and argue for the extraction of this tooth and not for its retention, since it has as much infection as would be available in a putrescent pulp. Our diagnosis, therefore, was that her immediate safety demanded the removal of all dental infection possible, which included not only teeth with putrescent pulps and chronic apical lesions, but those with deep caries involving, as did her molars, the major portions of the crowns of the teeth even though the pulps were vital. And these molar teeth were condemned not only because of the difficulty of being certain regarding the amount of infection in their pulps and the difficulty of determining how completely Nature might eliminate that infection, but because the probability of these pulps' dying under any restorations that might be put upon them is so great and the effect of such an outcome would be so serious that we are gambling the patient's health and very life against the problem of a questionable service of these teeth. The odds in such a case are far too great against the retention of the tooth. Even a toothless patient with a heart that will work, even with a murmur, is infinitely better than a quantity of gold crowns or any other type of more approved dental restorations, and they incapacitating the patient. That heart can maintain life only under the most favorable possible conditions; and the result has abundantly justified our decision. In a few weeks' time, this girl was back to work. In the five

years that have intervened she has not lost a day because of her rheumatism or heart involvement. She gained over twenty pounds in a few months' time, and all the money in the world could not compensate her for the mistake that would have been made by a less intelligent program.

It is important to note that the very thing that we have indicated would be likely to happen, had already happened with this patient in question. Her brothers and sisters will tend to have the same type of defense as an ancestral legacy, and one brother and two sisters have also broken in the last five years since this patient presented, and with quite similar symptoms and marked benefit. However, we must, in these cases, remember that the prognosis must always be influenced by the nature and degree of this inherited susceptibility. These patients should plan their lives not only to prevent all overloads that are within reach of their planning; but so far as their dental infections are concerned, they are largely at the mercy of the dentist in whose hands they may either choose or be compelled by circumstance to place their lot. This, then, is fundamentally a responsibility of the dental profession; and while the members of that profession may be largely responsible for the carrying out of the teachings, the ultimate responsibility must go back to the dental colleges which furnish the ideals and the methods for their being carried out.

And again we stress how many of the one in ten funerals that go by your window because a heart has given out, have we as a dental profession either helped to produce or failed to prevent. As I dictate this paragraph, my memory goes back to patient after patient whose life has gone out prematurely at forty, fifty, and sixty years of age, from heart involvement and other complications, but particularly with heart, and in whose mouths there were teeth which, according to my information at that time (which was the teaching of dental practice) had not sufficient evidence of pathology to condemn. As I would now interpret those teeth, what I mistook to be insufficient evidence of pathology, was an inadequate local reaction; and the lack of rarefaction or evidence of condensation of bone were really evidences of that poor defense; and I have no doubt that many of those patients, some of whom had come to be very dear friends, might have lived for years had I known to put into practice what I am teaching in this book. While ignorance may be bliss, there is perhaps no pain or grief like that expressed in the following words:

"Of all sad words of tongue or pen,
The saddest are these: 'It might have been!'"

CHAPTER LX

CIRCULATORY SYSTEM.

DISCUSSION.

In this group we will study the various lesions of the circulatory system which may be influenced or produced by dental infections. These will include endocarditis, myocarditis, pericarditis, heart block, aortitis, angina pectoris, phlebitis, arteriosclerosis, hypotension and hypertension, anemia, leucopenia, leucocytosis, lymphopenia, lymphocytosis, bacteremia, and glycemia. In the past the emphasis in our thinking has been placed upon heart valve lesions probably, both because of their severity and frequency and also the fact that there has been very little known of other lesions', of the circulatory system, being produced or aggravated by dental infections. Since one in ten, and probably a little more, according to the data in both England and the United States, of the deaths of all ages reported from month to month, are caused by heart involvement, it becomes immediately apparent what a great responsibility falls upon the dental profession. If it fail to remove the causes of any of these heart involvements, and more particularly if it produce conditions which tend to develop them, if, as many believe, approximately 90 per cent of heart involvements are the result of streptococcal invasion, we see an immediate suspicion thrown upon the dental source. This suspicion is increased by the finding that practically all dental infections, apical or gingival, contain streptococci, and in the former, particularly, of types that may readily develop elective localization for heart tissues. The results of these researches throw a very important new meaning and importance on this whole problem for it has been found that in a group of 681 families there were more cases of heart involvement in 100 families than in the other 581, and in only 51 single cases were patients found to have developed a heart lesion where no other member of the family was recorded to have developed the same. In other words, in 92½ per cent of patients in whom heart lesions were found, at least some other members of that family were recorded to have had a heart lesion.

Since this presentation is a report of researches and not a treatise on pathology, it is not within its scope to do more than outline the main features involved. Since, as shown, such a large percentage, namely from 10 to 11 per cent, of the deaths of all ages which occur in our civilized communities of today is, according to statistics, from some form of heart failure, it becomes one of the most important problems in the health of the community to prevent, in so far as possible, heart lesions. While authorities differ as to the percentage of the various types of infection found in heart lesions, it is quite generally conceded that organisms of the streptococcal group produce a very large proportion of these involvements, some placing them as high as 95 per cent. It certainly is high, whatever the exact percentage may be in a given community. It is not within the range of this study, or at least we have not included it as such, to make estimations or determinations of the incidence of dental infections and heart lesions of focal origin. I am, however, convinced that there are very many such cases and many in which dental infection may not have been the first source of focal entrance. Indeed, many of our histories suggest that tonsil involvements in children have been followed by some heart disturbance from which the patients have apparently quite completely recovered. Since, however, they had an inherited susceptibility, or lowered defense, for that tissue, and since one streptococcal infection tends to predispose toward another, the presence of a dental infection has tended to re-establish acute involvements of the heart and circulatory tissues.

ENDOCARDITIS.

Endocarditis, with its involvements of the heart valves and lining membranes of the heart, constitutes one of the most serious affections of mankind. For years it has been recognized that it frequently appeared as a sequel to tonsilitis. It now seems very necessary to study carefully its possible relationship to dental infections. We have already discussed, in Chapter 17, the case of a boy, fifteen years of age, who was brought in by one of the district nurses because he had rheumatism. We very quickly discovered that he had a serious heart involvement with much enlargement and rotation outward of the apex. The history of his case showed that about four weeks previously he was afflicted with an acute attack of pulpitis or tooth-ache at school. This seemed definitely located in the mandible on the left side in the first permanent molar. About a week after his acute tooth-ache,



FIGURE 306.—ACUTE ENDOCARDITIS IN TWO RABBITS FROM 1 CC. CULTURE FROM DECIDUOUS TEETH SHOWN, FROM CHILD WITH ENDOCARDITIS.

he developed acute rheumatism and myositis so severe that he could not get up from his seat in school, which necessitated his being carried home. The acute condition subsided in about a week and he returned to school. The teacher reported that he was very lazy. The suspected tooth was extracted; but before doing so, careful examination was made to determine the condition of the pulp. The tooth had very extensive caries in the crown, which, however, did not expose the pulp, though it had infected it. The tooth responded very sharply to changes of temperature and was sensitive to instrumentation within the cavity. On the removal of the tooth, the pulp was opened after sterilization of the dentin, cultures were taken from the pulp, which grew out pure streptococci, and this was inoculated into thirty rabbits. Ninety-three per cent developed acute endocarditis and 100 per cent acute rheumatism. In the chapter on tissue affinity qualities, characteristics of organisms, we have referred to the fact that subsequent inoculation of a second group of rabbits with this strain, after it had grown on artificial media for seventeen days, showed its elective localization very greatly changed. The percentage of hearts involved had fallen to 10 per cent. Incidentally, the boy died in about seven months from acute endocarditis.

In cases of acute endocarditis, the elective localization quality of the organisms seems particularly marked. In Figure 266 are shown two rabbits which were inoculated with the culture taken from the shown deciduous teeth, two of which had infected pulps, of a little girl nine years of age. (Case No. 1058.) She had been in bed five of these nine years. We do not know the nature and history of the early attacks or the probable source. The culture taken from the pulp chambers of the extracted deciduous teeth was injected into the ear veins of three rabbits and all developed acute endocarditis and myocarditis. The one shown to the left had the greatest enlargement of heart that we have ever seen in a rabbit on posting, and that shown to the right died on the thirteenth day from the acute endocarditis. The rabbit shown to the right also had rheumatism, with marked enlargement of the axillary lymphatics, as shown. These rabbits were inoculated with the washed culture of the organisms taken from the teeth.

It is very significant that in children suffering from endocarditis, rheumatism, or chorea, there is a marked tendency to delayed absorption of the roots of the deciduous teeth and delay in their

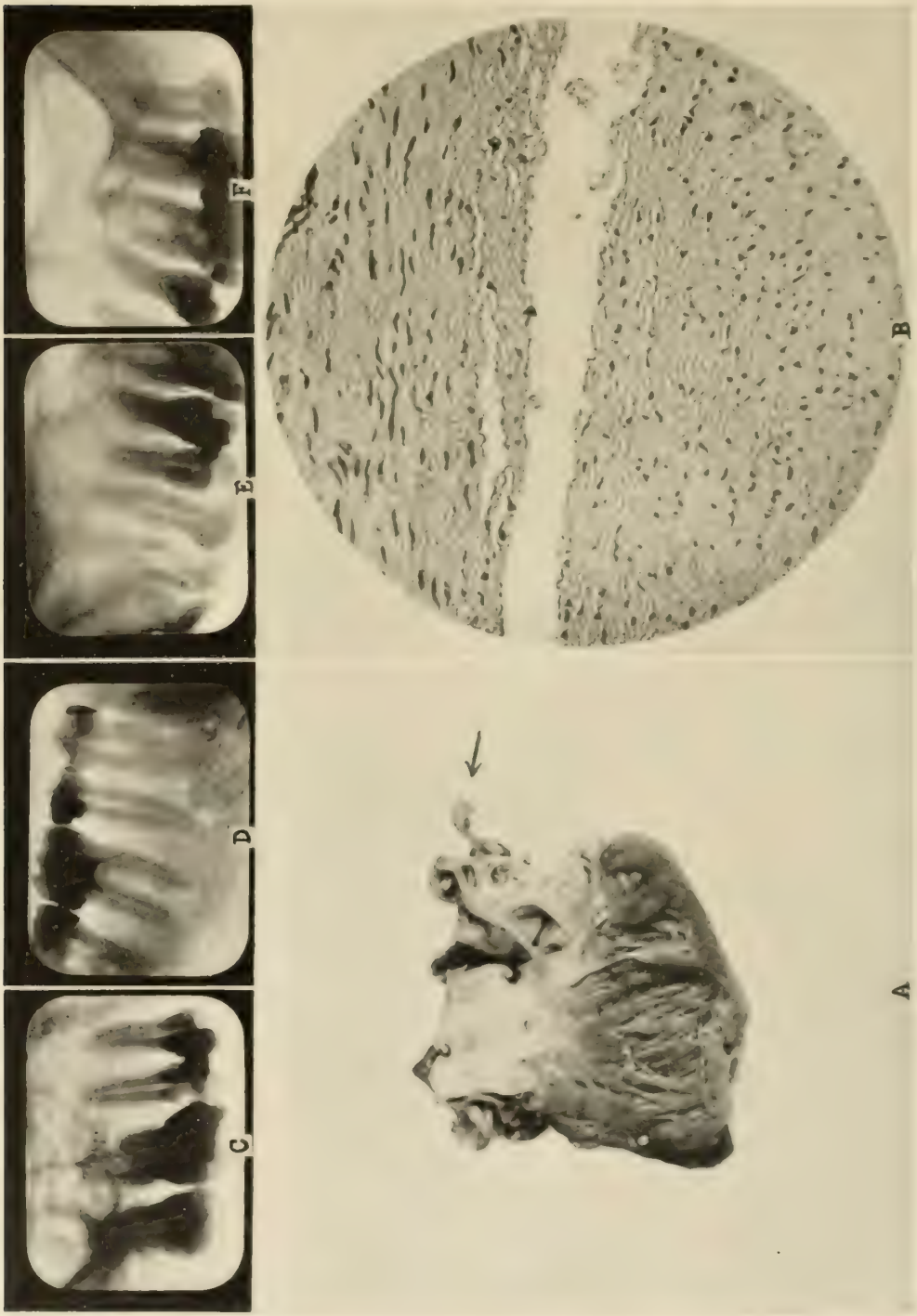

FIGURE 267. FATAL ENDOCARDITIS IN A RABBIT INOCULATED WITH ABOUT ONE-MILLIONTH OF A GRAM OF ORGANISMS FROM THE WASHINGS OF CRUSHED TEETH FROM A PATIENT WITH ENDOCARDITIS. HEART SHOWN IN A; THE TEETH IN C AND D. B, AN AORTIC ARCH INVOLVEMENT FROM ANOTHER RABBIT INOCULATED FROM TWO OTHER TEETH FROM SAME PATIENT, SHOWN IN E AND F.

exfoliation. This seems definitely to be related to depressed ionic calcium of the blood and disturbed calcium metabolism, which not only produce calcium hunger, but the very absence of the calcium ions directly disturbs, as I have shown, the metabolic processes and cell activities of practically all tissues and particularly those relating to morphological changes. This is an exceedingly important, and often serious, problem, for the very individuals who should be free from focal infection of deciduous teeth, are compelled to retain that infection because of disturbed metabolism relating to their exfoliation. I have no doubt that many a child has died from heart involvement who would have recovered had the infected deciduous teeth been removed. In these cases these infected deciduous teeth produced practically no discomfort to the individual; and we have been very often misled in presuming that because they were comfortable they were safe. Only those who have paid the price can know the seriousness of this mistake. I, myself, am one who was mistaken about the safety of my boy's deciduous teeth. Though they were roentgenographically in good condition, several of them having been treated and root-filled, they proved on extraction to be seriously infected and were being carried by an individual who had a heart involvement growing out of one severe attack of tonsilitis followed by acute rheumatism.

It is not necessary, however, that the quantity of organisms be large in strains having marked elective localization, which quality we have found only in acute processes. The heart shown in Figure 267-A is that of a rabbit which died in two weeks after being inoculated with the unfiltered washing from three teeth, two of which were root-filled, shown in Figure 267 in C and D. This rabbit developed both acute endocarditis and aortitis. We appreciate the impossibility of proving that these hearts were normal, and since aortic arch lesions have been reported in apparently normal rabbits, it makes an uncertainty as to whether this aortic arch lesion may not have been present previously, if not in its present aggravated form, in some form perhaps very much less severe. The fact, however, that the rabbit died with endocarditis from this small amount of infection is very important. The actual weight of the bacteria injected would probably be in the order of about a hundred millionth of one gram. Another rabbit inoculated with a culture from two other teeth from this patient, (Case No. 1113) shown in Figure 267 in E and F, developed aortic



FIGURE 268.—TWO RABBITS WITH ENDOCARDITIS FROM THE CULTURE OF THE APPARENTLY NORMAL TOOTH IN THE INSERT. PATIENT WAS PROSTRATED BY ACUTE ENDOCARDITIS.

ulcer with marked degenerative changes in the muscular coats and intima. The following is the pathological finding in this heart tissue:

"*Inverted Ocular* shows three small semicircular pieces of tissue from blood vessel, where the intima and media coats are well stained with a red-pinkish color; the adventitia with a light pink. In all the three sections there is an elevation at the center of the intima and media.

"*Low Power.* The section represents blood vessel wall (aorta). The intima is not well shown; only here and there can be seen remnants of the intimal endothelial lining. The media at the central part of the section shows distinct changes, namely for about 2 to 3 mm. it is swollen, and separated into two parts, which might be due to mechanical causes. The swollen portion shows many cells in degenerative processes; vacuoles can be seen surrounding the nuclei. There are practically no changes in the layer of adventitia surrounding that particular place of the media.

"*High Power.* The media at the central part shows fatty degeneration, the cell being filled up with small vacuoles which are pushing away the nuclei. The nuclei are taking good stain. There are no evidences of any cellular infiltration. This condition is found only at the central part of the section. The rest is in good condition.

"*Diagnosis.*—Atheromatous degeneration of the aortic arch."

In patients with a definitely developed susceptibility to streptococcal infection, expressing itself in heart irritation, there is a marked tendency to recurrence, particularly with the redevelopment of the focus as a source from which the infection may be developed. Figure 268 shows such a case. (Case No. 581.) About two years ago, she was brought in in a condition of extreme prostration from endocarditis and myocarditis, and was carried to our ward and operated upon in bed with the greatest possible care and consideration for her weakness. Her improvement was very rapid and pronounced. In a couple of weeks she was home about her house, and in six weeks her physician was permitting her to take light responsibilities about the home, and even walking up and down stairs. The heart enlargement had decreased and its irritability subsided. About two years later she suffered a recurrence of her endocarditis, with weakness and prostration and very marked dyspnea, which compelled her to gasp for breath about every half minute. Careful study of her mouth, roentgenographically, did not reveal a source of dental infection. However, the use of

the electrical and thermal tests for vitality revealed the presence of a non-vital pulp in the central incisor shown in the insert A. Note the absence of roentgenographic evidence. This tooth was extracted and its pulp cultured. Figures B and C show the hearts of two rabbits inoculated with this strain, both of which show marked endocarditis. In B, there are shown two large masses of coagulated exudate found within the pericardium. This patient's improvement was so marked that again in a few weeks' time she was at home doing most of her household duties, even walking up stairs.

BACTEREMIA.

Bacteremias are coming to be recognized as of frequent occurrence. Their symptoms may be very definite from the early stages, having much the appearance of an approaching febrile disturbance, the severity increasing progressively or intermittently, with or without evidences of heart involvement. The diagnosis seems to be most easily established by blood culture. The attacks may, however, come on violently and seem to be related to tonsilitis, surgical operation, an abscessed tooth, or some such acute process. It is, of course, always difficult, if not impossible, to tell with definiteness the source of the infection. The most significant thing is that they occur in individuals with an abnormally low defense for streptococcal infection, for the organism involved is very frequently the streptococcus. A close study of the history, morphology of the organisms, the biological characteristics of the strain, as established by fermentations, etc., together with the identification of the strain in some focus, will be an important procedure in determining the etiology of the disturbance. Such a case is shown in the following:

Case No. 926. Figure 269 shows in B an area of radiolucency to the Roentgen-ray, about the apex of the lower left second molar. This tooth was extracted, and attached at its apex was a very large granuloma, shown with the tooth in A. The patient was suffering at the time from rheumatism and a mild fever. Her symptoms became rapidly worse after the extraction of the tooth and curettement of the socket. She was kept in bed in our private ward, and blood cultures showed organisms in abundance in the blood stream. The lymphatics showed marked involvement, and cellulitis developed, involving the neck. E, F, and G show organisms grown out by culture from the aspirated blood from the

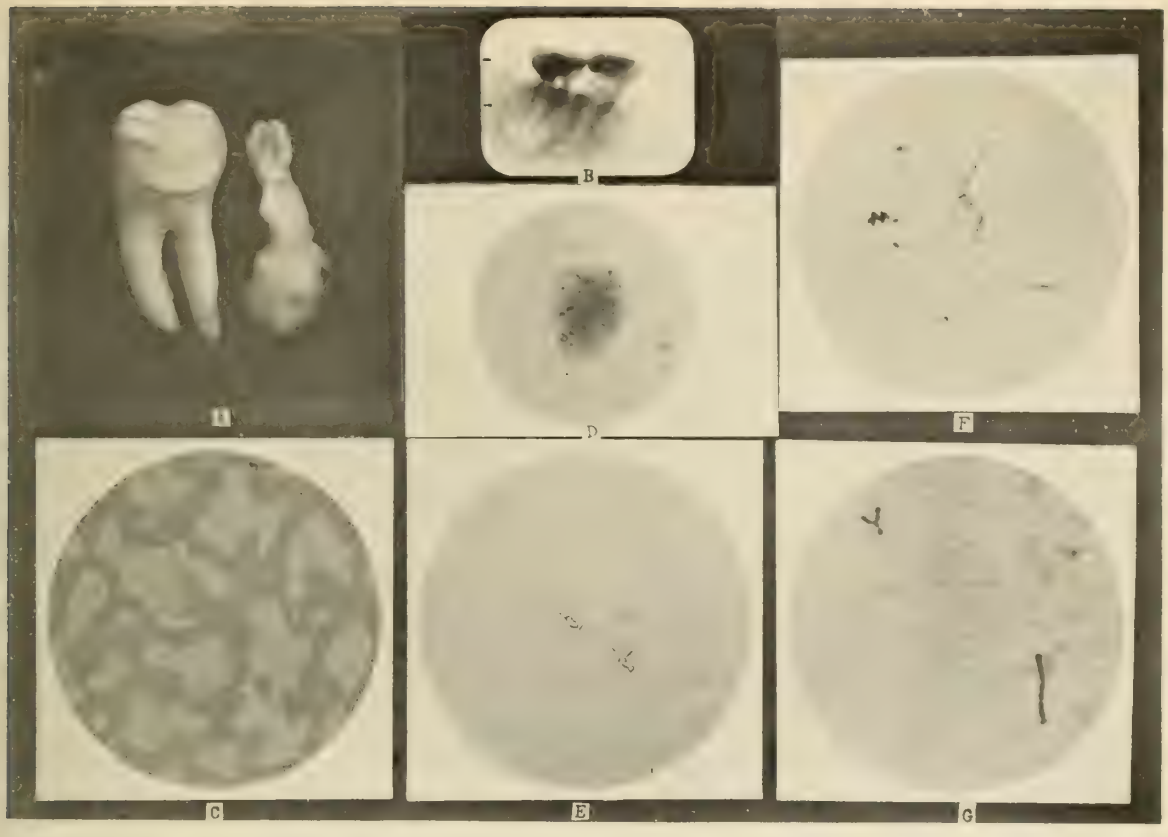

FIGURE 269. STREPTOCOCCAL BACTEREMIA: A, A DEGENERATING GRANULOMA OF UNUSUALLY LARGE SIZE, FROM THE SECOND MOLAR SHOWN IN B. E, F, AND G SHOW ORGANISMS GROWN FROM THE BLOOD TAKEN FROM THE MEDIAN BASILIC VEIN ON THREE DIFFERENT OCCASIONS. C, ORGANISMS IN THE BLOOD ASPIRATED FROM THE NECK; AND D, ORGANISMS IN A PHAGOCYTING LEUCOCYTE.

median basilic vein on three different occasions. C shows organisms in the blood aspirated from the neck tissue; and D, organisms in a phagocyting leucocyte. The culture grown from this tooth was inoculated into rabbits. Figure 270 shows one which developed acute rheumatism of the wrist joints and fore paws, which later developed into a typical deforming arthritis. The legs were bowed sideways and the rabbit walked on the sides of its fore feet, and for a long period was unable to hop, stubbing along with great difficulty like an old man nearly crippled from deforming arthritis. This rabbit lived, in apparently fair health, for twenty-five and one-half months after this inoculation of a single dose of the culture from this tooth (the amount of the dose being 1 cc. of a 24-hour growth of dextrose-ascites culture) and died finally of an acute or chronic peritonitis which, at post-mortem, within a few minutes after his death, showed in culture a streptococcus growing in diploid forms similar to that injected, in the multiple adhesions of the viscera and peritoneum. It is of interest that we never have found this type of infection or of le-



FIGURE 270. OLD PATRICK. THIS RABBIT LIVED FOR TWENTY-FIVE AND ONE-HALF MONTHS AFTER ONE INOCULATION FROM CULTURE OF TOOTH, FIGURE 269. HE DEVELOPED FIRST ACUTE RHEUMATISM, THEN DEFORMING ARTHRITIS, HAD BOWED LEGS, AND WALKED ON THE SIDES OF HIS FEET.

sion in the animals dying spontaneously that have not been previously inoculated with streptococcal strains. Figure 270 shows the roentgenograms of the bones of the forelegs. Note the deformity and enlargements. Figure 271 shows the rabbit as he was nineteen months after the inoculation. While he had grown large and heavy, he tended to be adipose and decrepit. As shown by the roentgenograms of different periods, there was a slow tendency to reduction of the arthritic deposits but never a restoration of function of the joints.



FIGURE 271. OTHER VIEWS OF OLD PATRICK WITH HIS DEFORMING ARTHRITIS. NOTWITHSTANDING HIS PERMANENT DEFORMITY, HE GREW VERY LARGE AND HEAVY.

Individuals with a very marked streptococcal susceptibility frequently have characteristic symptoms which are very suggestive. Their normal temperature is a subnormal of from one to four degrees. They may have a temperature which goes above this subnormal two or three, or even five or six degrees, usually a little above or a little below the true normal. This must be kept in mind; otherwise, it would not be recognized as a febrile disturbance. Their disturbances, however, are quite different from individuals with localizations without bacteremia.

Case No. 987.—Figures 272 and 273 show several views of rabbits inoculated with a culture from another such case. This patient's eyes were, frequently, both reddened. Their symptoms were very severe. During a period of about six years she has had severe recurring attacks; has never been entirely free for more than a short period of time, if at all; and her case represents a type for which the prognosis must always be extremely guarded. The symptoms have tended to develop in a somewhat definite order, one of the earliest of which was the eye involvement which would go through progressive stages of severity and become very painful and sensitive to light, after which, there would be considerable dimness of vision, so severe on several occasions that for days or weeks it would be difficult for her to make her way alone across the street. The use of an autog-

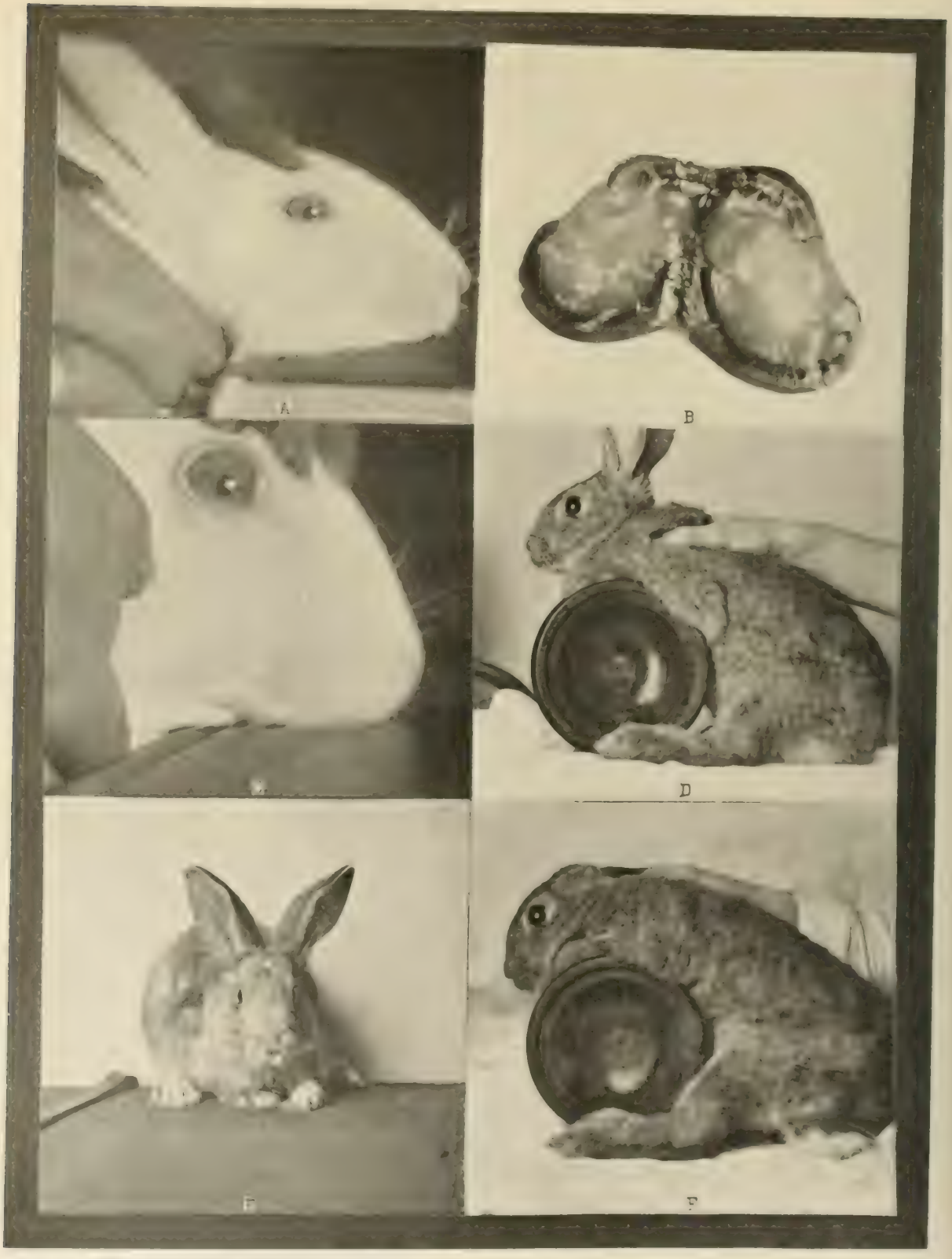

FIGURE 272. MULTIPLE LESIONS PRODUCED IN RABBITS FROM A CASE OF RECURRING STREPTOCOCCAL BACTEREMIA, CASE 987.



FIGURE 273. OTHERS OF THE MULTIPLE LESIONS PRODUCED BY THE DENTAL CULTURES FROM CASE 987 WITH STREPTOCOCCAL BACTEREMIA.

enous vaccine administered at the time of the onset of one of these attacks (or the earliest symptoms of one of these cycles) tended to abort the development of the cycle. The eyes would clear up without the customary pain, congestion, etc., and would not be followed by the acute rheumatism, though occasionally with mild symptoms of it.



FIGURE 274. SOURCE OF CULTURE FOR INOCULATIONS FROM CASE 987.

The culture from the tooth, shown in Figure 274, when inoculated into rabbits, produced expressions in many and varied tissues. A and C of Figure 272 show the progressive involvement of a rabbit's eye; E, acute rheumatism; D and F, views, on different days, of the left hind leg of a rabbit showing a very marked edema which subsided without joint changes. A, B, and C of Figure 273 show extensive rheumatic involvements with enlargement of the axillary lymphatic glands. Figure 273-D shows hemorrhagic infection of the pulp, so marked that it shows readily through the tooth *in situ*. Figure 272-B shows an acutely nephritic kidney. Cultures from this woman's tooth, blood stream on several occasions, and eye at the time of the acute inflammatory processes of it, gave the same organism and same type.

It is important to note that this patient's symptoms were very general and diffuse, which tends to be true of the systemic expressions of bacteremias. She had involvements of her eyes, acute rheumatism, heart irritations, frequent febrile disturbance, and edema, any or all of which symptoms would tend to become rapidly worse, but usually in succession. Cultures inoculated into animals from the dental infection, the blood stream, and the eyes, similarly tended to produce very diffuse disturbances. Just as this patient's wrists would be swollen in twenty-four hours and very painful with edema, which condition would subside quite as rapidly, just so the animals tended to be affected. The hind leg, shown in two views of twenty-four hours apart, illustrates the rapid reduction of the edema. Within twenty-four hours after inoculation this rabbit was carrying this hind leg, with the edema and swelling of its foot. The swelling disappeared. Another in-

oculation was given and again in twenty-four hours it was carrying the foot. It will be noted that the infection in these rabbits is more generalized than is usually found, as I have shown in other chapters.

It would seem probable that this streptococcal invasion of the blood stream, in so abundant a form as we have found it, would make possible the securing of this organism in almost any tissue of the body during these periods; and if any tissue were capable of becoming, because of degeneration, a pabulum for the growth of the organisms, it would readily be inoculated from the blood stream; and if such a patient should develop a non-vital pulp, it would seem very certain that it would become immediately infected with this strain. In this sense, it may probably be said that, the systemic infection, or bacteremia, has caused the dental infection rather than that, the dental infection has caused the bacteremia. It should be kept in mind, however, that all Nature's normal tissues lend themselves to Nature's mechanisms of repair and defense so readily that in normal tissue Nature is able, generally, completely to eliminate the systemic infection. If, however, any tissues such as dentin and pulp tissue have become non-vital, Nature has no mechanism again to place that tissue in a sterile condition, and it immediately becomes a focus, and permanently so, so far as Nature is concerned, and, notwithstanding the violent opposition of many members of our dental profession, such infected tooth structure is, in effect, if not literally, an infected sequestrum.

RAYNAUD'S DISEASE.

Raynaud's disease is a vasomotor neurosis which is supposed to affect chiefly children and young adults, but which has been present in a number of cases studied in this clinic. Its etiology is very obscure. In the severe cases it is marked by capillary congestion and livid swelling which may eventually result in gangrene. It not infrequently happens that individuals afflicted with this disease will have one after another of the fingers or toes amputated as the disease progresses. The affection is very little affected by local or systemic treatments which are designed to affect the capillary circulation. One of the cases of particular interest in this connection is as follows:

The patient, male, about fifty, had a severe affection of the toes of one foot, one of which had been amputated about three years previously. A second toe became acutely involved and proceeded to a gangrenous necrosis and required an amputation about

one year before. When he presented to me, a third toe was seriously affected and there seemed every indication that it would suffer the same fate as the other two. He had several dental infections which were removed, which resulted in a very marked improvement in his Raynaud's disease which did not manifest itself again for a year, after which time I lost connection with him and do not know his later history. It seems very probable that this disturbance was largely a sensitization process in its early stages.



FIGURE 275. ROENTGENOGRAPHIC APPEARANCE OF TEETH, CASE 1211 WITH ANGINA PECTORIS. PATIENT APPARENTLY IMPROVED.

ANGINA PECTORIS.

It is uncertain to what extent dental infections contribute to angina pectoris. We have, however, records of several cases in which the disturbance disappeared promptly and for sufficient periods of time to warrant the belief that the relief was produced by the removal of the dental infection. To illustrate:

Case No. 1241.—A patient presented with obscure disturbance in the vicinity of the chest and heart. Sometimes he could walk many miles without any discomfort, and on other occasions would be almost prostrated from pain and exhaustion. The dental examination revealed conditions that were considered border-line. They would readily be interpreted, as shown in Figure 275, as having slight pathology. In order to strengthen our basis for our diagnosis as greatly as possible, he was carefully examined by the internist of my staff, and we decided to send him to a heart specialist for confirmation or correction of our diagnosis. That report strongly strengthened the basis of our suspicion, and these border-line teeth were extracted, with the result that his angina symptoms entirely disappeared and have not returned, even for a moment, for nine months. This was particularly important, as will be seen by referring to the roentgenograms in Figure 275. There is so little evidence of dental pathology. These teeth, when cultured, showed definite internal infection with streptococci which, when inoculated into rabbits, produced both heart and kidney lesions.

One of the teeth of his case was placed beneath the skin of a rabbit, after having covered with celloidin its entire surface except the root apex. (Note: Our previous experiments have shown that celloidin is but slightly irritating when planted in the tissue of rabbits.) The rabbit proceeded to build an encapsulation about the tooth. A photograph of the encapsulated tooth is shown in Figure 276-B. A local abscess, however, developed and it died in twelve days, having lost 25 per cent. This rabbit's heart appeared congested on posting. On the anterior surface there were two triangular whitish patches about three-fourths of an inch in extension. On cutting transversely over the same, the whiteness extended into the muscle tissue for about one-half millimeter. A photograph of the heart is shown in C, and a section of the heart muscle showing the fatty degeneration is shown in D. The kidneys of the rabbit showed parenchymatous nephritis and local hemorrhages, a section of which is shown in A. This patient died suddenly about one year later.

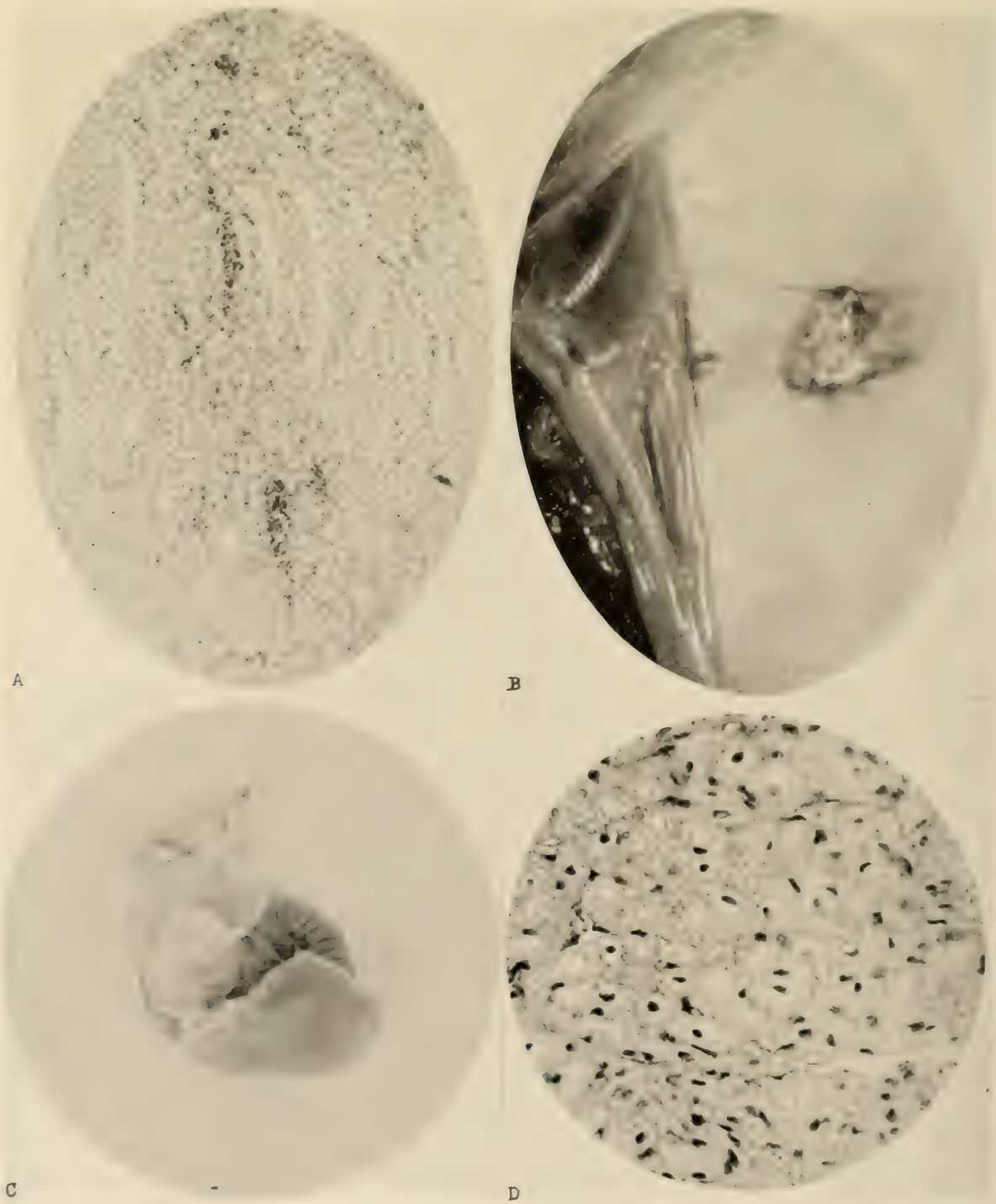

FIGURE 276. EFFECT OF IMPLANTING A TOOTH FROM CASE 1241 BENEATH THE SKIN OF A RABBIT. B, PHOTOGRAPH OF THE ENCAPSULATED TOOTH. C, A PHOTOGRAPH OF THIS RABBIT'S HEART. D, SECTION OF THE HEART MUSCLE SHOWING FATTY DEGENERATION. A, A SECTION OF THE KIDNEY, PARENCHYMATOUS NEPHRITIS.

HEART BLOCK.

Case No. 900.—In the chapter on dental cysts, I discuss a case of a very extensive invasion with absorption of root apices. This patient seventy-six years of age, was brought to us suffering from a very severe central nervous system disturbance and extreme hypotension, which varied sometimes quite rapidly. He had, on several occasions, given evidence of symptoms which his physician had diagnosed as heart-block. After the surgical treatment of his cyst, this symptom entirely disappeared so that he could walk for miles at seventy-six years of age as rapidly and comfortably as most men of thirty; and after two years, he is still free from those symptoms which had so nearly taken his life on several occasions. When brought by the physician, he was considered to be in such a critical condition that we were advised to be extremely careful or he might go out at any moment. The hypotension was quite completely relieved and it, also, for two years has remained nearly normal. Roentgenograms of his case are shown in a figure of Chapter 69.

HEMOPHILIA.

Few, if any, of the effects of dental infection are so marked as the chemical changes in the blood, conspicuous of which are the anemias and hemophilia. A typical case of the latter is as follows:

Case No. 1024.—A man of thirty-eight years of age was referred by a physician with the following history: For three months there had been almost constant seepage of blood from the mucous membranes of the mouth, chiefly about the necks of teeth, with occasional bleeding of the nose and throat. He had been very near death on several occasions. A few weeks prior to his being referred, he had had two blood transfusions which gave exceedingly little and temporary relief. The socket of a tooth extracted three months previously was still bleeding. The roentgenograms revealed the condition shown in Figure 277. Careful examination showed that the hemorrhage was greatest around the non-vital teeth. On the presumption that these teeth were furnishing a toxic substance which was contributing to this condition, we deemed it wise to remove one of these for study and observation of the effect, notwithstanding the great danger and difficulty attending the control of the hemorrhage following the extraction. Extreme care was taken and immediate packing of the socket and retaining of pressure to prevent hemorrhage was



FIGURE 277. HEMOPHILIA. CASE NO. 1024. ROENTGENOGRAPHIC APPEARANCE OF THE TEETH. NOTE THE ABSENCE OF LOCAL REACTION. PATIENT NEARLY DEAD FROM SPONTANEOUS HEMORRHAGE, CHIEFLY FROM GUMS, FOR THREE MONTHS, AND MOST SEVERE ABOUT ROOT-FILLED TEETH. SEE TEXT.

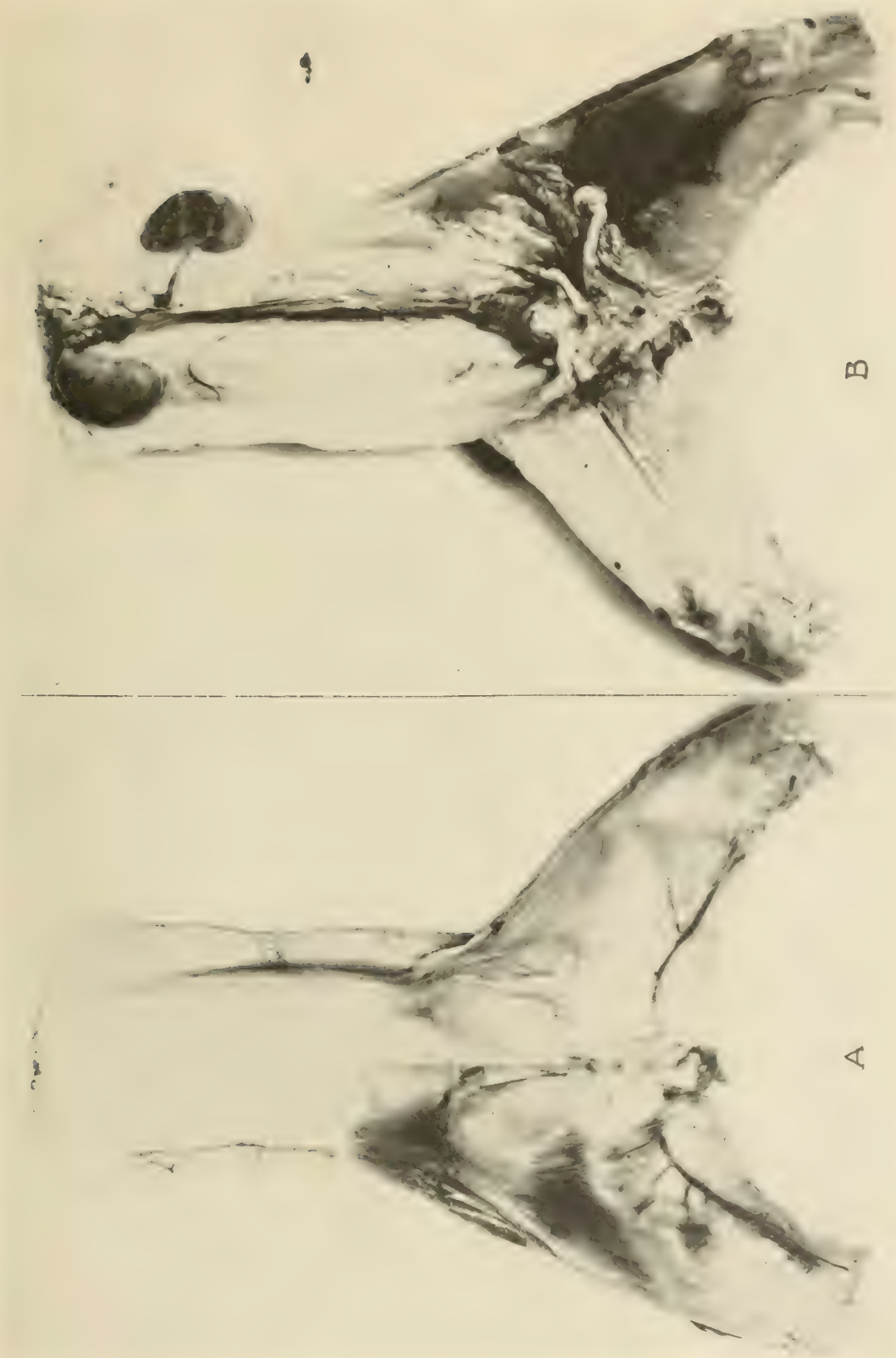

FIGURE 278. SPONTANEOUS HEMORRHAGE IN RABBIT, CAUSING DEATH IN TWENTY HOURS, FROM CULTURE FROM TOOTH, UPPER RIGHT THIRD MOLAR.
SEE FIGURE 277.



FIGURE 279. SPONTANEOUS HEMORRHAGES IN RABBIT'S KIDNEY AND THIGH. CASE 1024. MANY RABBITS DEVELOPED DELAYED CLOTTING OF BLOOD FROM THIS CULTURE. PATIENT GREATLY IMPROVED.

done. Notwithstanding this precaution and the close attention of a skilled nurse, a few ounces of blood were lost in a few hours. The tooth was used to make a vaccine from its culture; the organisms grown from it were also used for animal inoculation. These lengthened the clotting time of the blood of rabbits, which had been found to be normal at a half minute to a minute, to three and four, and in extreme cases to six and ten minutes, which is very unusual for rabbits, it being extremely rare that severe spontaneous hemorrhages occur. In the last thousand rabbits inoculated in the last two years, only a few rabbits have died from spontaneous hemorrhage, one of which is shown in Figures 278 and 279, which was inoculated with the culture from the tooth of this case. It died in twenty hours from extensive hemorrhages into the thighs, legs, viscera, kidneys, etc., and there was so little blood left in the circulatory system that it was impossible even to get a small amount for blood chemistry, which is frequently made in such conditions, by aspirating blood from the heart and larger blood vessels. This rabbit was posted immediately upon its death, which death process was being watched, and there was not time for any clotting of the blood within the vessels, which process was very slow in this rabbit.

With the extraction of this tooth and the use of the vaccine made from it, this patient's condition very rapidly and markedly improved. Three other teeth were extracted with intervening periods of a few days, and in one week's time spontaneous hemorrhage had almost entirely ceased from the mucous membranes of his body, and in four weeks' time he was back at his business with his clotting time reduced from eight and one-half minutes to three and one-half minutes. He had completely lost the hearing of his left ear at the time he came to us, as a result of a spontaneous hemorrhage in his internal ear, which deafness persisted. He continued at his business with but slight interruptions for seven months when he had a hemorrhage in one of his eyes. This laid him up for a couple of weeks, after which he went back on the road. After a very hearty meal, while being entertained at a friend's home, he was taken with distress in his stomach. He came home and had a severe hemorrhage from his nose. This was followed by a distress in his abdomen which was diagnosed as peritonitis. He was taken to a hospital in a critical condition for surgical assistance and, according to the report of his wife, died in a few hours from a complication as an extensive hemorrhage in both the abdomen and thorax. It seems probable that

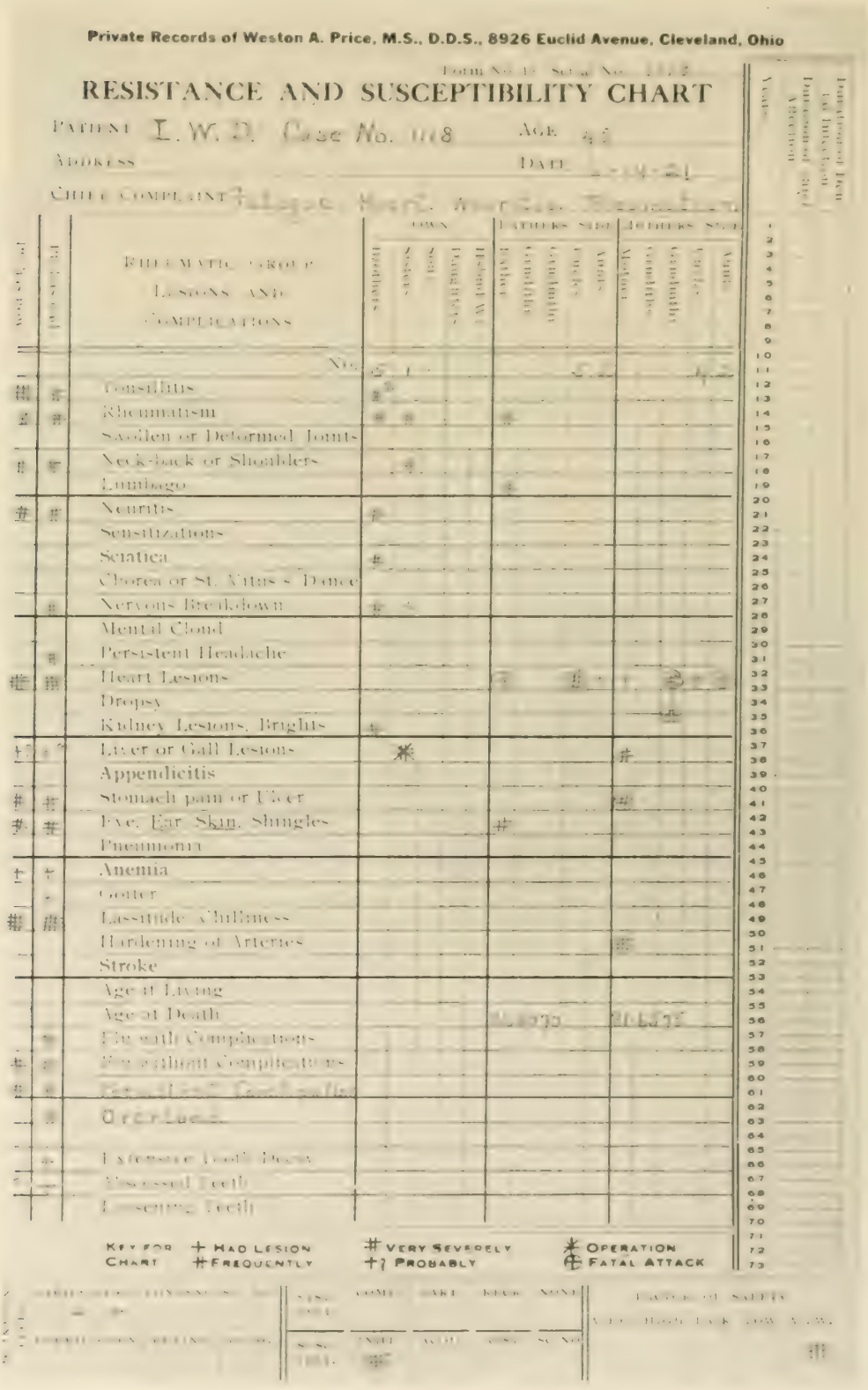

FIGURE 280. SUSCEPTIBILITY HISTORY OF PATIENT AND FAMILY. CASE NO. 1118.

he died in a condition strikingly similar to that developed in some of the rabbits inoculated with the culture from his teeth. This patient's hemoglobin was 70 and increased to 80. His erythrocytes increased from 3,250,000 to 4,700,000. The total calcium of his blood, ionic and combined, was only 8 mgs.

Some of these dental strains have very marked effect upon the various cells of the blood. It is very frequently found that in patients with a streptococcal susceptibility, whether inherited or acquired, the secondary anemias exist. There may be an erythropenia, two or three million, very often three and three and one-half million, which condition rapidly improves with the elimination of the dental infection. There may also be a very marked leucopenia. This condition is so frequently found that its presence is a very important diagnostic symptom. These patients tend to have a leucocyte count of four or five thousand per cubic centimeter. A differential count may show a polynuclear count of forty to fifty-five per cent. These patients are in very poor condition for defense. They tend readily to systemic complications. With removal of their dental infections, this condition frequently very rapidly improves. In Chapters 19 and 20, I have shown that just as these patients have these typical changes in their blood morphology, the rabbits inoculated with the strains from dental infections very frequently develop similar changes, which is also true of the chemical changes in the blood. For more detailed reference to these blood changes, see all the charts in Chapters 19, 20, 43, and 44.

CHRONIC CARDITIS.

There are many striking illustrations of the potential handicap of individuals born of an ancestry having a marked susceptibility to heart involvements. Such a case is strikingly illustrated in Case No. 412, a married man, aged forty-six, who has been suffering from acute heart involvement. There has been a history of heart involvement since seven years of age. He is a semi-invalid. A history of the family and ancestry reveals that his father died of a heart lesion at forty-eight. His father also had rheumatism; four of his father's brothers had rheumatism and one had heart and kidney involvements. His mother had heart involvement, and her mother died of heart trouble. One of her sisters is an invalid with heart involvement. The patient's mother and her mother and one sister all have had rheumatism. He has had acute digestive disturbance not accounted for by food, as have

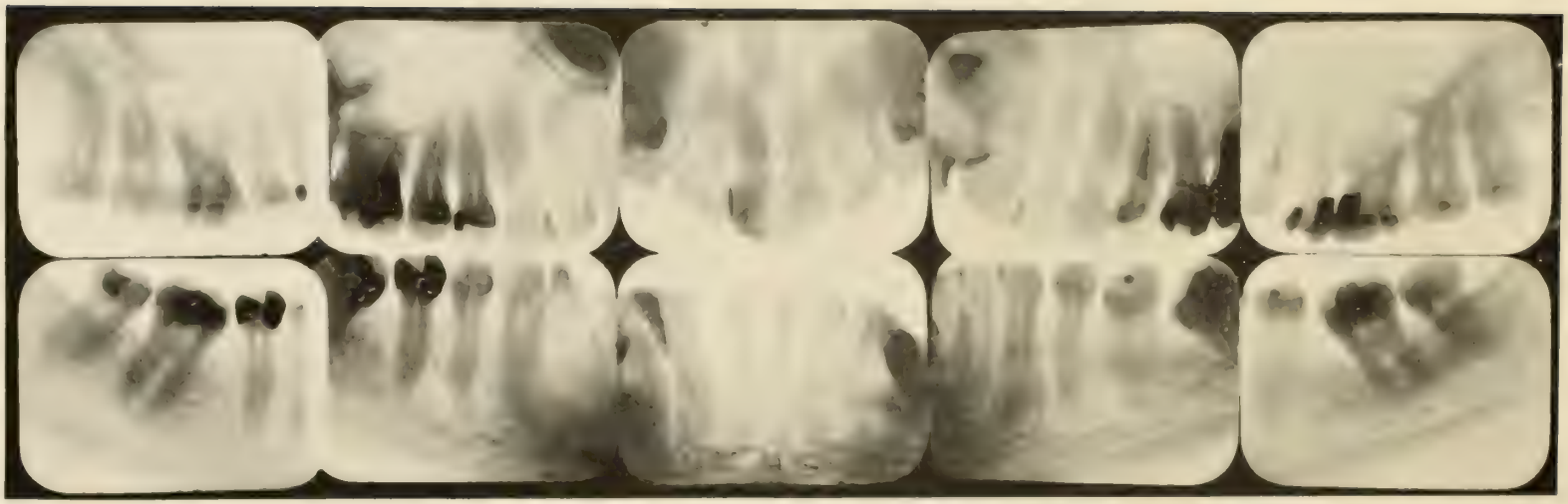

FIGURE 281. ROENTGENOGRAPHIC VIEW OF TEETH OF CASE NO. 1118 WITH RECURRING HEART INVOLVEMENT.

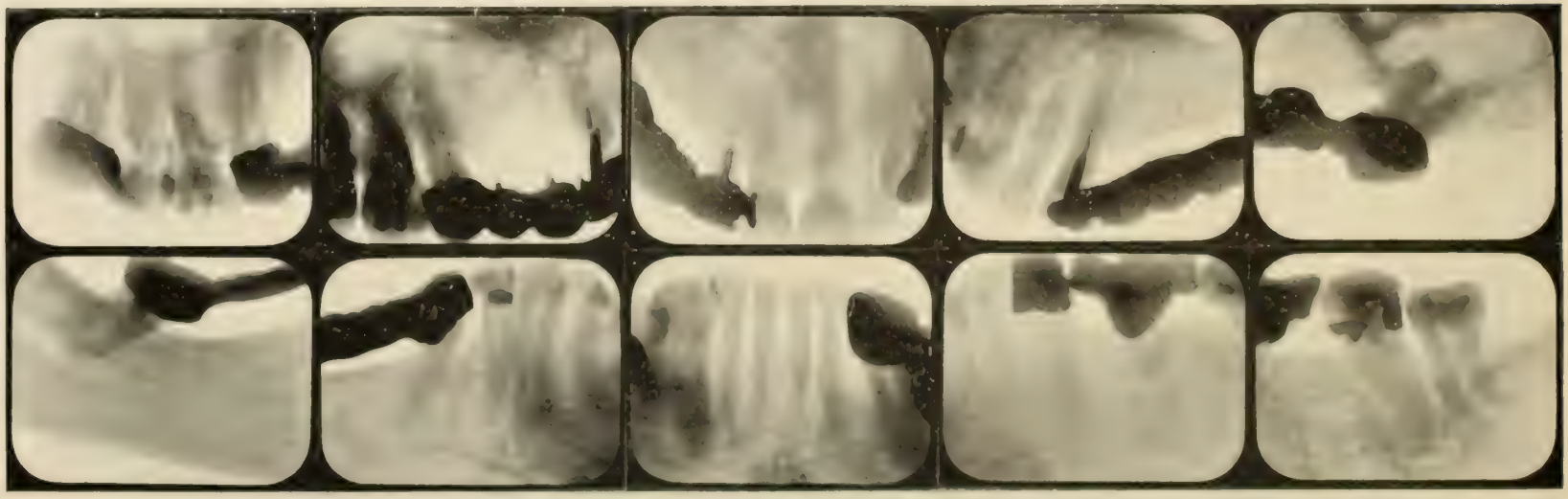

FIGURE 282. ROENTGENOGRAPHIC APPEARANCE OF TEETH OF PATIENT WITH MYOCARDITIS. CASE NO. 1346.

also two brothers. This has been a serious affliction with the patient's mother, and involved her mother, her brother, and sister. There has been left a very marked inherited susceptibility.

Such a case history can only be considered unfavorably and the prognosis not good. If this patient has a locked area of dental infection, it will be almost certain to aggravate his heart condition. Since it is so nearly impossible, if not entirely so, to maintain the sterility of a tooth, no matter how well sterilized and how well root-filled, in the mouth of this type of patient having a lowered defense, we would say with confidence that this patient has no right to have a root-filled tooth in his mouth. His prognosis will always be bad. The removal of dental infection or any other source of focal infection will be very important as removing that much overload. Absorption of toxic substances from the alimentary tract, nasal sinuses, or any other source, would tend to be a serious overload. Streptococci will grow in this man's body with very much greater ease than in the normal, and the proportion of streptococci in the bacterial flora of the mouth will be much greater than in individuals with a high defense for streptococcal infection.

We have stated elsewhere that the seriousness of the patient's lesion together with the factor of safety, as interpreted from the susceptibility chart, will largely determine whether so-called border-line teeth will be left or extracted. If, for example, the patient is entirely well, but is young, and has had no serious overloads, and the history shows that he or she might be expected to have a strongly inherited susceptibility for heart or kidney or some such vital tissue, it is my judgment that such a person should not be permitted to carry a condition which might some day produce the only other element required—namely, a source of streptococcal infection—to make possible a break in the heart tissue when the normal defenses become lowered. Sometimes, however, the break is already beginning if we have the foresight to recognize it. Such a condition is illustrated in the following case.

Case No. 1118.—The patient at forty-five years of age was suffering from fatigue, heart, neuritis, and rheumatism, and for some time had been practically incapacitated for her work. The roentgenographic study of her teeth, as shown in Figure 281, revealed only one non-vital tooth: namely, the upper right bicuspid. This did not have roentgenographic evidence of much local

structural change. We would consider this tooth border-line.

Her susceptibility revealed, as shown in Figure 280, that her chief lesion is heart, that it has been progressively developing, but most important of all that her father and one of his brothers died of heart involvement, and that one of her father's sisters was afflicted with a heart involvement. Her mother's mother died of heart and kidney involvement. Her brother had a heart involvement and her sister died of heart involvement. In other words, she has a strong susceptibility to heart involvement from both sides of the ancestry.

We, accordingly, would expect that with a source of streptococcal infection and an overload, physically or nervously, she would tend to develop a heart lesion. We would not expect that the removal of such a tooth as shown in the upper right bicuspid would produce sufficient physical change in her body to make great change in the condition of her heart. We would, however, expect, and that with confidence growing out of our experience, that this tooth would be infected in its dentin with streptococcal infection. It was extracted and cultured internally and found to be infected with a Gram-positive diplococcus.

An important procedure in this and all such cases is, we believe, the use of such means as may be possible to elevate the patient's attacking power for streptococcal infection, which is chronically low in this type of individual. For this we would recommend, and used in this case, an autogenous vaccine made from the organisms grown from the tooth. Results were very gratifying and her improvement marked, so that she was able to return to her profession of school teaching. I desire this case to be considered as an emphasis of the need for making a susceptibility study, to ascertain the patient's probable inherited factor of safety, together with the patient's own record of such.

As an additional precaution, we recommended that this patient see a throat specialist regarding the tonsils, which he recommended should be removed, on account of her general history rather than the positive tonsillar history. Her health has been excellent for two and one-half years up to the present, and she is again carrying full load, and that very comfortably.

Our later study of these cases reveals that an inherent lowered defense is expressing itself primarily in a decreased bactericidal content of the blood. Their best is never high or adequate for combating an overload. With the reduction of overloads to the

minimum, most important of which for them is a focal streptococcal infection, they may have quite comfortable and efficient lives; and this is the type of patient—namely, one having a low normal bactericidal content of the blood—whom we may greatly assist with a properly dosed and properly prepared vaccine, which was demonstrated in this case.

MYOCARDITIS.

These researches seem to be throwing an important new light on the probable etiology of many cases of myocarditis. Some of the most striking and gratifying improvements that we have ever seen have been in this type of patient. We have always considered heart involvements of all types as being very serious and, indeed, we do still. We do not, however, look with such alarm upon this condition as we did formerly, having seen so many individuals take up again very vigorous life work and carry it without break for many years with both comfort and efficiency.

In the next chapter under Respiratory System we discuss a case in which, with the suspected tuberculosis, there was severe tachycardia with lassitude and dyspnea on exertion, which has been entirely relieved by the removal of his dental infections, the patient having gained in weight from 122 to 176 pounds and has since taken large life insurance policies notwithstanding that he had been refused previously on account of his heart. In five years he has retained practically perfect health, carrying on an active business, and looks like an athlete.

In Chapter 59 on the Application of Preceding Experimental Data in Clinical Practice, I have used as an illustration a patient who at twenty-three years of age was suffering from a very acute heart involvement and rheumatism, the former so severe that she could scarcely walk about. Within a few weeks, she gained from 131 pounds to 146, and for five years has retained her perfect health notwithstanding the fact of a very marked hereditary susceptibility, both her father and mother having died of heart involvement between fifty and sixty years of age, as did others of the ancestry.

It is very difficult in classifying cases, to prevent overlapping because of the frequent, if not general, tendency to complications; that is, several organs or tissues will be involved at the same time in the one patient. The following is such a case.

Case No. 1346.—The patient was forty-nine years of age and had been suffering what threatened to be a complete break in his health for the last three years. His chief distress has been in and

about his heart. Physical examination indicated that the heart was enlarged and the apex rotated nearly to the nipple line. His disturbance had been previously diagnosed as myocarditis. The blood pressure was 180. He had a sensation of extreme tension in his head and symptoms which had been diagnosed as stomach involvement. He had had several thorough physical examinations including his mouth, and it had on each occasion been decided that the teeth were not involved, roentgenograms of which are shown in Figure 282. Our first impression from the roentgenograms was that his teeth were not sufficiently involved to be a serious contributing factor, if judged exclusively from a casual study of the roentgenograms. A more thorough study, however, revealed that the pulps were putrescent in both the second and third upper left molars, and exposed by caries and infected in the upper left first molar, none of which teeth showed apical involvement in the roentgenogram, but which conditions were evident upon careful physical examination of the teeth. The low angle of the upper right cuspid did not reveal clear evidence of apical involvement which, however, the high angle



FIGURE 283. HIGH ANGLE VIEW OF UPPER RIGHT CUSPID SHOWN IN FIGURE 282. NOTE DIFFERENCE IN PERIAPICAL APPEARANCE.

view, shown in Figure 283, clearly reveals.

The ionic calcium of his blood was much below normal. His blood sugar was 108; non-protein-nitrogen 49; urea 12.5; erythrocytes 5,450,000; polymorphonuclear leucocytes 47.5; small lymphocytes 47.5 per cent. His features were drawn and expressive of great nervous strain and tension. A culture was made, anaerobically, from the pulp of the upper left first molar and from the contents of the putrescent pulp of the upper left second

molar and inoculated into two rabbits. One died in about twelve hours with hundreds of small hemorrhages throughout the musculature of the body. These were found in both striated and non-striated muscles. These are shown in the chapter on Elective Localization in Figures 152, 153, and 154. Figure 152 shows four views of this rabbit with its spontaneous hemorrhages in various parts of the body. Figures 153 and 154 show spontaneous tissue hemorrhages in several different rabbits, with the characteristic, that the specific quality which expressed itself as spontaneous hemorrhages, reduced as the culture increased in age. In the rabbit dying in twelve hours, and which received the earliest generations of the culture grown from his teeth, and which had hundreds of hemorrhages in various parts of its body, the heart was large and flabby and showed evidence of dilatation. The heart muscle showed a very remarkable condition. In addition to the macroscopic hemorrhages visible in the heart and corresponding with the macroscopic hemorrhages in other tissues of the body, the heart muscle showed, when sectioned, exceedingly profuse interstitial hemorrhages. These had been so violent as to rupture the connective tissue. This is shown in Figure 284. The upper left molar was planted beneath the skins of several rabbits in succession, the first five of which produced definite lesions, the first with hemorrhagic myositis, with spontaneous hemorrhages; the second, hyperemia of the myocardium, muscle atrophy, and edema of the kidney; the third, acute appendicitis, minute hemorrhages of the wall of the large intestines, and hyperemia of the myocardium, liver, and kidneys; the fourth, hyperemia of the heart and liver, and muscle atrophy; and the fifth, hyperemia of the myocardium and kidneys.

The patient was placed on the following program: A diet rich in calcium, consisting of from three pints to two quarts of buttermilk or sweet milk per day, calcium lactate in tablet form, parathyroid one-tenth grain daily, reduced later to one-twentieth grain daily.

The postoperative condition following the extraction of the three upper left molars was that a secondary hemorrhage set in a few hours after the extraction, which persisted for hours and was very obstinate, requiring the patient to be kept in the ward with nurse's attendance for the night. This is particularly important in connection with the effect of the culture on the inoculated rabbits which developed spontaneous hemorrhages in the muscles.

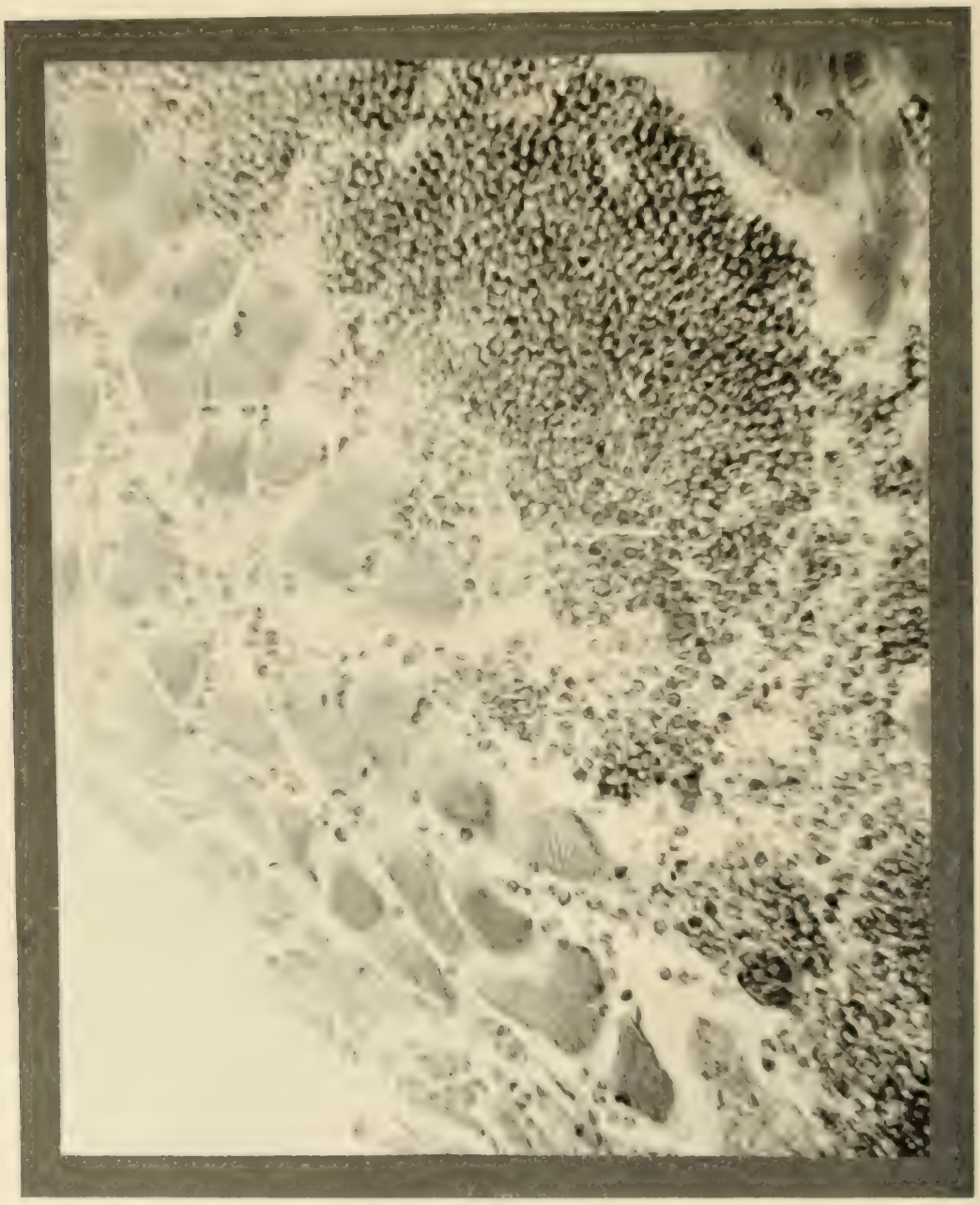

FIGURE 284. SECTION OF HEART WALL OF A RABBIT WHICH DIED IN TWELVE HOURS FROM SPONTANEOUS HEMORRHAGE FROM TOOTH CULTURE OF CASE NO. 1346. SEE ALSO FRONTISPIECE C.

After the extraction of the first three teeth and the treatment that was instituted, no further hemorrhages were experienced. The other extractions followed in a few days. The general result

was that in ten days' time the patient's ionic calcium of the blood was back to normal. His general physical state had improved so greatly that he stated that he had not felt so well for three years. His appetite was excellent and he slept well. The vital index of the polymorphonuclears showed marked improvement. The relation between the ionic calcium and the general condition of the patient was characteristic of this type. When the ionic calcium was low, he had to drive himself with a whip, being in a state of intense lassitude and nervous irritability. He expressed the former condition as one in which the feeling of his head was as though he had been struck over the head with a club, and it was almost continually sore or under sense of severe tension for months. This sensation completely disappeared. He stated that he had not felt as well at any time for three years as he did within ten days after these first extractions and the starting of the special treatment.

A piece of the root of the upper left second molar was placed in some of this patient's blood serum to determine its effect upon the blood calcium. This piece of root furnished enough toxin to combine with approximately one-tenth of the available ionic calcium of this serum in 1 cc. in one-half hour's time, or a total of approximately 30 per cent, when added to the already combined calcium.

Whereas, before the removal of his dental infections and his treatment, he was in such serious condition that he could not carry on business and at times could scarcely carry on a conversation because of the sense of distress produced by having to think, which symptoms were more aggravated for an hour after eating, at which times he would not dare to walk a block because of the distress about his heart, since the removal of the dental infections and treatment, and beginning within a few days and rapidly improving, the heart irritation has entirely disappeared, as also the distress related to eating, and he is entirely free from the nervous disturbances and mental irritability. Within a few days he was walking several blocks, and in a few weeks was carrying on business practically without limitation. He has gained in weight and a feeling of well-being and joy was clearly expressed in all his features in place of the haunted nerve tension that clearly demonstrated that he was just at the point of nervous crisis.



FIGURE 285. SPONTANEOUS HEMORRHAGES IN THIGH OF ONE RABBIT AND PSOAS MUSCLES OF ANOTHER RABBIT. TOOTH CULTURE FROM CASE NO. 1346.

Illustrations of the spontaneous hemorrhages produced by both culture and the implantation of his infected teeth in other muscles than the heart are shown in Figure 285, in which A shows hemorrhages into the hind leg of a rabbit, and B, hemorrhages into the psoas muscles of the back. This case is discussed also in the chapter on Digestive Tract in relation to the type of lesion expressed in the stomach.

For those who are interested directly in the elective localization quality of the organism found in this case, we would state that in ten rabbits inoculated, nine showed spontaneous hemorrhages and the tenth showed hyperemia of the myocardium. This should be thought of in connection with the fact, that the patient not only had the heart involvement, which had been interpreted as a myositis, and which condition was apparently quite perfectly relieved, but also had an exceedingly severe secondary hemorrhage following the removal of his dental infections. This elective localization quality tended definitely and rapidly to diminish with time. Only the first generation of organisms produced the sufficiently severe spontaneous hemorrhages to cause death. In this connection it should also be noted that even the implanted tooth produced spontaneous hemorrhages.



FIGURE 286. SMEAR FROM THE URINE OF CASE NO. 1346, SHOWING MANY PUS CELLS WHICH ENTIRELY DISAPPEARED AFTER THE REMOVAL OF DENTAL INFECTIONS.

The urinalysis before the removal of the dental infections showed both hyaline and granular casts and pus cells in large numbers, arranged largely in shreds as if formed into such in the glomeruli. Figure 286 shows a smear from his urine with polymorphonuclear leucocytes and diplococci. This condition entirely disappeared with the removal of his dental infections.

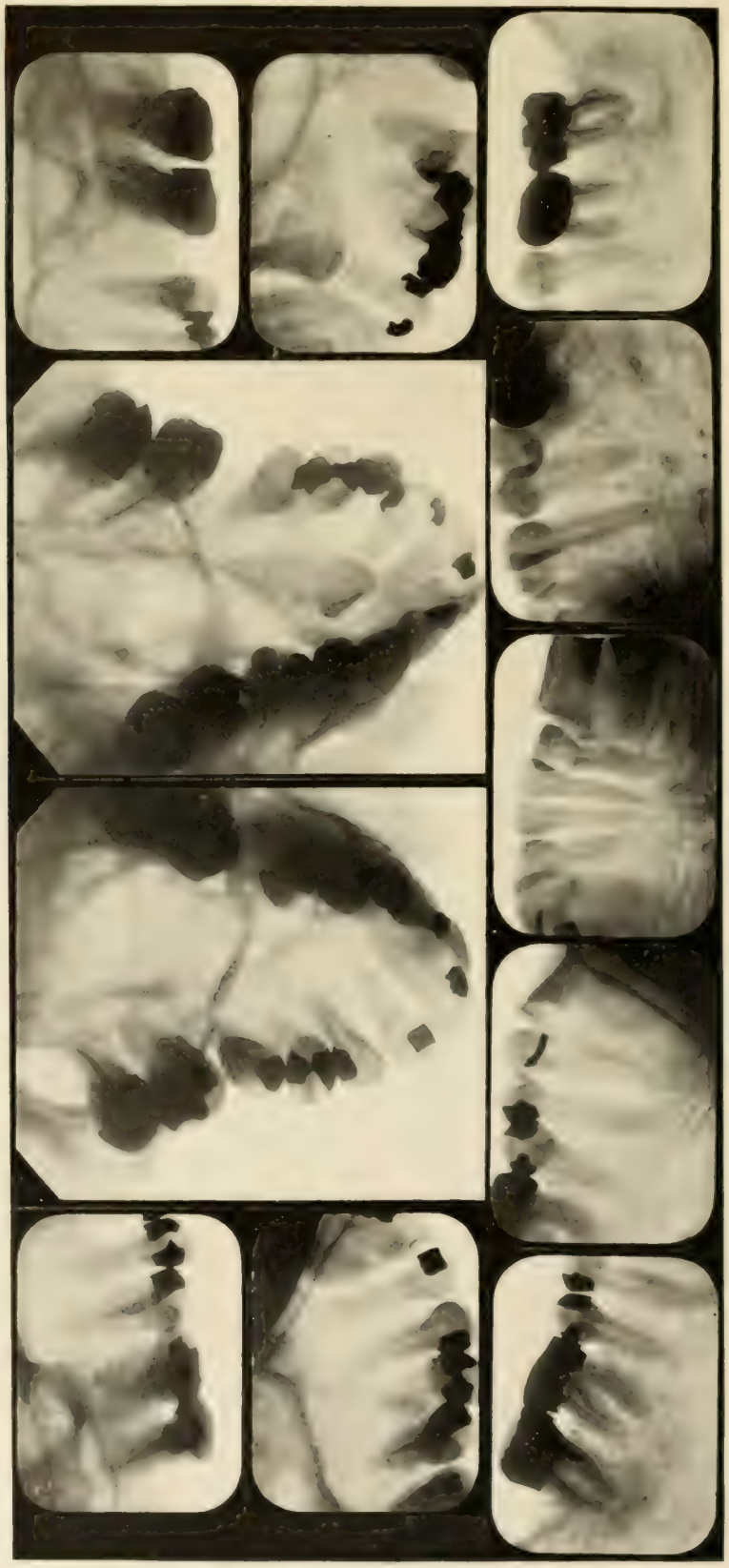

FIGURE 287. ROENTGENOGRAPHIC APPEARANCE OF TEETH OF CASE 1335 WITH HISTORY OF SEVERE HEART INVOLVEMENT.

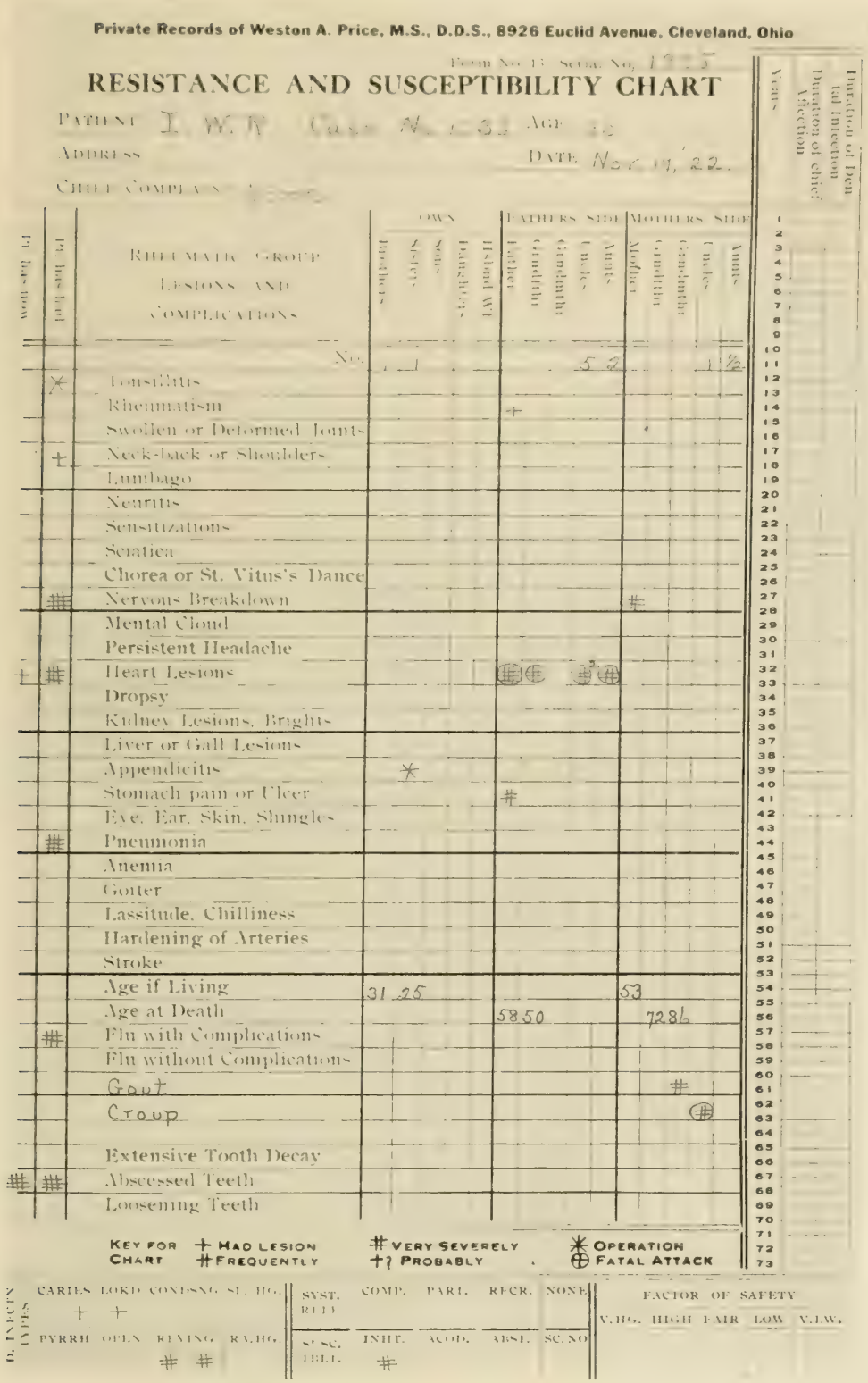

FIGURE 288. RESISTANCE AND SUSCEPTIBILITY RECORD OF FAMILY AND PATIENT OF CASE NO. 1335. NOTE FIVE DEATHS ON FATHER'S SIDE.

Many individuals present for dental operations with every evidence of having excellent health and of high defense, who have as a matter of fact a very serious handicap in the form of a marked susceptibility which cannot safely be ignored. Such a case is the following, whose roentgenograms are shown in Figure 287. (Case No. 1335). She looks well and at the time of presenting says she is well. A study of her case would readily, of course, condemn the lower right second molar. Since her health is reported so good, it would be very natural for some of the other root-filled teeth to be passed without suspicion. This is the type of case where very great harm might be done if the operator either through ignorance, carelessness, or lack of time, neglects to take the history. Notwithstanding that the girl is apparently in splendid health now, her history shows that she was laid up with enlargement of the heart for one and one-half years following the Flu in 1918. Her susceptibility chart is shown in Figure 288. It will be seen at a glance that her father died at fifty-eight of heart involvement, her father's father at fifty with heart involvement, two of her father's brothers and one of the father's sisters all dying of heart involvement; in other words, five members of her father's family, including her father. This shows an inherited susceptibility of so great a strength, that, even though she had never broken, we would be very fearful for fear she would. The fact that she has done so, following the Flu, throws very great responsibility upon the dental infections which she carried at the time of her Flu, for as we have shown in the chapter on Overloads, more than twice as many people were found to have developed complications with the Flu in a group having dental infections as in the group without the dental infections. It is clearly our duty in this case to remove all root-filled teeth. With this evidence of streptococcal susceptibility I would say that the chances are more than 999 out of 1,000 that every root-filled tooth in her head carries streptococcal infection, for in the thousands of teeth that we have cultured, we have practically always found the root-filled teeth, which have been under suspicion, to be infected within the tooth structure.

There was one item in this case which should arouse suspicion, at least to the extent of making inquiry: namely, that this patient was apparently and actually decidedly underweight. In another chapter we have discussed the frequency of underweight in streptococcal susceptibility.

While dictating this part of the text of this chapter, there has

come in the mail a typical communication from a member of the profession of another state, who stands far above the average, and in the best ten per cent, so far as judgment, training, and experience would be expected to place him. His inquiry is so typical of the plight of the profession in general that I would use his case as an illustration. He presents the roentgenograms that had been made for his patient with the recommendation that certain root-filled teeth be extracted, and expresses the wish that, if possible, they may be saved. He desires an expression of my judgment before deciding. Incidentally, he gives this information about the patient. He is suffering from enlargement of the heart and from angina pectoris.

This is just such a communication as I am receiving frequently except that the symptoms of the patient will vary, but similar in the very little detail that is given, such as the age of the patient, how long he has been suffering, etc., etc. In the first place, it is impossible correctly to read the roentgenograms without a physical examination of the patient's mouth, or to make such tests and direct examinations as will disclose non-vital teeth whose pulps have not been removed, etc. The roentgenograms show evidence of apical involvement with condensing osteitis; and, notwithstanding evidence of considerable deficiency in root fillings, there is not a considerable periapical alveolar absorption. The fact that there is not as much as the physical conditions of the roots would suggest might be expected, together with the brief statement regarding the patient's condition, that he has an enlarged heart, (for these latter immediately suggest a low systemic defense for streptococcal infection,) suggests that we should expect in such a case, as we have shown, very little apical alveolar absorption. In other words, this patient would, in all probability, fail to establish an adequate quarantine immediately about the tooth, and because of the absence of this the bacteria and their toxins could pass beyond that quarantine and would have to be dealt with throughout the body, and would tend to attack the most susceptible tissue. His case resolves itself then, since we are dealing with an organ that is vital to health, into a choice between taking the chance of his living a longer time with fewer of his own teeth and dependent upon artificial substitutes, or a probable shorter life without artificial substitutes. If I were a betting man, my research experience would justify me in betting a thousand to one that every

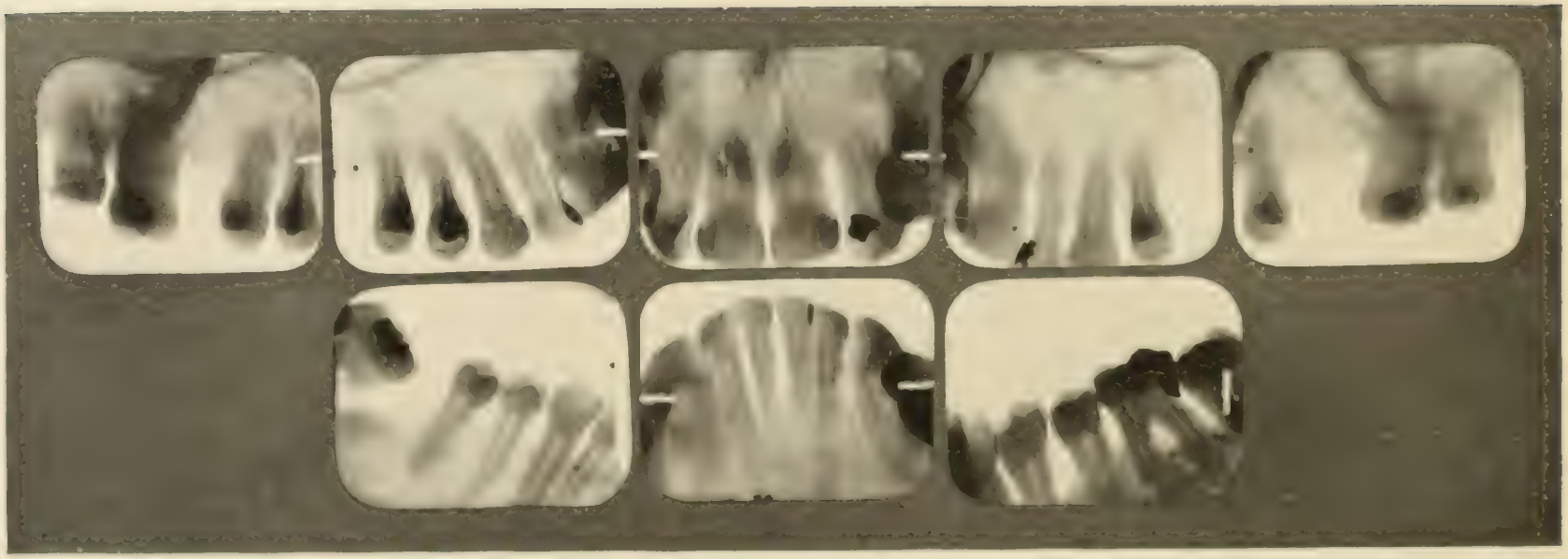

FIGURE 289. ROENTGENOGRAPHIC APPEARANCE OF TEETH OF CASE 1009, A SEVERELY SUFFERING INVALID WITH DEGENERATIVE ARTHRITIS. NOTE DIFFERENCE IN LOCAL STRUCTURAL CHANGE.

one of the root-filled teeth in question in this patient's mouth is infected in the dentin. This would not necessarily be a serious situation for a constitution that was so organized that it could adequately defend itself against the invasion of infections and toxins immediately at the portal of their entry into the system—namely, the vicinity of the root apex—but it is a profoundly serious matter for a man with so much evidence that he is failing in that very defensive process, both as revealed by the condensing osteitis and his carditis. His enlarged heart, in all probability, is the direct result of streptococcal invasions, first as petechial hemorrhages followed by their subsequent fibrosis with, or without direct bacterial infection.

Two things, in particular, must be kept in mind regarding this type of invasion: First, that one streptococcal invasion predisposes to another; and second, that the dominant characteristic of the organisms with which we are involved is their ability to accommodate themselves to the environment and culture medium that any particular patient may tend to furnish, which quality must dominate in the absence of that similar quality, which constitutes the efficient mechanism of defense of the patient whereby the patient as a multicellular organism readjusts itself to every counter move of the bacteria and maintains without a moment's failure the adequate quarantine by a chemical process of combating the organism and its toxin as far as it comes within its reach about the hiding place—namely, the patient's infected tooth—for these chemical substances of defense cannot enter, as we have shown, an infected tooth and stamp out the source of supply. Yellow fever has been almost completely banished from the face of the earth in a very few decades by the stamping out of the source of infection and the carriers, the mosquitoes. Our human bodies can do this with, practically, every other infected structure of the body except the tooth.

In Chapter 21 we have discussed the relation of overload of several closely consecutive pregnancies and illustrated with patients, one of which group is illustrated in the following:

Case No. 1009.—She was brought to us, in a wheel chair, so severely weakened from heart involvement and deformed from arthritis that she could only stand a moment, and that with great difficulty, taking very few steps. Her weight was 78 pounds and her height was about 5 feet 4 inches. At three years of age she had infantile paralysis, but as a girl had nearly normal

strength, had been engaged in business, and when married had good health. The roentgenograms of her teeth are shown in Figure 289. The family history on the father's side was excellent; not so on her mother's side. Her mother and grandmother and two of the mother's sisters, all died of heart involvement. This girl had three miscarriages in two and one-half years, all closely following a full term birth. The result of this overload was to bring on an acute rheumatism and deforming arthritis and heart involvement. We would expect from the type of early reaction around the necks of her teeth that she had normally a high defense, since, as we have shown, a capacity for a good reaction is evidenced by the destruction of alveolar bone and gingival tissues in the presence of irritants. Cultures taken from her teeth were inoculated into five rabbits, every one of which developed carditis, four as endocarditis, and one as myocarditis and aortitis. This patient's weakness was very marked and she was a very great sufferer, frequently not being able to sleep a moment during an entire night, from the pain. She had never been able to regain her strength after the depression of her frequent pregnancies. The use of an autogenous vaccine made from the culture of her infected teeth, together with the removal of the infected teeth, produced so great a change that she was able to go about the city alone in a few months' time and was practically free from pain and has progressively improved to the enjoyment of very comfortable health and few serious physical limitations.

We would interpret her case as follows: She inherited a good defense from her father's side and a susceptibility to heart infection from her mother's side. Under normal conditions she had normal health. In the presence of her unusual overload she became a prey to streptococcal infections (to which she was, by inheritance, susceptible,) from all available sources, important among which were the teeth. She was not able to regain control of this handicap without the removal of the principal source of infection—namely, her teeth—and the boosting of her defenses by means of a vaccine. Her margin of safety is low, at best, and now always will be lower than before, because of the carditis, and infantile muscle atrophy, even though she seems quite well. With a recurrence of overload, which may be Flu, or, as before, she may be expected to break and particularly so, if there be present at the time within her system, a focus of infection to furnish the type of organisms to which she is so sensitive. The knowledge of the inherited susceptibility for heart involvement so

strong from her mother's side places an entirely new and important responsibility upon her dentist, upon herself, and her husband. This is the type of case that will likely break with another pregnancy, unless very great care be taken to keep her calcium reserve as high as possible.

A striking illustration of inherited susceptibility to disturbances in particular tissues or organs of the body will often be found associated with this most important organ of the body, the heart, and, no doubt, constitutes one of the major afflictions of mankind. Previously in this chapter I have discussed as Case 1346, a condition that had been diagnosed as myocarditis which was apparently entirely relieved by the removal of dental infections. Cultures taken from the tooth of that patient produced profuse hemorrhages into the muscular tissue of the heart, when injected into a rabbit, as shown in Figure 284. This individual's daughter (Case No. 1414) presented later with symptoms of nervous break, much lassitude, and a pain about her heart. Two things are very important in this connection: The first is that with the removal of her dental infections her heart disturbance was entirely relieved, as were also her nervous symptoms, and she, like her father, made very important and rapid improvement. The other important thing is that when a culture from her tooth was inoculated into a rabbit, there was a very marked disturbance of the heart, both as endocarditis and myocarditis. Figure 290-A shows a section of the heart muscle with multiple areas of infection, some of which involved zones are large. The heart wall was thickened and there was distinct evidence of fibrosis; and even though the heart lesion was so severe, the heart was still functioning splendidly when the rabbit was chloroformed for posting. B shows a higher magnification of one of these zones, which shows a profuse round cell infiltration and a beginning of degeneration. In some of these zones, however, degeneration had gone on to a process of necrosis and vacuolization, as shown in Figure 291.

It is important in this connection to emphasize again the type of dental pathology that was expressed in this individual. In Chapter 42 of Volume One I have shown for comparison the roentgenographic and blood chemical analysis studies of two patients presenting the same day, one with a high, and the other with a low defense, and I have discussed there some fundamental factors involved. The patient with high defense furnished a

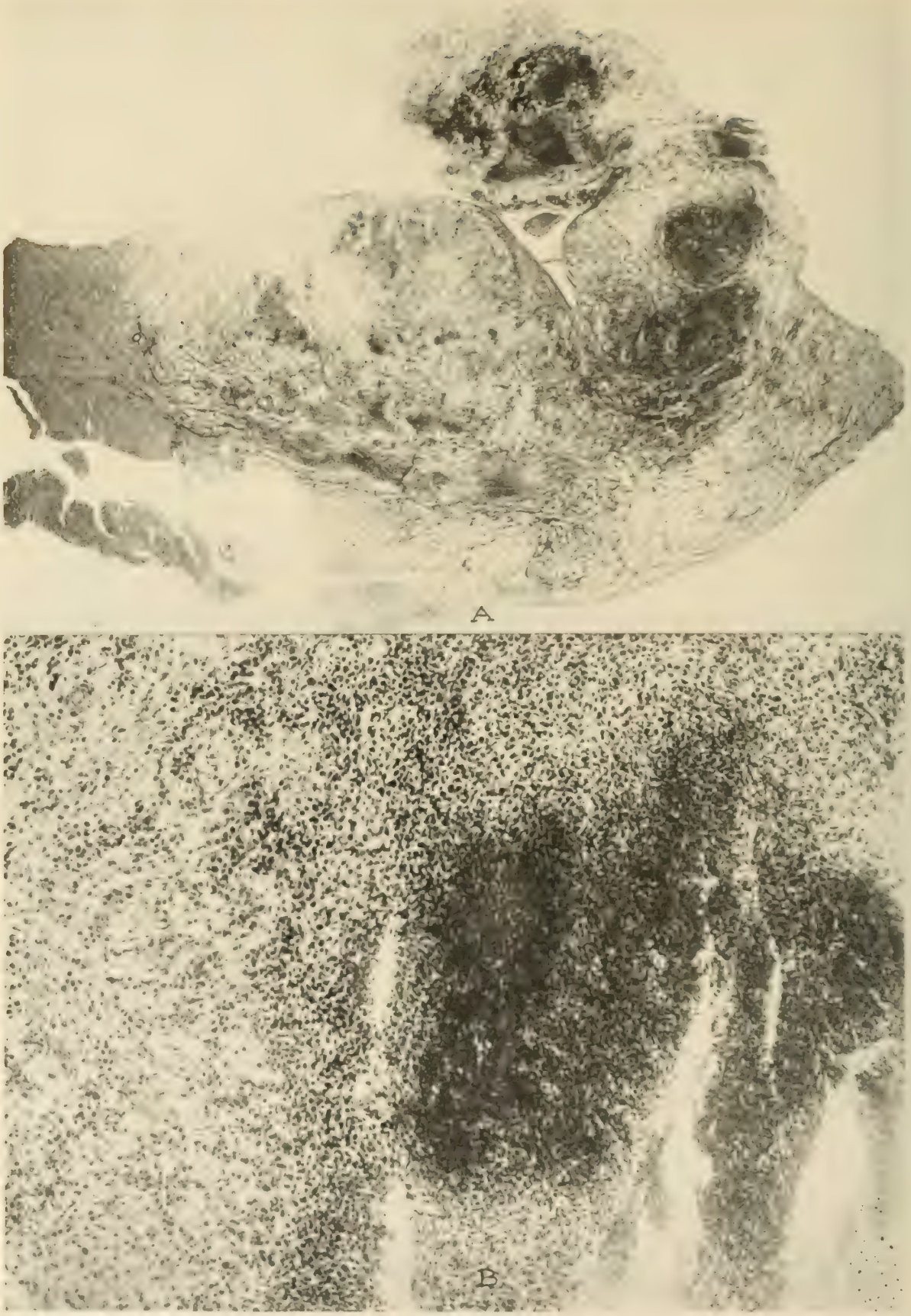

FIGURE 200. A VERY SEVERE MYOCARDITIS PRODUCED IN THE HEART OF A RABBIT INOCULATED WITH CULTURE FROM CASE NO. 1414. A, LOW POWER; B, MEDIUM POWER OF FOCALIZATION.



FIGURE 291. HIGH POWER OF SEVERE MYOCARDITIS PRODUCED IN THE HEART OF A RABBIT INOCULATED WITH CULTURE FROM CASE 1414. SHOWS EXTENSIVE NECROSIS, FIBROSIS, AND VACUOLIZATION, WHICH WAS NOT YET FATAL WHEN CHLOROFORMED.

blood that was very efficient in bactericidal property, besides which it had a capacity, when vaccinated, to have this high efficiency exalted, whereas this patient, Case No. 1414, furnished a blood with exceedingly low bactericidal property and which, when vaccinated *in vitro*, showed no capacity for an increase of that function. I have also shown in that chapter the typical

difference in the roentgenographic expressions of irritations about the teeth; and since there is so much to be learned from a careful study of that great truth, I deem it of sufficient importance to show in this connection the roentgenograms of the teeth of both of these patients, which are presented in Figures 292 and 3. The teeth of this patient are shown in 293, and it will be noted that three pulpless teeth the lower right first molar, the lower left second molar, and the upper right second bicuspid show very little evidence of periapical reaction, notwithstanding there is much occasion for it, particularly in the upper bicuspid and the lower right first molar. In comparison with this, note that the companion picture of the teeth of the individual with the high defense, who has never suffered any of the rheumatic group lesions, shows very extensive gingival and periapical change from irritation.

For those dentists and physicians who are want to make their decisions on the presumption that the extent of the apical involvement, as expressed roentgenographically, is a measure of the danger, I would urge that they refer occasionally to the difference in the bactericidal capacities of the bloods of these two patients, as shown in Figure 248 of Volume One. Since the other volume of this book may not be conveniently near for immediate reference, and because of the great importance of this matter, I am presenting that illustration again here in Figure 294. If that condition obtained in a child of mine, I would not for a million dollars permit those teeth to remain, for from my intensive study of this problem, it is my judgment that the probability of this girl's going through life without further serious injury from these teeth, is not one in ten, granting that she will have the average overload of a normal life. She is a chip off of the old block and has already proven it; and, after all, is that not true of most of us? The difference in the value of the comfort of life without the injuries which these teeth can produce, when compared with the possible discomforts of living and eating with artificial restorations, is so great as to make an effort at comparative values a mockery. We do well to remember that the cracked china cup may last longer than any cup in the cupboard, but only because it is better taken care of. We should also always keep before us the fact that approximately one in ten of all deaths is a life gone out years too soon because of a secondary involvement which has injured the heart.

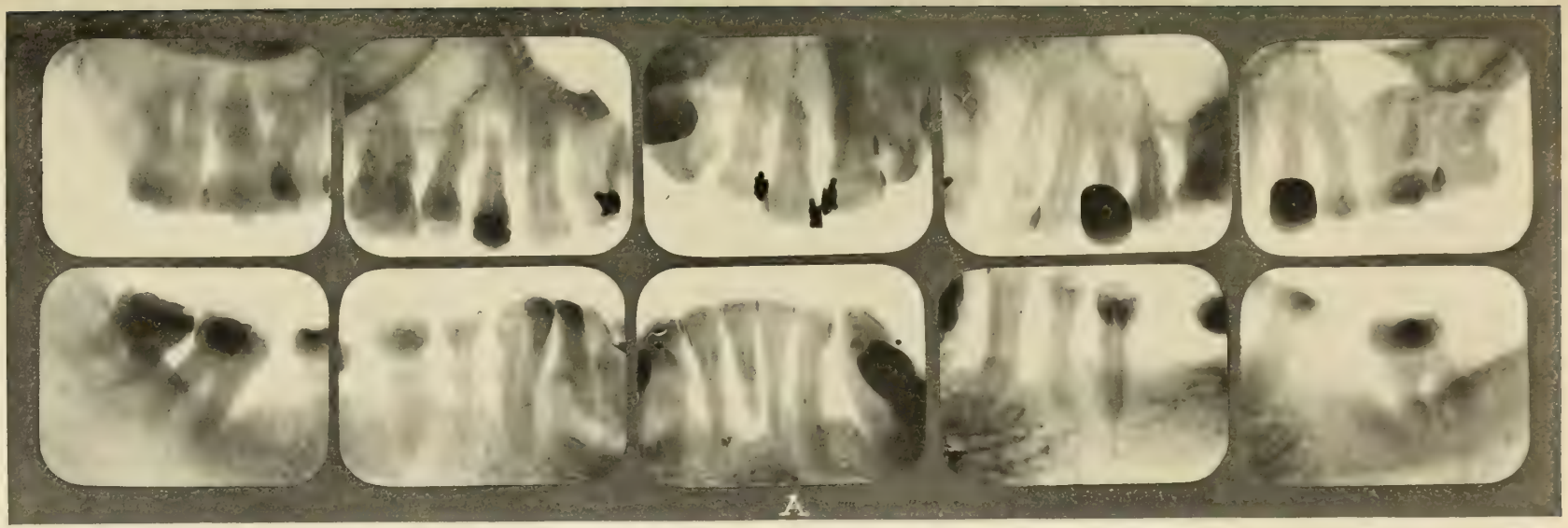

FIGURE 292. DENTAL CONDITIONS OF CASE NO. 1415 WITH HIGH DEFENSE SHOWN IN FIGURE 294.

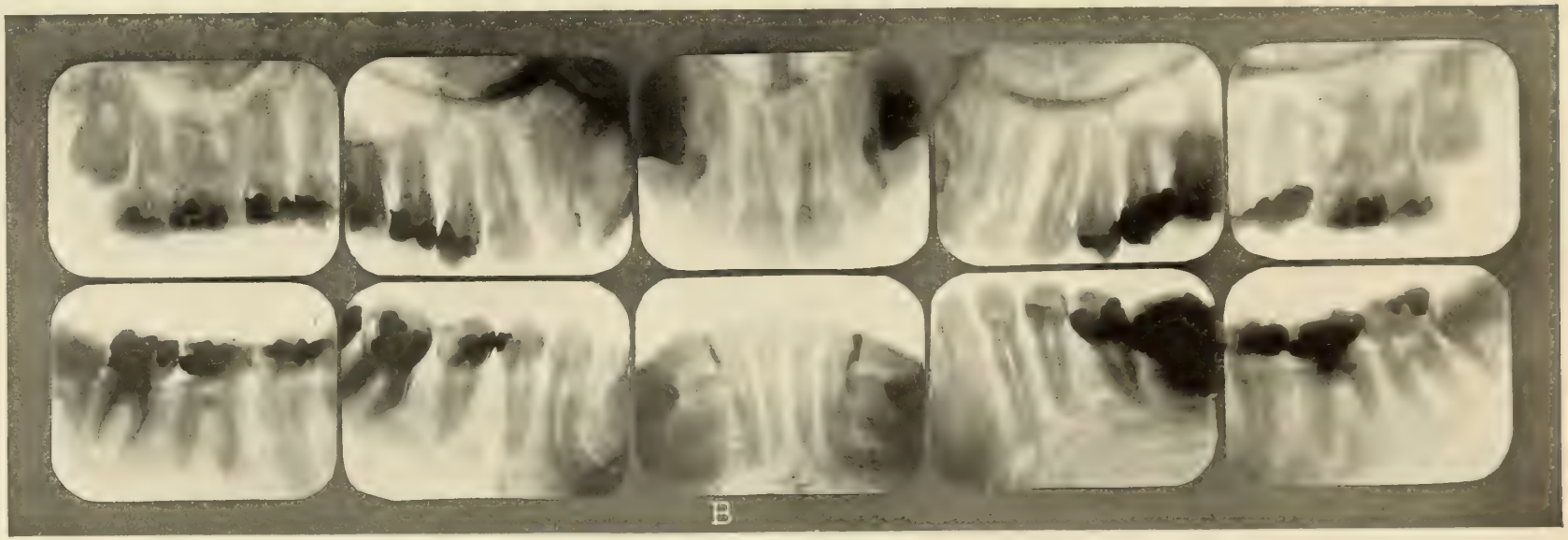

FIGURE 293. DENTAL CONDITIONS OF CASE NO. 1414 WITH LOW DEFENSE SHOWN IN FIGURE 294.



FIGURE 294. COMPARISON OF BACTERICIDAL PROPERTIES OF TWO BLOODS: CASE 1414, VERY LOW; CASE 1415, VERY HIGH. SEE DIFFERENCE IN DENTAL PATHOLOGY IN FIGURES 292 AND 293.

Another phase of myocarditis has to do with those degenerative heart conditions which are the result of long standing irritations. It not infrequently happens that patients who are making a supreme struggle in every tissue of their bodies to carry on, go down with a crash with a disturbance of dental infections in the presence of a heart overload that is already involving the capacity of the powers of adaptation. Probably I hear of more of them than I would in general practice and were I not engaged in research, but it does seem that scarcely a month goes by that I do not hear of a death following dental operations. Unfortunately, the public mind does not know that the individual whose life has gone out, took to the dentist a condition that was almost, if not entirely too late for repair, and the dentist is generally too severely criticized. The time must come, however, when methods will be developed whereby the average practitioner can determine what cases constitute legitimate risks and what do not.

It is not only the patients with acute heart involvement that should have this consideration, for many other individuals have extremely grave conditions from the standpoint of surgical procedure. This is true particularly of those individuals suffering from a marked depletion of their alkali reserve. Even though the organs of their bodies are functioning with relative efficiency, they are entirely incapable of taking care of the additional toxic products which will be provided by the breaking down of tissues as well as by the setting free of both bacteria and toxin from the infection in the area. Many of these patients look fairly well, but their appearance is very deceiving. In the chapter on Osteomyelitis in Skeletal Diseases I have discussed a case which shows in quite considerable detail the relation of defense to alkalinity index of the blood. It is most gratifying that since we have developed the information presented in these two volumes, we have not had a single serious or grave sequence following surgical procedure, and I think entirely because we have a basis for judgment in determining what operation may be considered safe for a given patient before any operations are undertaken.

It has long been known that diabetics constitute exceedingly poor risks for surgical procedures. While this is general knowledge, it probably is not generally understood that probably the most important factor in diabetes, contributing to making these individuals a poor risk, is the greatly depressed alkali reserve; in other words, they are in a chronic state of acidosis. At this point

it is well for me to make an important distinction. I have frequently referred to the fact, that patients with a marked susceptibility to periodontoclasia make a splendid repair after extractions, and I have also stated that diabetics tend to have periodontoclasia, and *vice versa*. It is therefore most natural to make the conclusion that diabetics make a good repair after surgical procedure. The facts are that diabetics constitute a distinct divergence from the general group which would be susceptible to periodontoclasia. This is evidenced in many ways, only one of which is this lack of readiness to healing, another being the lack of response of pyorrhetic conditions to treatment and both for the same reason. This condition, too, is true of all individuals with marked acidosis, or distinctly depressed alkalinity index.

All of this is preface to the presentation of a case which illustrates the need for an adequate examination of the patient before beginning extensive dental procedures. The case is that of a man thirty-four years of age, Case No. 1057, whose chief disturbances were heart, rheumatism, and digestive tract, with extreme nervous irritability. There was a history of attacks of rheumatism at five years of age, twenty-five years of age, and twenty-eight years of age. His heart trouble was first recognized about four years ago; he fatigued in walking a few blocks with much shortage of breath, which began about four or five months prior to examination. He was brought by a physician who greatly desired that we hasten our operations as rapidly as possible. As he had recently been to a sanitarium and had pretty complete studies made, we accepted their reports as a basis. We, however, took the precaution to insist that he stay in the ward for a day for observation before making extractions. The first two attempts to make surgical procedures were abandoned because of the patient's condition. His physician was present and urged that we proceed, since he was going from bad to worse and since he had so much dental infection that probably was an important contributing factor. With extraordinary precautions, one or two teeth at a time were extracted on three occasions. He was kept under careful observation in the ward with our pathologist watching his heart condition which was not the most disturbing symptom. While there was evidence of improvement in some of his conditions, his general condition grew progressively worse, and in twenty-eight days from the time of our first opera-



FIGURE 295. TWO SEVERE HEART LESIONS PRODUCED IN RABBITS INOCULATED WITH CULTURE FROM CASE NO. 1057: A, MYOCARDITIS WITH HYPERTROPHY; B, ENDOCARDITIS.



FIGURE 296. ROENTGENOGRAPHIC APPEARANCE OF DENTAL CONDITIONS OF CASE No. 1057, SUFFERING FROM SEVERE ACIDOSIS, WITH HEART, STOMACH, AND RHEUMATIC INVOLVEMENTS.

tion he deceased with symptoms of extreme acidosis.

I do not know of any procedure which would have made this grave condition a safe one for surgical operation. In the first place, the removal of the dental infections was much too greatly delayed. I feel quite sure, however, that had we at that time been making determinations of the alkalinity index as we do now in all questionable cases, that we would not have undertaken an operation until he was in better condition, which probably could have been obtained by antiacidosis treatment. Cultures were taken from his teeth and were inoculated into rabbits, the hearts of two of which are shown in Figure 295. The one in A shows a very great hypertrophy, and the one in B vegetations on the heart valve. Some of his dental conditions are shown in Figure 296.

In several chapters of Volume One and in this and the preceding chapter of this volume I have stressed the fact that the difference between relative safety and danger from focal dental infection is largely a matter of defensive capacity of the host rather than the attacking power of the bacterium involved. In individuals with a high defense the mechanisms of attack upon the invading organisms are sufficiently active not only to destroy the organisms in the territory adjacent to their source but will tend to destroy them at every point where they are accessible to those defensive forces. I have also demonstrated that the mechanical structure of the tooth with its approximately three miles of closed channels in a single-rooted tooth, constituting the tubuli of the dentin, constitutes a protected zone into which the forces of defense cannot enter. In individuals with an adequately high defense, therefore, there is a solution process established by the host, which slowly but progressively takes down the fortress by absorption of the infected tooth, thereby ultimately making accessible all of the organisms for annihilation. I have also shown in Chapter 42 that part of the protective mechanism is the building of so efficient a barricade between the source of infection and toxin and the host that the products of the warfare may by their mechanical pressure break a channel to an external surface and there escape, and in so doing start an exit for the exfoliation of the infected sequestrum. It is very unfortunate that so many of the members of our profession find themselves in antagonism to the thought that root-filled teeth may be to a greater or less extent an infected sequestrum, without having sufficient experimental data to justify their conviction that the

same is not true, which conviction I fear is largely based upon clinical symptoms, all of which are in their more nearly correct analysis evidences of an adequate defense, which latter makes that tooth relatively safe only so long as that relatively high defense is maintained.

In order to assist in the visualization of what is involved in this process of defense I wish to call attention again to the fact that an important part of the defense against bacteremias from focal infections is the capacity of the host to build a protecting membrane around the infected sequestrum and so to vitalize it with defensive fluids, including the defensive cells of the blood, that for all practical purposes an adequate quarantine is established and maintained. In Figure 297 I show in A such a cystic membrane organized around the broken up chips of an infected tooth, which were sufficiently fine to pass through a medium sized hypodermic needle. The rabbit was later chloroformed and this encysted material removed for sectioning and further study. C shows a cross section, and it will be noted that a dense fibrous capsule has been built around the pieces of infected tooth structure. It is very highly vascularized and there is evidence of a very efficient mechanism of defense, both from the local structural conditions and from the clinical, for the rabbit gained in weight from 1185 to 1539 grams, amounting to 30 per cent in sixty-nine days, at which time it was chloroformed for study. On posting no systemic pathology was found. Locally a cyst had been formed and was removed for study.

PHLEBITIS.

It seems probable that we have not given due consideration to focal infections as playing an important role in the etiology of phlebitis. In so far as I know, it has not been suggested that dental infections are involved in the etiology of these processes. While there are many types of inflammation, certain general conditions are usually present, such as infiltration of the coats of the vein with the formation of a thrombus of coagulated blood. The swelling, stiffness, and edema, frequently produce a great deal of pain, and with these it is very troublesome in its more severe forms in which there is the breaking down of tissue with the development of local necrotic processes. In its simpler forms the chief symptoms are the swelling, edema, and pain. One of our patients (Case No. 1048) had been suffering severely from this disturbance and after her recovery presented for the study of her

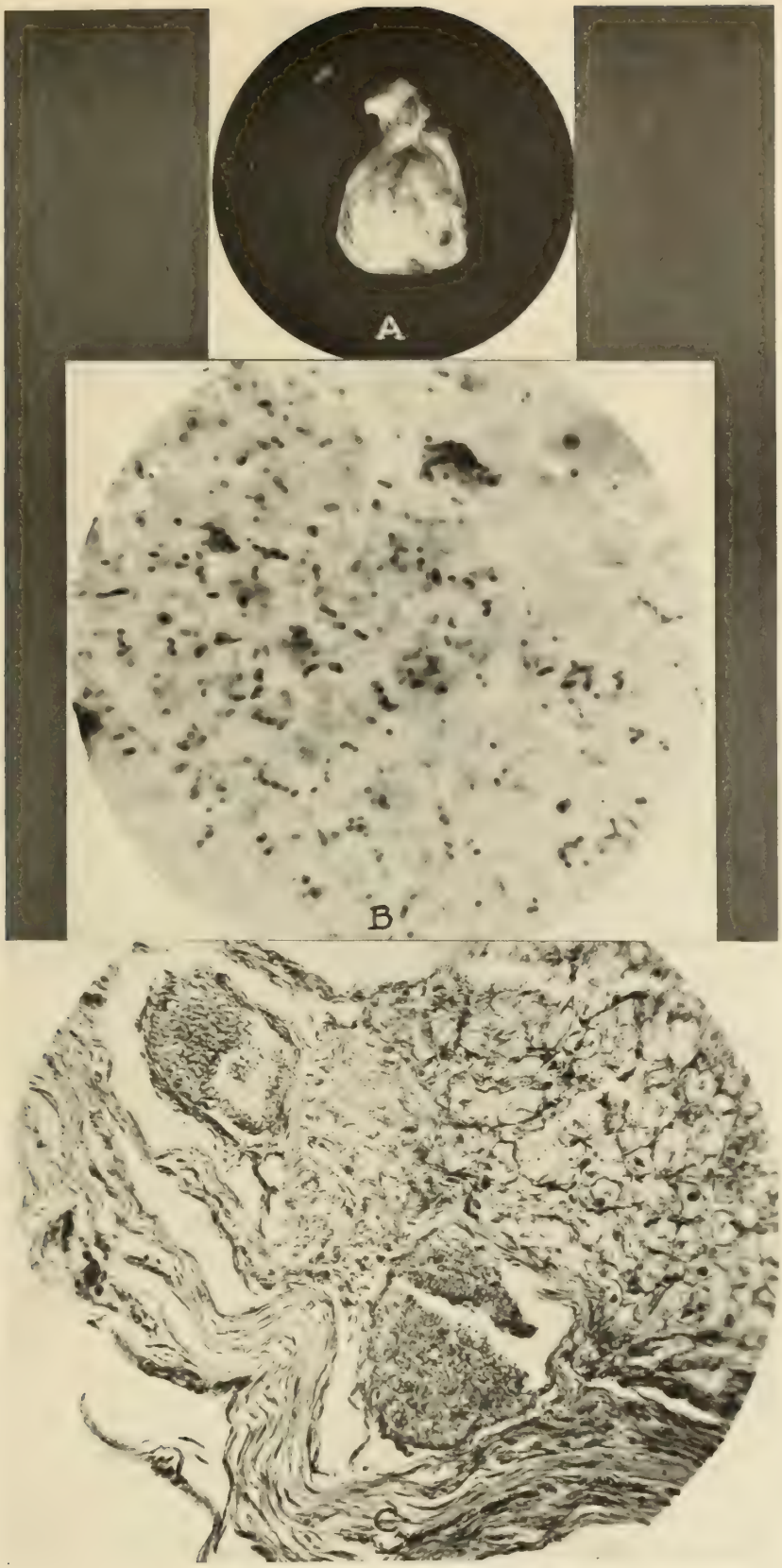

FIGURE 297. DEFENSIVE REACTION: A, ENCAPSULATED TOOTH CHIPS; B, ORGANISMS IN SAME; C, FIBROUS ENCAPSULATION TISSUE, VERY VASCULAR.



FIGURE 298. A SEVERE CASE OF PHLEBITIS, PRODUCED IN A RABBIT'S EAR BY INOCULATION WITH A CULTURE FROM A TOOTH OF A PATIENT WHO HAD RECENTLY SUFFERED FROM A SEVERE ATTACK.

dental infections in connection with her digestive tract disturbance, localizing particularly in the liver and gall-bladder. The cultures taken from her tooth not only showed the acute infective involvement of the gall-bladder, with multiple ulcers as shown, but also localized in the blood vessel walls of the rabbit. In Figure 298 we show this rabbit's ear which is swollen ten to twenty times its normal thickness, very red, edematous, and painful to touch. This, of course, does not prove that this patient's phlebitis was in any way connected with her infected tooth. The fact, however, that this lesion is very rare in our experimental animals leads me to suspect that there was some connection, which would be entirely in keeping with our knowledge to date

regarding elective localization qualities and the conditions under which they express themselves as such.

HIGH BLOOD PRESSURE.

The etiology of hypertension and hypotension is exceedingly difficult to determine. High blood pressure tends to be associated very often with renal disease and tends to develop, in many cases, carditis. It, therefore, is a relatively serious manifestation. I am coming to associate certain types of dental infections very frequently with a type of abnormal blood pressure, which tends to fluctuate in a marked degree. In the case referred to under heart block, that gentleman, seventy-five years of age, had a blood pressure, varying from day to day, from 125 to 175. In other cases the blood pressure tends to remain abnormally high. Such a case is the following, and this also, like the one just referred to, is related to a dental cyst.



FIGURE 299. A DENTAL CYST WHICH PRODUCED A HIGH BLOOD PRESSURE REACHING ABOVE 220, COMPLETELY RELIEVED BY ITS REMOVAL.

Case No. 796.—This woman, aged forty-seven, had a blood pressure in the vicinity of 220, above and below. She had very marked distress in her head, was almost incapacitated, and the symptoms were quite alarming. The prognosis had been given by her medical attendant as very bad. In the roentgenogram shown in Figure 299, there will be seen a bone cyst in the mandible, beginning at the apices of the roots of the first permanent molar and reaching nearly to the lower border, but encased in the structure of the mandible. With the removal of this and the two adjoining teeth and curettement of the cyst chamber, her blood pressure, which had been high for over a year, rapidly descended to 125 and has remained in the vicinity of normal ever since. Her physical condition has returned completely to normal; she has again taken up her duties, and for several years has had no tendency to reinvolvement. It is also of interest to note that a few years prior to the development of her high blood pressure she had

an operation for the removal of an exceedingly large ovarian cyst. In the light of our studies recorded in Chapter 62, it is particularly suggestive that her dental infection may readily have been the origin of this ovarian cyst.

CHAPTER LXI.

RESPIRATORY SYSTEM.

DISCUSSION.

There are two distinct ways in which dental infections very directly contribute to, or become confused with, tubercular and pneumococcal infections of the lungs and respiratory tract: namely, they may be additive to these other infections, or may be confused and mistaken for them. There is need for a great deal of very careful research work in this field, for, it not infrequently happens, that the interference with dental infections of patients suffering from lung involvements, very greatly aggravates that condition rather than relieving or correcting it. We have seen lives go out very rapidly after the breaking up of dental infections where there was involvement of the respiratory tract. Also, as we shall illustrate, we have seen cases of exceedingly marked improvement and apparent complete recovery as a result of the removal of dental infections.

While we may, in a general way, be able to visualize the differences between these groups, the information available does not justify presentation at this time of a set of rules. In a number of instances where patients with a marked susceptibility to streptococcal infections have developed pneumonias, our examination of the sputum has revealed a practically pure culture of streptococci, usually in diploid form; and, indeed, I have come to believe that the pneumonias of this type of patient are either complicated with streptococcal infection, or the result, primarily, of invasion by that organism. Of the tubercular complications and cases interpreted as tubercular, which are not, but are streptococcal, while there is quite a large number in each group, it would be very difficult to prove conclusively the presence or absence, with certainty, of the tubercle bacillus since that organism is so easily overlooked.

One of the symptoms of streptococcal infection which adds very greatly to the confusion with the tubercular infection, is the fact of a recurring afternoon temperature. The streptococcal curve with its weakness and cough would cause many to class

that symptom group with tubercular infection. One of the frequently present differentiating symptoms, although only suggestive, is the fact that tubercular patients do not suffer from mental cloud as a direct effect of the toxin of that organism, which reaction is very likely to be present in patients suffering from streptococcal infection. While the tubercular patient is always going to get well, and hopeful, and confident to the day of death, the streptococcal patient tends, on the contrary, to be discouraged and fearful of an impending doom, which may take any phase from hysteria, or even insanity, to an extreme nervous activity, even expressing itself in an exalted mental efficiency. Indeed, some of the best products of the human brain have been done under the stimulation of this whip.

We would present as an illustration of the role of dental infection in a case of so-called tubercular infection of the two above types, the following: Case No. 345. This patient, aged fifty-one, presented with the following history. He had been sent away from the city to die or get better from tubercular involvement of his lungs. He was running a typical lung temperature, had a persistent and very aggravated cough and rales, and these symptoms were aggravated by a definite heart lesion which expressed itself in tachycardia with skipping a beat. He was advised that he probably would not live over six months when sent to a sanitarium in the eastern mountains. After waiting to die for about two years and with his condition changing but little, he returned to the city and was referred to me by his physician. The dental conditions are revealed by the roentgenograms shown in Figure 300. It will be seen not only that there was a very great quantity of infection in his mouth, but that his reaction had formerly been very considerable to this infection locally, so that there were extensive areas of absorption surrounded by zones of condensation, indicating a break in that defense.

As he presented, his weight was 122 pounds; his height, about 5 feet, 11 inches; a man of large frame but greatly emaciated. His cough was very distressing and his heart enlarged, rapid, and missing beats. When asked how long he had had this heart irritation, he stated for several years. This he knew because he had been refused life insurance on account of his heart.

Our program was quite radical. We removed all of the questionable teeth. The results were so remarkable that they were spectacular. His cough disappeared; his heart irritation disap-

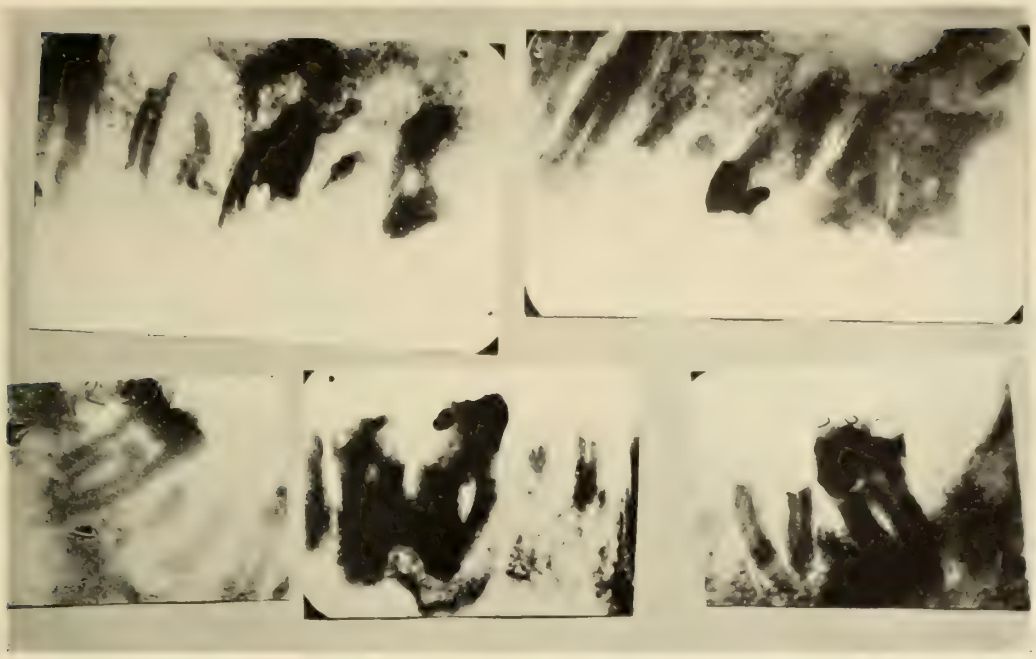

FIGURE 300. DENTAL INFECTIONS WHICH PRODUCED A CONDITION DIAGNOSED AS PULMONARY TUBERCULOSIS. AFTER THEIR REMOVAL THE PATIENT GAINED FIFTY-FOUR POUNDS.

peared; and in a few months' time he had gained from 122 to 176 pounds. He has since taken out three life insurance policies; and it is interesting to note that the insurance companies, knowing of his former record, refused to accept the result of his physical examination on the ground that it was impossible with the history of such a heart lesion as he had had. They wrote to me to find out what I had done to make so great a change in his heart. The fact that he has taken $50,000 of life insurance, and that he has had no recurrence of his trouble in five years, and is carrying on his business, apparently in perfectly normal health, is sufficient evidence that his dental infections were the principal cause of both his lung and cardiac disturbances.

Another case is quite as significant though not so spectacular. Case No. 1153.—This patient at the age of thirty-eight was brought to me by her brother in an invalid carriage a year ago. Knowing of his personal experiences, he desired to know whether this sister, who was in a hospital with acute lung involvement, might not have her condition either aggravated by dental infection or be otherwise involved. She had been confined to her bed in a hospital for months because of daily temperature, bad cough, and raising of sputum, all of which was interpreted as tubercu-

losis of the lungs, and which may have been true. She, however, had occasional symptoms of rheumatism with lameness in the neck and shoulders and hips.

A study of her history reveals that she has had rheumatism frequently during her life. Of seven brothers and four sisters, one brother and two sisters have had acute rheumatism. Her father and his mother had had acute rheumatism. Her mother has been until her death recently a bed- and chair-ridden invalid for about twenty years with deforming arthritis following acute rheumatism. Her mother's father and her brothers and sisters have had acute rheumatism. There was, therefore, a marked susceptibility to streptococcal infection by inheritance. There had also been marked nervous symptoms as neuritis and neuralgia in both a brother and her mother.

Her dental condition is shown in Figure 301. In the light of our experience we would not expect this patient to make an adequate reaction about her dental infections to protect her from the toxins and bacteria furnished by them; and we would also interpret the physical conditions in the involved teeth as furnishing a volume of infected material, such as should in a normal person produce a much greater reaction than is apparent in her case. (See non-vital upper left first biscupid.) We, accordingly, condemned the upper right first molar, second bicuspid, upper left first bicuspid, and first, second, and third molars. The other teeth responded normally to testing.

The result has been most gratifying. She very rapidly gained in weight; her cough and fever disappeared; and for the past six months, she has been, practically, in perfectly normal health. She has gained in weight approximately to her normal, gaining a pound a week for about seventeen weeks.

In different chapters I have discussed streptococcal infections as complications with other disturbances. For example, in a study of overloads, I found that in patients suffering from Influenza, as found in the various city hospitals of Cleveland and Columbus at the time of the 1918 epidemic, the incidence of serious complications such as pneumonia, heart, empyema, was approximately two and one-third times as great in the groups with focal dental infection, as it was in the groups without dental infection, in which cases the complication was, practically, always a streptococcal involvement of the lungs as pneumonia, the pleura as empyema, or the circulatory system with carditis. I also found many cases of acute neuritis with extensive dental infections.



FIGURE 301. ROENTGENOGRAPHIC APPEARANCE OF TEETH OF CASE 1153. NOTE ABSENCE OF PERIAPICAL ABSORPTION.



FIGURE 302. ROENTGENOGRAPHIC APPEARANCE OF THE DENTAL INFECTION PRODUCING A SEVERE NEURITIS. CASE 1120. SECOND MOLAR HAS PUTRESCENT PULP.

These cases all gave a history of no trouble from their dental infections either before the attack of Influenza or since its onset. These individuals clearly became a prey to an infection already focal in their system, but for which under normal conditions they had an ample defense. Similarly, we found in the chapter on Pregnancy as an Overload, that a lower defense from that cause made individuals and animals susceptible to infections which under previous conditions they had carried without apparent involvement.

DENTAL INFECTIONS AND TUBERCULOSIS.

In the preceding paragraphs I have discussed the relation of dental infection to lung involvements simulating pulmonary tuberculosis but which are streptococcal lesions or streptococcal infections superimposed upon tubercular. There is a phase of the relation of dental infection to tuberculosis, which I believe is quite new and which has developed from these researches and is presented here for the first time.

In our studies of the physical and clinical histories of many hundreds of patients and their families, in my effort to establish some fundamental characteristics constituting the presence or absence of susceptibility to streptococcal involvements, I have included many other susceptibilities for comparison, such as susceptibility to typhoid, tuberculosis, influenza, cancer, etc. In Chapter 31 of Volume I, I have discussed some phases of the role of dental infections in precancerous conditions, and in the chapter on Overloads, the relation of dental infections to influenza. I wish here to discuss my studies on some phases of the relation of the presence and absence of susceptibility to streptococcal infection, to the presence and absence of the susceptibility to tubercular infection.

We are all quite familiar with the evidence of an inherited susceptibility to tuberculosis as a unit characteristic and similarly to an inherited susceptibility to streptococcal infections, as endocarditis and rheumatism, etc. In these studies I have been primarily concerned to establish in considerable detail the presence or absence of streptococcal susceptibility and the group characteristics of each class. In Chapter 4, Volume I, I have presented in consolidated form, various data characterizing the inheritance and acquirement of streptococcal susceptibility. I have not included in the figures presented there, other data which was secured at the same time. It early became evident that a predisposition to streptococcal infection did not necessarily con-

stitute a predisposition to tuberculosis, notwithstanding the fact, that dental infections, which are primarily streptococcal, constitute a distinct overload and handicap in the warfare of the patient against tubercular involvements. An analysis of the individuals making up the list of those developing tuberculosis, has revealed the important fact, that when dividing individuals into two groups, those with a distinct susceptibility to periodontoclasia and those without, the former group has much the larger percentage of individuals developing tuberculosis. But I have said elsewhere and frequently in these chapters that individuals with a marked susceptibility to rheumatic group lesions—in other words, streptococcal involvements—do not as a group tend to develop periodontoclasia, and, conversely, those with marked susceptibility to periodontoclasia do not as a group tend readily to develop rheumatic group lesions, and when they do so it is usually an acquired susceptibility. I have also shown that tendency to alveolar absorption relates similarly to a physical state, whether apical or gingival, and hence and accordingly individuals with a high defense for streptococcal infections tend to have the more extensive rarefaction about an apical involvement from a putrescent pulp or infected tooth structure than do those individuals with a distinct streptococcal susceptibility. What I am now saying is that those individuals, who, as a group, tend to have a high defense for streptococcal infections, are as a group more susceptible to tubercular infections. This grouping is not sufficiently clear cut and constant to make it a universal rule.

There are several phases of this relationship which have great importance, and an understanding of them, when it shall be obtained, must assist in an understanding of the tubercular infection and therefore with developing means for combating it. Doubtless all who have had the responsibility of caring for tubercular patients, have seen all too frequently, the temperature rise, perhaps with a bound, following the extraction of an infected tooth and, occasionally, seems to mark the development of progressive decline, terminating fatally. This type of reaction will not infrequently be seen associated with the removal of teeth with marked gingival infections rather than periapical. For the present, let us think of these individuals as carrying a capacity overload, in which state the stirring up of an infected process or the liberation of toxic materials will constitute overloads. We will also think of these individuals as having a lowered capacity

for both defensive reaction and repair. These, however, probably do not constitute the whole or chief contributing factors.

In order further to study these relationships, I have in addition to my contact in my clinical practice, endeavored to study this problem both by going to sanitariums where various types could be seen, and by correspondence. I have made one of these studies at the tubercular sanitarium at the Cleveland City Farm, a municipal enterprise for the care of not only the indigent tubercular patients with well developed or advanced tubercular conditions, but also for those contact cases, who, because of environment and heredity, would be considered susceptible. I wish to take this opportunity to express my appreciation of the splendid coöperation and assistance of Dr. Rockwood, Director of Public Health, and Dr. Horrigan, Dental Surgeon in charge of oral hygiene and oral surgery. I asked Dr. Horrigan what, if any, oral or dental pathological lesions he found to be sufficiently frequently associated with tuberculosis to make it a characteristic lesion, to which he replied in substance, a predisposition to gingival infections and alveolar recessions.

A study of the patients from bed to bed, while revealing a majority with periodontoclasia, disclosed several without this lesion in a marked degree. A more careful examination disclosed, however, that some of these individuals had been very faithful in prophylactic procedure. In a comparative study of periodontoclasia and dental caries in Chapters 7 and 8, it was demonstrated that individuals with a marked susceptibility to periodontoclasia had a less susceptibility to dental caries. It was accordingly of much interest to note that in the individuals herewith studied, the percentage with all of the teeth intact, or only one or two fillings or cavities in the entire denture, was large, which is quite the opposite characteristic of the group with a marked susceptibility to rheumatic group lesions.

If conditions obtain, as these data suggest, (the evidence available is not adequate yet for making extended conclusions) several important questions are suggested, one of which is: What are the constitutional qualities involved in a defense for streptococcal infection and a lessened defense or susceptibility to tubercular infection? I have shown in other chapters that there is a distinct relationship between the degenerative inflammatory reactions, with the taking down of organized bone as in osteomalacia and periodontoclasia on one hand, and proliferative deform-

ing arthritis and calcification processes on the other. This immediately suggests that those individuals in which osteoclastic activities are dominant over osteoblastic activities, there would be a distinct difference in the capacity for calcification of fibrocytic tissues. In other words, if two individuals, one representing each of these two groups, would be considered as having a lung tubercle, the data presented in many of these chapters would suggest, if not justify, the conclusion that the individual with the marked tendency to periodontoclasia and such osteoclastic processes, would in a very much lesser degree calcify the tubercle and fibrocytic capsule than would the individual of the other group with a marked tendency to osteoblastic activity. If this line of reasoning should be based on fact, it should be possible to find data in a chemical analysis of the blood of tubercular patients that would throw light upon this process. In Chapter 20 of Volume I, I have shown in the first chart a series of one hundred successive blood analyses related to both the physical condition of the individuals and the type of dental pathology existing. In that and succeeding chapters, particularly 43 and 44, I have shown a direct relationship between the ionic calcium of the blood and the factors of defense and susceptibility. These have shown that a lowered ionic calcium of the blood tends to accompany a proliferative arthritic reaction and an exalted ionic calcium tends to accompany, if not produce, a degenerative type with osteoclastic tendencies predominating. To illustrate, patients with active periodontoclasia practically always have an exalted ionic calcium of the blood as do patients with osteomalacia. However, individuals with either of these (though the latter can scarcely exist without the former) may develop in a few months' time a quite divergent physical state, in which the gingival pockets would not have been obliterated or conspicuously changed, and therefore lead to gross misinterpretation through not distinguishing between an active and a passive process. I have not been able to find in the literature, data showing in comparison the ionic calcium of the blood of individuals making a successful warfare against the tubercular parasite, with the ionic calcium of the blood of those making an unsuccessful warfare.

Another factor entering directly into this phase of the problem has to do with the acid-base balance of the individual making a defensive reaction. I find in the literature, data calling attention

to the fact, that in the terminal stages of tuberculosis severe degrees of acidosis have been noted. My studies to date do not include a large enough number of determinations to warrant conclusions; they do indicate, however, that these individuals in the early stages of their tuberculosis tend to have an ionic calcium of the blood at and above normal, and an alkalinity index below normal. The following are some typical analyses, and it will be noted that, in general, they correspond with those of advanced stages of periodontoclasia.

Case No. 1427. Blood from vein. 3 P. M.	
Alkalinity index	25.90
Calcium plus thrombin	23.00
Calcium ionic	8.46
Calcium ionic plus combined	11.976
Calcium in combination	3.516
Thrombin content	14.54
Non-protein-nitrogen	41.40
Blood sugar	84.00
Uric acid	2.00

Case No. 1428. Blood from vein. 3 P. M.	
Alkalinity index	24.20
Calcium plus thrombin	25.00
Calcium ionic	9.943
Calcium ionic plus combined	12.162
Calcium in combination	2.219
Thrombin content	16.057
Non-protein-nitrogen	34.00
Blood sugar	78.00
Uric acid	2.05

Note: These are advanced stages of tuberculosis and therefore the ionic calcium has gone down, but the pathologically combined is very high in both, making the total calcium seem high: namely, 11.9 in the first Case 1427 and 12.1 in the second Case 1428. The most striking pathological condition is seen in the alkalinity index, amounting to a severe acidosis, 25.90 in Case 1427 and 24.20 in Case 1428.

By analogy we may be justified in making some observations. Since active periodontoclasia reactions tend to develop an exaggeration of the associating complications, such as acidosis, osteomalacia, and pancreatic insulin insufficiency, all of which

conditions are lessened in severity and often markedly so by the correction of the periodontal infection, it should be expected that the development of periodontoclasia might aggravate tubercular infection by lessening the defense against it, and this is not without support from clinical observation, for we have noted a direct improvement in many cases by the instituting of adequate prophylactic and therapeutic procedures. These should, however, be considered as imperative accompaniments with the protective and preventive procedures of the early stages, rather than means for restoring a defensive mechanism after it is overwhelmed and broken. Maver and Wells [2] have shown that calcifications tend to develop and calcium tends to enter tubercles even in the early stages of necrosis. Their experiments on guinea-pigs indicated "that tuberculous organs regularly show much more calcium than normal lesions."

If, as seems indicated, defense and susceptibility are factors which are closely related to calcium metabolism, whether for the streptococcal group of organisms or the tubercle bacillus, and if it be true that that physical state which tends to the development of periodontoclasia and odontoclastic reactions, predisposes to tuberculosis, we may have here a new approach to the study of the etiology and pathology of tubercular processes, and thereby to new means for combating this malady which is man's greatest single scourge.

In the extensive analyses of case histories in connection with dental and general pathology in Chapter 4 of Volume One I have shown that certain affections tend to group in certain individuals. In the subsequent chapters, especially 20, I have shown evidence of a chemical basis for these groupings, or at least a parallel group of associated serological conditions. If my above suggestion be true that there is an association between lowered defense for tubercular infection and a tendency for osteoclastic activity with decalcification processes, as in periodontoclasia, through calcification and decalcification activities, it should be possible for other associations to be made of tubercular susceptibles. I have shown, for example, that individuals with definite tendency to periodontoclasia do not tend to have the rheumatic group lesions while in that physical state. This has suggested observing the association of rheumatic group lesions with tuberculosis, since tuberculosis tends to be less successfully resisted by individuals with a marked susceptibility to periodontoclasia. I am gathering data on this point which will be presented in further

[2] See Bibliography.

detail later, but it is important that in about two hundred cases now studied in this regard, it has been found that a very large majority of the progressive cases support this interpretation. I have shown that, in general, individuals with an acquired susceptibility, that is a broken defense from overload plus infection, behave very similarly to those with an inherited susceptibility; and hence a history of rheumatism or other rheumatic group lesion would not necessarily contraindicate the above interpretation since individuals may change from their normal type of reaction during such a break. In checking this factor it will be necessary, therefore, to make this observation. The apparent exceptions may prove to be those with a broken streptococcal defense due to overload. *The evidence to date strongly indicates a definite relation between normal osteoblastic activity, or calcium deposition, on the part of those with high defense for tuberculosis, and osteoclastic activity, or calcium depletion or suspension, on the part of those with a low power for fighting a tubercular infection.*

If this be true, we should expect that cases progressing favorably would show more extensive calcifications of lung tubercles than those progressing unfavorably, which, according to many observers, corresponds with the basis roentgenographic observations.

STREPTOCOCCAL PNEUMONIA.

With regard to the streptococcal pneumonias, there are two types in particular of frequent occurrence. One of these is related to influenza in patients carrying streptococcal foci of infection. Since dental infections are practically always streptococcal, this is a matter of great importance. In Chapter 21 on Overloads, I have shown that patients suffering from influenza tend more definitely to develop complications if they have dental infections than if they do not. To review that research briefly, I found by examining patients in five hospitals during two severe Flu epidemics, that the percentage of individuals having serious complications in the group of individuals without dental infection was 32, and in the group with focal dental infections it increased to 72, which is two and one-half times the percentage in the first group. This strongly suggested that dental infections may be carried by the patient without apparent injury while that patient has his normal defensive mechanisms. Influenza

infection, however, destroys the normal defense in a very few hours after its onset, which is shown in the blood morphology and blood chemistry. In this state of broken defense the individual becomes a prey to that infection for which he previously had an adequate protecting mechanism.

In Chapter 41 of Volume One I have shown that the defense of the blood is very largely dependent upon bactericidins which are carried by the leucocytes, and which substances are set free from the leucocytes by the antigen of the invading infection. In the individual with his normal defense the reaction is so efficient that the organisms are destroyed almost immediately that they pass beyond their protection within the infected tooth, and that this battleground of the first line defense about the apex of the tooth constitutes a local quarantine station. Structurally, the tissue is highly vascular and designed particularly to combat and neutralize the toxic substances and destroy the bacteria. The lymphatic circulation carries away a large part of the overflow from the chemical processes of neutralization. If the quantity to be carried away is too great, a fistula forms to the surface and there may be a continuous discharge of the neutralized products. Contrary to the general conception, such a fistula discharges a substance which is harmless compared with the toxins before they are neutralized. It is not uncommon to see these fistulæ close with the onset of disease, such as influenza and other fevers, in which state the products are not being properly neutralized, there is not so much of the overflow of waste product, and instead of the battle being a fight to the finish close by the tooth, these products may then go to other parts of the body. This is approximately what happens in a case of influenza when a patient is carrying a dental infection. That warfare, which formerly was waged with the complete destruction of invading organisms and toxin in the immediate vicinity of the source—namely, the infected tooth—becomes much less active and efficient, with the result that these products pass beyond that first zone. That patient's body has suddenly become like a village without its fire department, all right so long as there was no fire, but in the presence of a conflagration and high wind the hamlet is doomed.

In order to determine the effect of dental infections when superimposed upon influenza infection, I have made studies during two

epidemics by inoculating animals with influenza virus by using the washings from the nasopharynges of patients during the first twelve hours of an attack, and injecting this material into the tracheæ of the rabbits. This produces a typical disturbance, characterized by a change in blood morphology, lassitude, and an acute congestion of the lungs, with some emphysema, which, however, is practically never fatal. Using the method suggested by Olitsky and Gates[3], I have macerated the lung of such a rabbit and inoculated other rabbits. Those workers have shown that an extended series of animals may be inoculated in succession by this method and have the typical influenza lesions produced by this process of animal passage. By taking cultures from infected teeth and inoculating a small amount of a streptococcal strain into the ear vein of a rabbit carrying influenza infection, there is a very marked tendency to the development of terminal streptococcal pneumonia. This is illustrated in Figure 303, in which A shows an influenza lung, which is not fatal to rabbits, and B the lung of a rabbit dying with pneumonia by superimposing a small quantity of dental infection upon the influenza.

It is common knowledge that a very large percentage of the deaths from influenza are streptococcal pneumonias. Since so many individuals carry streptococcal focal infection about the teeth, these individuals are living in the presence of a real danger since they cannot know when their influenza attack may come. It is, therefore, a matter of very great importance in connection with the degenerative diseases, which constitute so large a part of the fatalities of a modern civilization which has rid itself of the infectious fevers, to see to it that focal dental infections are not permitted to develop or remain. If space permitted, it would be of interest to present here, data from the reports from the various army camps at the time of the outbreak of the epidemic of 1918, which not only showed a very high percentage of fatalities being caused by pneumonia, but also that they were streptococcal. We must therefore think of these as being blood-born rather than air-born with the influenza virus.

There is another group of pneumonias which have direct relation to oral infections, and these are the result of the aspiration into the lung of infected material from the mouth. This will involve, particularly, cases of advanced pyorrhetic infection, in which case there is much streptococcal infection with the spiro-

[3] See bibliography



FIGURE 303. STREPTOCOCCAL PNEUMONIA. UPPER VIEW—LUNGS OF RABBIT WITH INFLUENZA, NOT FATAL TO RABBITS. LOWER VIEW—LUNGS OF RABBIT WITH INFLUENZA PLUS INOCULATION WITH SMALL AMOUNT OF DENTAL CULTURE, CAUSING DEATH FROM PNEUMONIA.

chete, which readily infects the emphysematous exudate in those individuals with the lower defense due to influenza or other causes. The very nature of the influenza involvement invites this result. The development of the frothy exudate in the alveoli of the lungs tends to produce violent spasms of coughing, which fail to raise this frothy exudate. A violent expiration compels a violent inspiration, with the result that oral and nasal mucous, with the infections they are carrying, are sucked into the lungs. For this reason influenza patients should have their mouths thoroughly cleansed and as free as possible from infection. Since this process develops suddenly, the only safety lies in the maintenance of a continually clean mouth. This also relates to those individuals who for any reason are given a general anesthetic. It is my personal judgment that many of the complications of pneumonia are nothing more or less than the inspiration into the lungs of infected material from the mouth.

There are the individuals of another group, however, who are very susceptible to streptococcal pneumonia, and these are the individuals suffering from either deforming arthritis or other forms of chronic streptococcal infection. It is probable that in these cases their pneumonias are produced in part by the focal infections throughout their body, particularly in the joints. In several instances where I have cultured the sputum of this type of pneumonia, it has proven to be streptococcal in pure culture. These individuals, besides furnishing probably many foci for streptococcal culture, are generally in a state of low defense for that organism, which susceptibility makes them an easy prey. The evidence suggests, however, that the walled-off infections in passive arthritic joints are not nearly so potential for harm as are focal infections about the teeth. Chapter 40 on the effects on the teeth of arthritic processes, strongly indicates that these individuals tend readily to have the arthritic involvement attack the teeth as it does other joints of the body, and I say other joints, since the tooth has its attachment by a membrane which gives it movement and which mechanism constitutes a joint. I have also shown that they tend readily to have calcifications within dental pulps. This process tends to produce the death of the tooth, in which case its degenerated pulp tissue becomes a pabulum for the blood stream streptococcal infection and a new focus is thereby readily established. In that chapter I show six teeth in succession that have become involved and the pulps

non-vital as a part of the arthritic process, quite independently of caries or ordinary processes of pulp involvement. Such teeth can, therefore, readily become the focus of an active streptococcal invasion, producing in a patient a pneumonia, during such period as the resistance is lowered. These patients from their moribund condition tend to invite respiratory involvements, which condition is probably aggravated by the fact that they tend almost universally to have a subnormal temperature, to be hypersensitive to cold, and tend to have their sleeping rooms too warm for the best efficiency of the respiratory tract.

For several years I have been observing my patients with deforming arthritis and other phases of acute rheumatic group lesions. They have particularly tended to develop pneumonia which, apparently, seldom with them proves fatal. In some instances I have secured cultures of the sputum raised from these patients and have found it to be, practically, pure streptococcal culture. My attention was drawn to this condition by the fact that in our experimental animals some strains of dental cultures, which were always streptococal, though occasionally carrying associated organisms, developed pneumonia which was often terminal, though in many cases it was found at necropsy as a complication, the animals having been chloroformed for examination. In practically every instance these lung involvements, as pneumonias and empyemas, were streptococcal and culturally corresponded to the organism which we had injected of dental origin.

One of the patients above referred to has been bedridden for years and almost every joint of her body seems rigid and deformed. She has had three severe attacks of pneumonia. At the time the sputum was taken for culture, I found her temperature 103, pulse 140, respiration 40; one lung apparently entirely consolidated, the other partially so.

These individuals seem to have evidences of a streptococcal susceptibility in that their rheumatic group lesions are streptococcal, their complications tend to be streptococcal, and, frequently, cultures made from their saliva and detritus from their mouths will grow out pure or nearly pure streptococcal cultures in broth media in contrast to cultures taken similarly from other types of constitutions.

In connection with the pneumonias I have referred to the fact, in the chapter on Tooth Implantations, that we find a marked tendency in our rabbits with teeth implanted to die of pneumonia.



FIGURE 303. A PNEUMONIC LUNG WITH STREPTOCOCCAL PNEUMONIA FROM THE IMPLANTING OF AN INFECTED TOOTH BENEATH THE SKIN, SHOWN ALSO IN POSITION IN THIS FIGURE.

In Figure 304 will be seen the photograph of a posted rabbit, which shows the tooth in position beneath the skin where it has become partially encapsulated. The chest wall has been cut away to expose the lung. The dark area, which is shown leaning over the piece of white paper, is consolidated and gangrenous. This rabbit died in eighteen days after the placing of the tooth under its skin. The most significant feature, however, of these

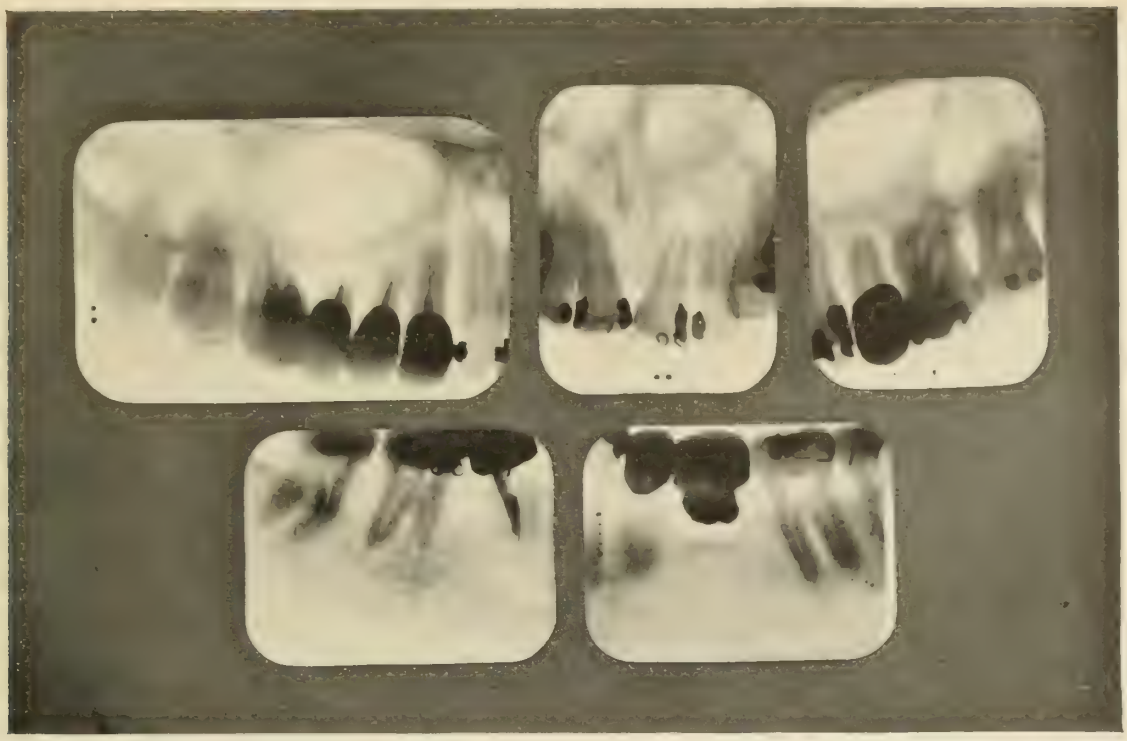

FIGURE 305. ROENTGENOGRAPHIC APPEARANCE OF THE TEETH PRODUCING A SENSITIZATION REACTION AS ACUTE RECURRING COLDS. NOTE EXTENSIVE ABSORPTIONS OF BOTH TEETH AND BONE.

pneumonias is the fact, that, on culture they show a streptococcus in diploid and chain forms, which is characteristic of a type of pneumonia that develops in patients with marked streptococcal susceptibility, such as those with deforming arthritis.

HEAD COLDS.

Under this heading I will discuss a group of disturbances which includes sensitization reactions in the mucous membranes of the air passages and sinus involvements. The characteristics of the former have been discussed in detail in Chapter 30 on Anaphylaxis and Sensitizations. I have found that sensitizations tend to appear in individuals who, normally, have a high defense and with it a considerable quantity of dental infection extending over a long period of time. Their good reacting power takes on the form or modification of a highly developed sensitization in some particular tissues of their bodies. These special tissues are probably most frequently (1) skin reactions, (2) mucous membrane reactions of the air passages, (3) asthmas, and (4) special organs

and tissues. I will discuss only the second and third of these in this connection, because the chief symptom tends to be an involvement of the respiratory system.

In Chapter 30 on Sensitization I have used as an illustration an extreme case which should be referred to at this time. This man had suffered from these acute inflammatory high fever-like disturbances with increasing frequency for several years, apparently regardless of season or geographic location. The removal of his dental infections has entirely relieved for one and a half years these acute symptoms though they had been present once or twice a month prior to that time, and the first disturbance of his dental infection brought on, within a few hours, the most severe attack he had ever had. With the description of this case we have illustrated the use of the sensitization test for identifying this type of case.

Another typical and striking case, though not so spectacular, is the following: The patient about forty years of age had recurring colds, as he explained them, every few months or weeks, winter and summer, and without apparent cause which he could discover. Figure 305 shows his dental infections which were characterized by an exceptionally extensive absorption of the roots of his teeth, a condition which, as we have shown, obtains only in certain types of systemic condition and usually those of very high defense. This man had never suffered from rheumatism, heart, or kidney involvement, or any of the rheumatic group lesions, also characteristic, as I have shown, of individuals with sensitization processes. It will be noted not only that the lower molar roots are absorbed but also the upper molar. I have elsewhere, in Chapter 1, used this case to illustrate the inability of the Roentgen-rays to reveal conditions as they are. With the removal of these dental infections, this patient's tendency to head colds entirely disappeared and for two years has not returned.

ASTHMA.

Asthma is now recognized as being frequently, if not generally, a sensitization reaction to an antigen which varies through a wide variety of proteins or albumins. They may be foods, vegetable products, or bacterial toxins from focal infections. A typical illustration of the latter is as follows:

A patient of good physique and habits suffered from recurring attacks of asthma. On questioning him, I found that these asthmatic attacks had a history of development since the history

of the beginning of his dental infections, that on different occasions he had had prostrating attacks following a sense of soreness and pain about the crowned teeth. He had several bad dental infections. They were particularly bad because there was the quantity of infection of the pulp chambers of very poorly filled roots of teeth that were crowned, and which did not have fistulæ. With the removal of these dental infections his asthmatic attacks entirely disappeared. He had, however, a long history of carditis and finally died of heart involvement.

The types of cases which we have been discussing in this chapter will only be found where the dentist or physician has taken pains to go carefully into the history and intelligently relate the clinical symptoms with the types of dental pathology which are present, and by use of sensitization tests such as we have described in Chapter 30.

There is a phase of involvement of the respiratory tract which is very confusing and obscure and should be stressed because it is of quite frequent occurrence. Patients running a typical afternoon temperature with much loss of weight will, in general, suggest to the internist a possibility of tubercular involvement. This will only need the presence of a typical rale to complete the diagnosis in many instances. We have referred to such a condition with involvement of the heart in this chapter. The rheumatic group lesions do not, in general, tend to be associated, as we have shown, with the type of oral infection such as is present in typical periodontoclasia, pyorrhea alveolaris. It is, however, a very important, and when it is understood will be a significant fact, that tuberculosis tends to develop in individuals who have had a marked predisposition to periodontoclasia. In another chapter we have discussed this relationship. The typical spirochete infections do not tend to develop in root-end abscesses unless that chamber is connected through a liberal opening with the mouth, and particularly an opening beside or between the teeth but following the cemental wall. In mouths with typical periodontoclasia pockets, apical abscesses tend to develop spirochete involvements when related to the mouth as suggested. It sometimes occurs that one tooth may have a very abundant infection and not be accompanied by other involvements in the same mouth. This involvement may be so located that an ordinary examination of the mouth will not disclose such a seriously involved tooth. Such a condition may exist and produce very

serious harm and with symptoms quite different from the typical rheumatic group lesions. Such a case is illustrated in the following:

Case No. 1120.—The patient presented with so serious a bilateral sacro-iliac involvement that she virtually had to be carried. She had not been able to roll over in bed for many weeks, had suffered very severely, and in addition to the neuritis was running a daily temperature with cough and rales. She also had a heart involvement as a murmur diagnosed as mitral disease.

An ordinary examination of her mouth revealed an apparently well kept mouth with excellent teeth and no evidence to suggest that they could possibly be related to her general condition. Had not the physician who sent her been a man of very unusual keenness and thoroughness he would not have suspected the teeth as a possible contributing factor. The roentgenogram of her teeth shown in Figure 302 showed the lower left second molar to have a very deep pocket between it and the third molar, which was displaced backward, and the pulp of the second molar was non-vital and putrescent, the cause for which could not be accounted for except by an extension of a distal suppurative periodontoclasia which extended to and involved the apices of the roots. There were no local symptoms about the tooth to cause the patient to have any suspicion of it. The culture was a most profuse spirochete and streptococcal involvement. With removal of this tooth the daily temperature ceased, the neuritis entirely disappeared and has not returned, which is now about two years. The patient advises that she has never in her life been in better health, does all her housework, and most important, the lung symptoms have entirely disappeared. In this instance but one tooth was involved, and while it was seriously so from the standpoint of its effect, there were no symptoms locally known to the patient and no suggestion from the appearance about the tooth to indicate any involvement. The physician or dentist, who on general principles for lack of efficiency in diagnosis, would condemn several or all of such a patient's teeth because one was involved would do a great injury as would also those who, judging from the appearance of the membranes of the mouth and the appearance of the teeth, supported by the patient's judgment regarding them, would pronounce the mouth free from all responsibility.

CHAPTER LXII.

PRIMARY AND SECONDARY SEX ORGANS.

DISCUSSION.

Neither the literature nor the teachings of the medical and dental professions have associated acute and chronic infections of the primary and secondary sex organs with dental focal infections. While the evidence we will herewith submit strongly suggests such a relationship, it is not clear what these relationships are. In some cases it would seem to be quite strongly suggested that the dental infection either selects or aggravates lesions of the ovaries, tubes, and uterus. In some other cases, as we will cite, it would seem that disease in those tissues has produced some changes in the system which expresses itself as an elective localization quality in the bacteria of the dental focus. Of over a thousand rabbits used in the last two years, localizations in ovaries, tubes, and uterus have occurred a number of times but in only a very few instances where these tissues were not affected in the patient from whom the dental infection was taken, and in two of those instances the cultures were taken from the teeth of male patients who had suffered from gonorrheal or syphilitic infection.

Case No. 1085.—The first case we will cite is that of a young unmarried woman twenty years of age, whose distress at the time of her menstrual periods was so severe that she was required to go to bed for several days, and whose health, both physical and mental, was apparently being seriously injured. Her history showed that some five years previously she was hit over the left ovary when playing golf. This injury was a matter of history without evidence of local injury except for a short period. At this time she had some infected teeth which she carried for the intervening period. Her condition was sufficiently serious so that it became necessary for her either to get relief or give up her university work. In addition to the menstrual disturbance she had an acute nervous disturbance affecting breathing, which began about a year previous to the time of her examination, and numbness followed by severe pain in the back of the neck which



FIGURE 306. ROENTGENOGRAPHIC APPEARANCE OF TEETH, A CULTURE FROM WHICH PRODUCED THE OVARIAN AND TUBAL INFECTIONS IN THE NEXT TWO FIGURES.

was worse before her periods. An acute ovarian pain began three months before our history was made, at which time the numbness ceased.

At the time of our first operation we removed the upper left central and the lower right first molar, which are shown in Figure No. 306, with the result that her ovarian disturbance disappeared. She gained rapidly in weight with a very marked improvement both mentally and physically. Cultures were made from these first extracted teeth and inoculated into rabbits. Six rabbits were inoculated, four females and two males. All of the females developed acute infection in ovaries and tubes. The males remained negative. These are shown in Figures 307 and 308, and all reveal very highly congested ovaries and fallopian tubes. Owing to the fact that her university work in another city made it difficult for her to be absent long enough to have the other upper central incisor removed and replaced, it was not extracted at this time, but instead had the old root filling removed, the tooth sterilized, and the root refilled and an apicoectomy made. Her condition remained greatly improved for a few months when her old conditions returned, at which time we removed the central incisor, made cultures from it, and inoculated three other female rabbits, two of which showed acute infections of the ovaries and tubes.

The result of this operation has been to make so great a change in her health that her mother states that she is like an entirely

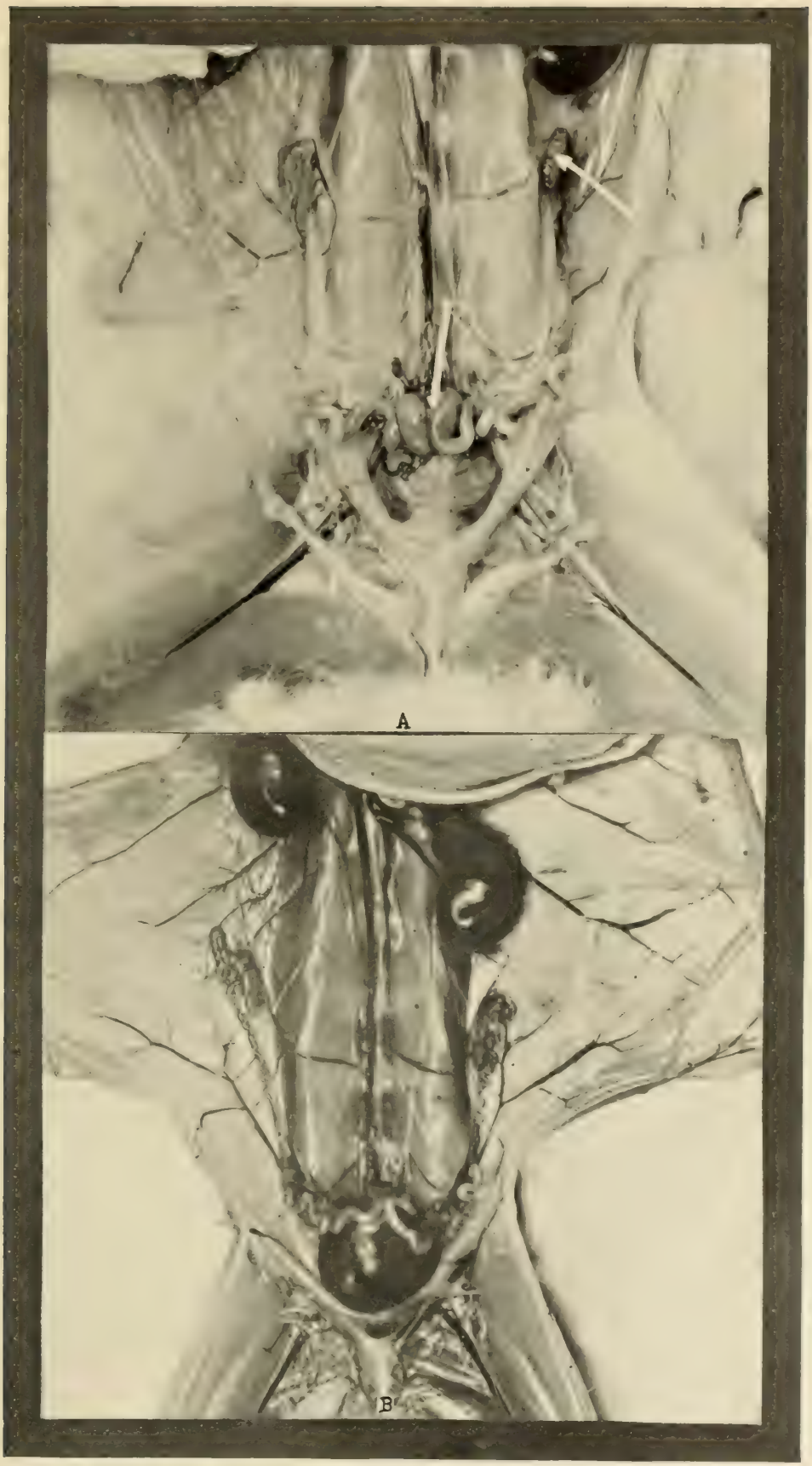

FIGURE 307. ACUTE OVARIAN INFECTIONS PRODUCED IN RABBITS INOCULATED WITH CULTURES FROM TEETH OF PATIENTS SUFFERING FROM SAME.

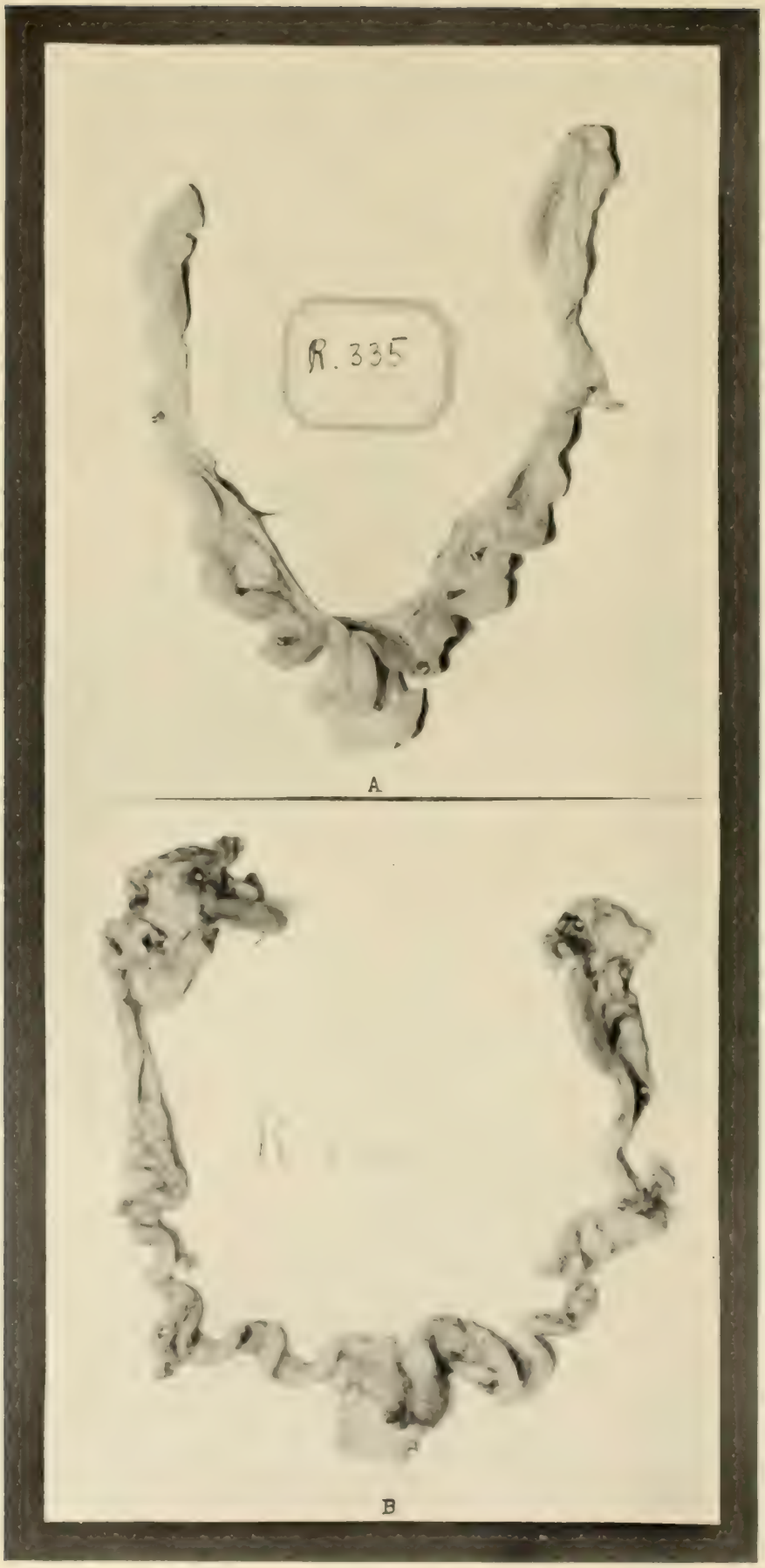

FIGURE 308. OTHER OVARIAN INVOLVEMENTS IN RABBITS FROM SAME CULTURE. CASE NO. 1085.

different person both mentally and physically. Her periods are normal and without pain. She has gained considerably in weight (over twenty pounds) and for approximately two years there has been no tendency to a return of her old trouble. It would seem, in the light of our study, that we have in this case an elective affinity developed in the organisms for ovarian tissue. That the organisms from the dental infection were selecting and irritating her ovaries seems very probable, if not quite certain; and that they are better, if not now quite normal, seems quite certain from the fact, that in every way her health seems perfectly normal. Whether, however, that quality on the part of the organisms was primarily due to the presence in her system of diseased ovarian tissue which, because of its influence on the culture medium—namely, the circulating body fluids—supplied to the organism in the dental culture by the system at large, tended to irritate that tissue, is not clear though it is strongly suggested in other cases.

For example, a woman of about fifty suffered severely from lameness and pain in the back of the neck and shoulders. Cultures taken from her dental infections, inoculated into rabbits, developed ovarian and tubal infection in several. Why this is true is difficult to state, particularly since she had been operated upon twice for ovarian infection, both ovaries being removed. At the time the second ovary was taken, the uterus was removed; and notwithstanding, according to her records, the primary sex organs were completely removed, the organisms showed this elective localization. This would seem to suggest that the normal blood plasma and fluids of the body carry defensive elements for each of the various organs and tissues of the body, the absence of which defensive elements may be an important factor in the development of elective localization qualities in the organisms. This may be a fundamental part of the quality we previously discussed as organ susceptibility, acquired and inherited, particularly the latter. The acute inflammatory process in the preceding case was accompanied by engorgement of the tubes with a serous fluid in which there were few organisms, but the chief characteristic was an acute inflammatory process.

This is quite unlike the process which has developed in some other cases in which the inflammation was limited almost completely to the ovarian tissue with the formation of ovarian cysts. In Figures 309 and 310 are shown several ovarian cysts; one (Figure 310) as large as a small hen's egg; (Figure 309-B) six



FIGURE 304.—SEVERAL OVARIAN CYSTS PRODUCED FROM CULTURE FROM TEETH OF A PATIENT RECENTLY OPERATED FOR OVARIAN CYST, SHOWN IN B, AND CYSTS ON THE VAS DEFERENS FROM SAME CULTURE.



FIGURE 310. A VERY LARGE OVARIAN CYST PRODUCED IN A RABBIT FROM A DENTAL CULTURE.

small cysts on one ovary; and (Figure 309-A) a cyst on the vas deferens. Direct smear and cultures made from the cyst of 310 showed Gram-positive diplococci which corresponded morphologically with those inoculated into the animal from the dental infection. So far as we know, this is the first time ovarian cyst has been produced experimentally by the cultures from den-

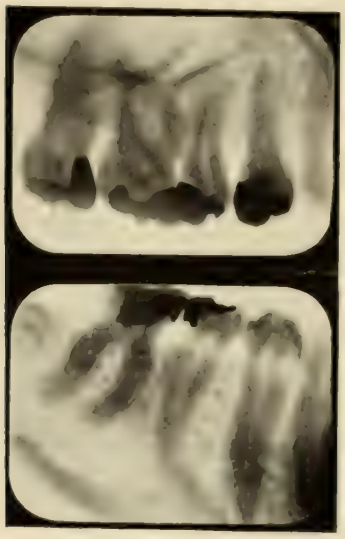

FIGURE 311. ROENTGENOGRAPHIC APPEARANCE OF TEETH OF CASE 1224, THE CULTURE FROM WHICH PRODUCED THE OVARIAN CYST SHOWN IN FIGURE 300. THE PATIENT HAD RECENTLY BEEN OPERATED FOR REMOVAL OF LARGE OVARIAN CYST.

tal infection and, so far as we know, the first suggestion that focal infection may be an etiological factor in its production. This is further strengthened by the following case.

Case No. 1224.—A married woman, age thirty-one, had been operated upon a few months previously for an ovarian cyst, which was about the size of a goose egg, and which had been diagnosed as the cause of sterility. Cultures made from her dental infection, shown in Figure 311, were inoculated into five female rabbits and two developed ovarian cysts, shown in Figure 312. Inasmuch as cysts are not developed rapidly, the fact that these rabbits were posted in from two to four days puts much greater emphasis on the results. The rabbit shown with the very large cyst in the previous figure was posted thirty-one days after inoculation.

It has frequently occurred that the development of infections of unusual tissues of this type in rabbits has been the first suggestion that we have had of such a condition in the patient, and the fact that the patient had suffered or was suffering from ovarian or uterine trouble was only brought out by careful questioning after this elective localization had been expressed by the animal inoculations. The next case illustrates this, as do several others.

Case No. 1050. This patient presented with a history of heart involvement with rheumatism. After the inoculation of rabbits with the culture from her teeth, without thought of sex, the posting of a female rabbit a few days after its inoculation disclosed enormously enlarged tubes with uterine involvement. The patient was questioned and she stated that she had deliberately falsified when the history was made. She had been suffering from

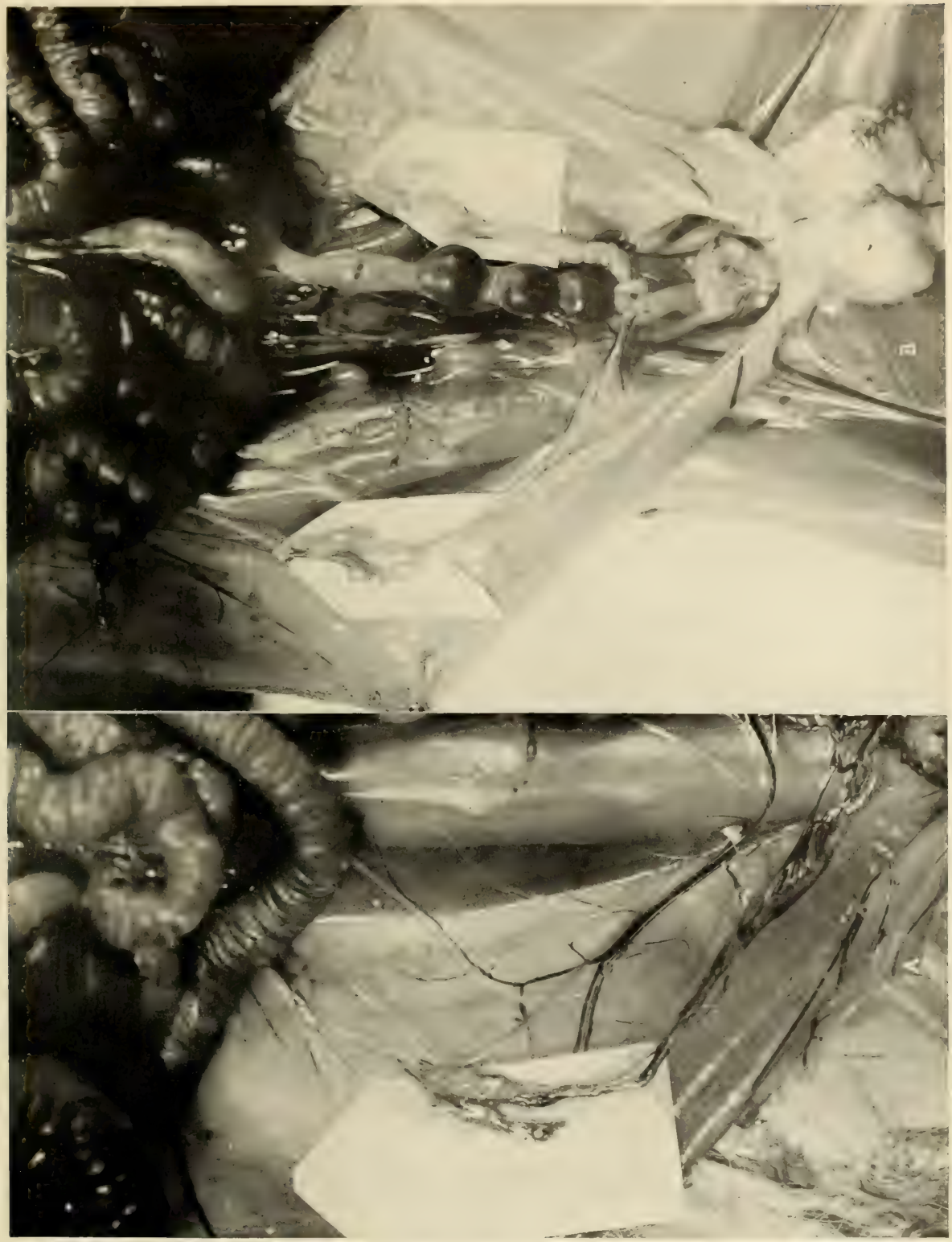

FIGURE 312. THE SECTIONS OF TWO RABBITS SHOWING OVARIAN CYSTS PRODUCED IN FROM TWO TO FOUR DAYS AFTER INOCULATION WITH A CULTURE FROM THE TEETH OF CASE NO. 1224.



FIGURE 313. A VERY PURULENT UTERINE AND TUBAL INFECTION PRODUCED IN A RABBIT FROM THE DENTAL CULTURE FROM A PATIENT SUFFERING FROM A PURULENT UTERINE DISCHARGE WHICH ENTIRELY DISAPPEARED AFTER THE REMOVAL OF HER DENTAL INFECTION.

a purulent uterine discharge for eight months, which her physician had feared was malignant. This infection had been the reason for her physician's sending her to us for dental diagnosis and care. With the removal of her dental infections, this uterine discharge entirely disappeared and has not returned for two years and a half except at one time, for a few days, when one of the sockets from which an overgrown infected root (lower right) became acutely infected with development of a sequestrum, following the extraction. It disappeared promptly with treatment by the removal of the sequestrum. She has gained in weight, gone

back regularly to her work, and her heart is nearly normal. Figure 313 shows the dissection of a rabbit inoculated with the culture from her teeth, which showed very severe infection of the ovaries, tubes, and uterus. When we realize that approximately 550 of the 1100 rabbits have been females, and of that 550 not 2 per cent have developed ovarian infection from a culture which was not taken from the tooth of a woman suffering from ovarian and uterine involvement, and also that in many instances of women suffering from ovarian, tubal, or uterine involvements, percentages running as high as 100 per cent of the female rabbits develop localizations and acute involvements in these tissues, it is very suggestive, if not definitely significant.



FIGURE 314. A DEEP INDURATED ULCER ON THE INNER SURFACE OF THE FALLOPIAN TUBE OF THE RABBIT SHOWN IN FIGURE 313.

In the photograph of this rabbit with uterine, ovarian, and tubal involvement, there will be seen greatly enlarged fallopian tubes. A photograph of the lining membrane of one of these tubes is shown in Figure 314, and there will be distinctly seen an ulcer which nearly perforates. The culture aspirated from the tubes of this case gave a pure culture of streptococcus growing chiefly in diploid form. Frequently, we find, however, that the content of these infected tubes, resulting from the inoculation into the ear vein of dental cultures, proves to be sterile, notwithstanding the extensive involvement of the ovaries and tubes.

In this connection I wish to illustrate what may be a significant condition and which developed in a rabbit. I have referred to the fact, that in exceedingly few instances have we had involvements of the ovaries, tubes, and uteri of rabbits where the patient from whom the dental culture was taken was not a woman suffering from such a condition or with a history of such a condition. In



FIGURE 315. THE HIGHLY INFLAMED FALLOPIAN TUBES, OVARIES, AND UTERUS OF A RABBIT INOCULATED WITH A CULTURE FROM THE TEETH OF A PATIENT WITH SYPHILIS.

Figure 315 will be seen the dissection of a rabbit in which the ovaries, tubes, and uterus are very highly inflamed, and engorged with pus. This rabbit received four small inoculations of the culture from the teeth of a patient with syphilis. We do not know whether there is significance in this association. The fact, however, that while this type of disturbance is so rare, we have had this kind of reaction in cultures taken from the teeth of two different men with a history of syphilitic or gonorrheal infection, is at least suggestive, if not significant.

This elective localization of primary and secondary sex organs is not limited to females. In approximately 550 male rabbits in



FIGURE 316. ACUTELY INFLAMED TESTICLES, ONE FROM EACH OF THREE RABBITS INOCULATED FROM THE CULTURES OF THREE DIFFERENT TEETH OF A PATIENT SUFFERING FROM ACUTE SWELLING AND PAIN IN TESTICLES. HE HAD PREVIOUSLY HAD GONORRHEAL OR SYPHILITIC INFECTION.

the group here reported, infections of the male generative organs have occurred rarely. In Figure 316, three testicles are shown from three different rabbits inoculated with cultures from three different teeth of the same patient. These are more instances than had appeared in any hundred male rabbits previously. Figure 317 shows the teeth from which these cultures were taken. When the patient was questioned, he stated that he had been afflicted with a painful swelling of the testicles during recent months in conjunction with rheumatic involvement. His rheumatism was completely relieved by the removal of the infected teeth and the testicular pain greatly relieved. He acknowledged that there had been gonorrheal or syphilitic infection twenty years previously.

It does not follow that the presence of involvement of the testicles in conjunction with dental infection is related to gonorrheal or syphilitic infection. In several instances where the pain and swelling of the testicles have been a very marked symptom and have been relieved by the removal of dental infections, the evidence has been satisfactorily established that there was no previous infection.

In Chapter 34, on Pregnancy Complications, we have discussed researches that we conducted for the purpose of studying the influence of dental infections, or the infection from that source, on pregnant animals, with reference to illustrations from practical cases. In this chapter, I wish to present some striking illustrations of the effect of overload in reducing the defense. We have stated in Chapter 21 that a very large number of our



FIGURE 317. THE TEETH FROM WHICH THE CULTURES WERE TAKEN PRODUCING RESULTS SHOWN IN FIGURE 316.



FIGURE 318. A HELPLESS CASTING OF MULTIPLE ARTHRITIS. SHE CAN SCARCELY MOVE A JOINT OF HER BODY.

patients suffering from acute and chronic rheumatic involvements have histories which show that this condition dated back to pregnancy or lactation. (It is significant that nearly all bedridden cases are females.) The following is a striking illustration.

Case No. 338—The patient, eight years ago, age thirty-five, was suffering from very severe acute and chronic deforming polyarthritis. When carried to the office, she confided to me that she greatly wished to get better because her husband had told her that if she did not die or get better soon, he would leave her. Her four children had been taken from her and placed in public institutions; and recently, when brought to see her, they were in such a condition that she had a burning new desire to get well to get her family together again. Her utterly helpless bed-fast crippled condition is shown in Figure 318. She was entirely helpless; could be lifted into a chair for a little while, but her suffering was so great that she had to be moved frequently; could not feed herself or do anything to wait upon herself.

With the removal of the dental infections and the use of an autogenous vaccine, she very greatly improved, so much so that she was able again to feed herself, do the family cooking, and her four children were brought back from the institutions in which they had been kept, and her family was reunited. She could even comb her own hair as well as feed herself. While making this progress, the very great misfortune occurred that she became pregnant. She soon became bedridden again, for her system could not furnish the vitality and new tissues, particularly calcium, required for the new life. It was, as is so often the case, the flame to the smouldering fire. Three of her sisters died of complications attending childbirth, probably puerperal fever, which is a streptococcal infection. She has never since regained the use of her joints. The consolidation and ankylosis has gone steadily on until she can only quiver her fingers. The child born from that pregnancy is now seven years old, and she lives on. She has had penumonia three times. On one occasion, I went to her home; at the time, it seemed impossible that any person could be so ill and survive. Cultures made from the sputum showed a pure streptococcal pneumonia. She looks upon her affliction as a divine punishment for her pregnancy. In this connection, when we see, as I do, so many cases of bedridden complications in the form of arthritis, dating back to pregnancy and lactation, it emphasizes the very great need for a campaign of culture and education that will protect women in this most dangerous condition of streptococcal susceptibility.

After this patient's setback and later pneumonia, I had her brought in an invalid carriage to my ward to see if we might relieve her of some of her acute suffering, for she was again in very great distress from acute processes. She was practically as immobile as though lifeless, except that she could move her lips and her fingers. There was practically no movement in her knees, hips, spine, and elbows, and but little in her mandible. During the period of three years following her pregnancy, she had progressively gotten worse, and with this came a necessarily great neglect of the mouth. Some additional teeth had become non-vital. These were removed with the result that the acute inflammation and pain subsided; and she felt that great benefit had been derived although the increase of movement was only sufficient to allow her to move her arms slightly at the shoulders, permitting a swing of about six inches with each arm. Since that time, she has been quite free from pain, though she is compelled to lie rigid in every joint except her mandible and her fingers, about the only movements she can make being with her lips, throat, and voice.

Her history shows that her mother had rheumatism and heart involvement, and that her mother's mother died of acute and chronic arthritis. Her father was an alcoholic. Her first attack of rheumatism came on at twenty-one years of age when she was working in a foundry that was not properly heated, and her work was polishing the iron fixtures for harnesses which were frosty cold. With her rheumatic susceptibility and extreme chilling, together with dental infections which dated back to that period, she developed these serious lesions. I would like the dental readers of this to visualize what their feelings would or should be if they could know that even through ignorant conservatism they had contributed to such an almost endless living death.

Another and striking illustration is the following: The patient, Case No. 1269, brought by the Visiting Nurse Association, has both a central nervous system disturbance and myositic rheumatism which has made her a bedridden invalid for two years, as well as a very severe sufferer. Her history shows that she has had six pregnancies in seven years; and two years ago, she had a miscarriage with a two months' pregnancy and was again pregnant within a month; and her present acute involvement developed during that period, from which she has made almost no progress toward recovery. Since writing the above, this bedridden unfortunate who was making very definite improvement and progress toward a comfortable condition, has again become

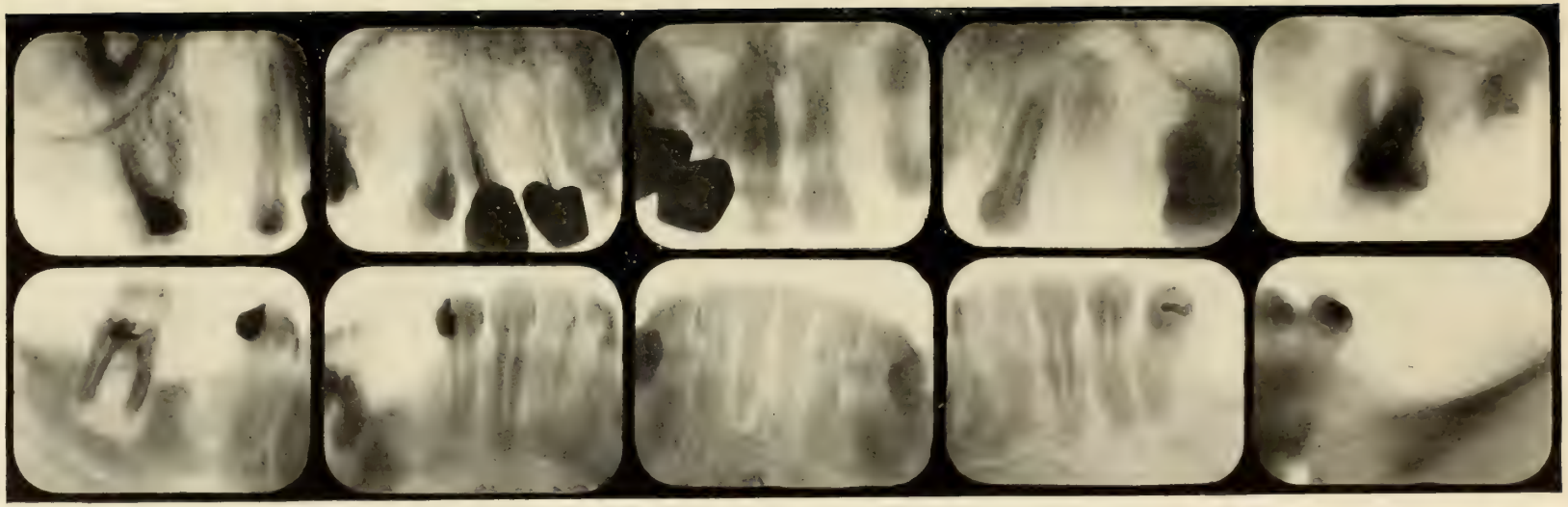

FIGURE 319. ROENTGENOGRAPHIC APPEARANCE OF THE TEETH OF THE PATIENT, CASE NO. 1269. THIS WOMAN IS A HELPLESS BEDRIDDEN CRIPPLE AND SEVERE SUFFERER, PROBABLY LARGELY BROUGHT ON BY THE OVERLOAD OF SIX PREGNANCIES IN SEVEN YEARS TOGETHER WITH DENTAL INFECTIONS.

pregnant, and her condition is very greatly worse than it has ever been before. She can now scarcely move any part of her body and is continually begging that she may die. She may live for years in this almost inconceivably distressing condition. The roentgenograms of her teeth are shown in Figure 319, and it will be noted, as, for example, in the lower molar, that there is evidence of a previously high defense which, however, is surrounded by a condensing osteitis, which change in structure probably relates in time to the overloads and the breaking of her defense.

These cases may be aggravated also by any infective fevers, such as typhoid, diphtheria, etc. The following is a typical illustration. The patient was a helpless invalid with deforming arthritis, as shown in Figure 320. In addition to her severe arthritic involvements, she had bed sores as large as half an orange. Her history showed that she had been in good health until a pregnancy which occurred at about forty-two years of age, with which she developed her acute rheumatism and preceding which, she had had considerable acute tooth-ache that received no attention. The condition of her mouth was one of apical infections. We removed her to a hospital where she could get better care and where it would be possible for me to carry out the proper program. With the removal of her dental infections and the use of a vaccine and her better care, she improved so greatly that she was able to get up in her wheel-chair, roll herself about, feed herself, and was practically without pain. She returned to her home with a vision of enjoying again the happiness of her five-year-old little girl and of being able to cook once more for her husband. Shortly after her return, this little girl came down with diphtheria which her mother contracted, with the result that her acute rheumatism was again lighted up and she became almost as rigid as previously. Could she have been properly protected and properly cared for, we believe she might have made much further improvement which was progressively occurring up to the time of her contracting diphtheria.

These researches show clearly that when society becomes more intelligent, motherhood will get a very different protection. I have recently been informed by a patient, when getting her family history, that her mother, who had lived in Europe, died at thirty-four after having given birth to eleven children besides which she had two miscarriages. Several of the children of this woman died in childhood from symptoms which indicate rickets.



FIGURE 320. A HELPLESS BEDRIDDEN ARTHRITIC CRIPPLE, WITH BED SORES AS LARGE AS HALF AN ORANGE. HER CONDITION STARTED DURING PREGNANCY LATE IN LIFE WHEN SHE HAD CHRONIC DENTAL INFECTIONS.

We do not know what all is involved in the maternal overload of gestation. In the chapter on Overloads I have reported the result of our researches on the deficiencies of gestation as indicated by blood analysis. It is very significant that the ionic calcium of the blood is often lowered in this condition, as it is also in the saliva; and the tendency to dental caries has been shown, in the chapter on Caries, to be related directly to this state.

Dental and medical care of expectant mothers must finally include an intelligent estimation of the calcium starvation as well as other elements, particularly phosphorus, and it must become a part of intelligent living that this condition shall not be allowed to occur, where the system has not an ample factor of safety, and is free from sources of focal infection against which the body may have ample defense during normal stress, but an inadequate defense during this overload. This is particularly illustrated by the effect on rabbits of inoculations with culture producing serious streptococcal lesions, from which the rabbits apparently, completely recovered after several months' time. But while their recovery was adequate to let them return to apparently normal health under ordinary stress of life, they were not able to hold this walled-off infection in check after the overload of pregnancy was established. I will, accordingly, refer for detailed descriptions of this to Chapter 21 on Overloads, Figures 140 and 141.

CHAPTER LXIII.

KIDNEYS AND RELATED EXCRETORY ORGANS.

DISCUSSION

KIDNEY.

Whereas, formerly, we looked upon kidney lesions as being remotely related to dental infections, we have come to recognize a very great responsibility in leaving dental focal infections in the mouths of patients having either an acute or chronic nephritis, or marked susceptibility by heredity for same. We have frequently found in patients, in the thirties and forties, that he or she was already developing nephritic changes without its having been suspected, either by the patient or the family physician, and was only looked for by us, because of finding in the susceptibility study, that it might be expected, that there might be an hereditary susceptibility, together with the fact that the patient was found to have definite dental focal infections. This would be illustrated by the following:

Case No. 692—The patient, female, unmarried, age thirty-five, had generally been in good health during her lifetime with the exception of rheumatism, from which she had been free for several years. The susceptibility study, as shown in Figure 321, revealed the fact that her father had died of Bright's disease, that the father's father and mother had each had Bright's disease, that one brother had died of Bright's disease, and one sister had died of heart trouble. The urinalysis made for the patient revealed albumin and a great abundance of casts, shown in Figure 322. Some teeth had been considered border-line until this information was secured; but, on ascertaining this serious condition, they were condemned. Three of her teeth, which are shown in Figure 322-I, were extracted and implanted beneath the skins of three different rabbits, roentgenograms of which are shown in two positions in A and B. C shows casts in the urine of a rabbit inoculated in this way. D shows the organism recovered from the blood stream when posted. F and G show the histological appearance of the kidney, revealing acute parenchym-

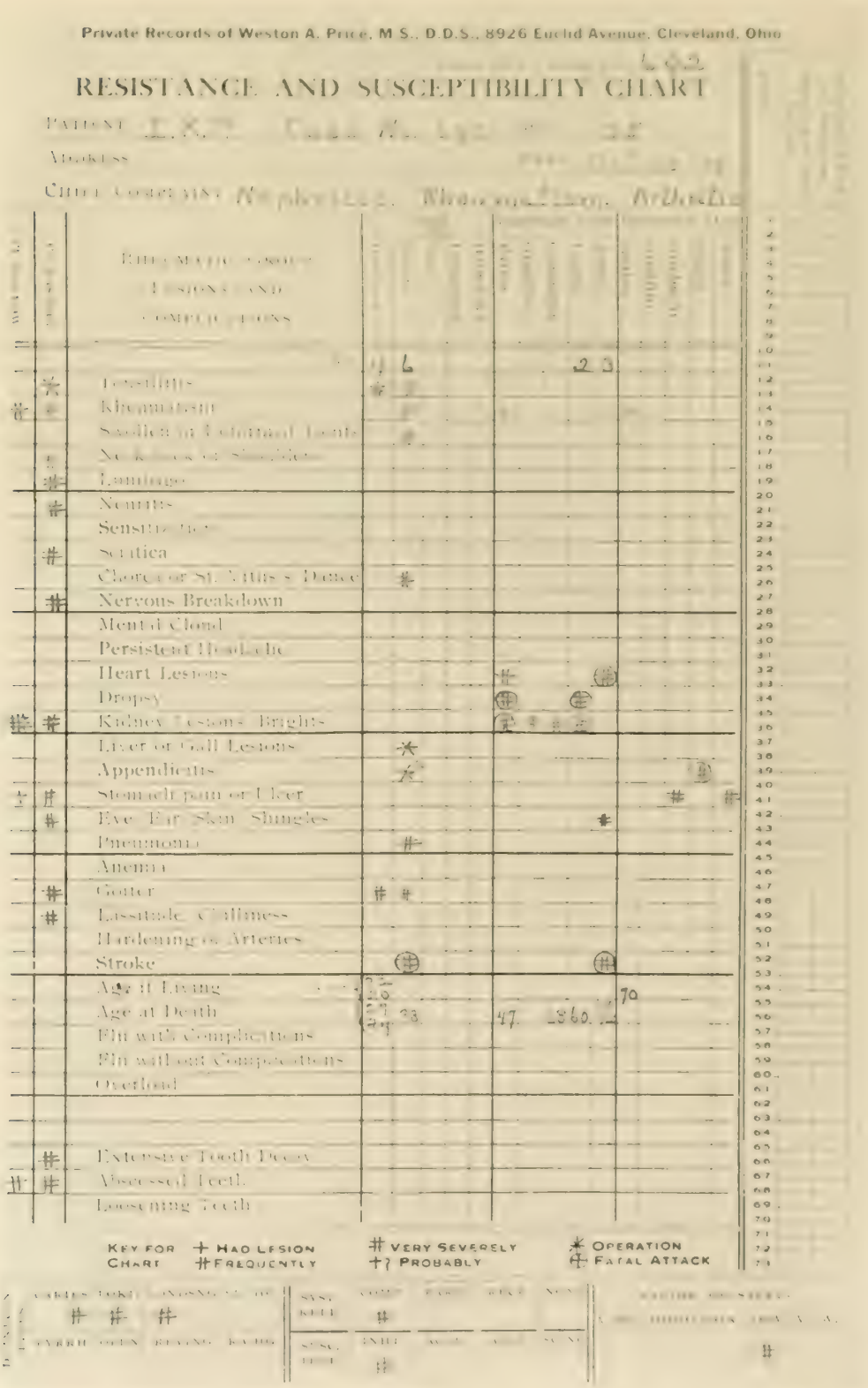

FIGURE 321. SUSCEPTIBILITY STUDY SHOWING MARKED SUSCEPTIBILITY TO KIDNEY INVOLVEMENT INCLUDING PATIENT AND FOUR MEMBERS OF FATHER'S FAMILY. CASE NO. 692.

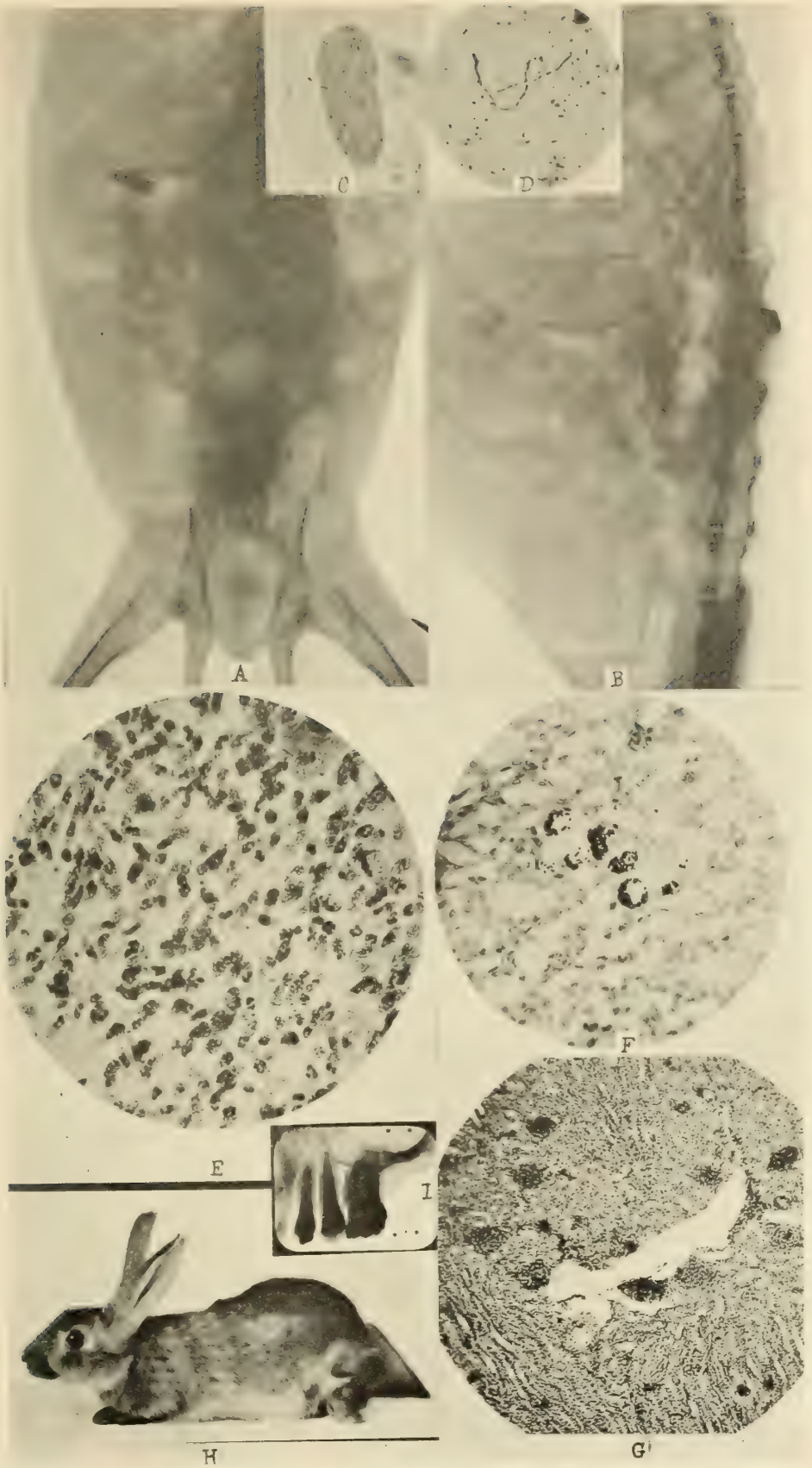

FIGURE 322. RABBIT REACTIONS TO TOOTH IMPLANTATIONS OF CASE IN PREVIOUS FIGURE. A AND B, IMPLANTED TEETH. C, CAST IN THE RABBIT'S URINE. D, ORGANISMS IN THE RABBIT'S BLOOD. E, CASTS IN THE PATIENT'S URINE. F AND G, NEPHRITIC KIDNEY SECTIONS.

atous nephritis. All three rabbits, so treated, developed acute nephritis. H shows the involved rabbit. It is interesting to note that, after these teeth had been in rabbits' tissues for a period of time, they lost their ability to produce nephritis, and, at this time, three months after their extraction, these teeth are being carried in rabbits without apparent effect upon them.

It sometimes occurs that, when teeth are implanted, they produce quite violent reactions with abundant development of pus, and at other times there is exceedingly little reaction about the tooth. It does not follow, however, that the former condition is necessary in order that serious lesions may develop in animals. In the following case (No. 861) the patient, male, age sixty-eight, had both sugar and albumin with casts and renal cells in the urine. A tooth that had been considered border-line, shown in Figure 323,



FIGURE 323. TOOTH FROM PATIENT WITH NEPHRITIS. SEE NEXT FIGURE.

was accordingly condemned, and when extracted was planted beneath the skin of a rabbit which was posted in two weeks' time. Figure 324 shows the appearance of the tissue about the tooth when the rabbit was posted. As will be seen, there was exceedingly little local irritation about the tooth; but, notwithstanding this fact, the rabbit was losing in weight, and developed an acute nephritis, as shown by the kidney section in Figure 325. Some of the borings of the interior of this tooth, which was apparently well root-filled, were inoculated into another rabbit after being ground finely enough for them to pass through a hypodermic needle. The normal salt suspension of these tooth chips was injected beneath the skin of the rabbit. It also developed acute nephritis.

From these last two cases it will be noted that the quantity of infection that was inserted in the rabbit was exceedingly small, not a grown mass of culture inoculated into the circulation, and the organisms in the tooth placed beneath the skin, or small

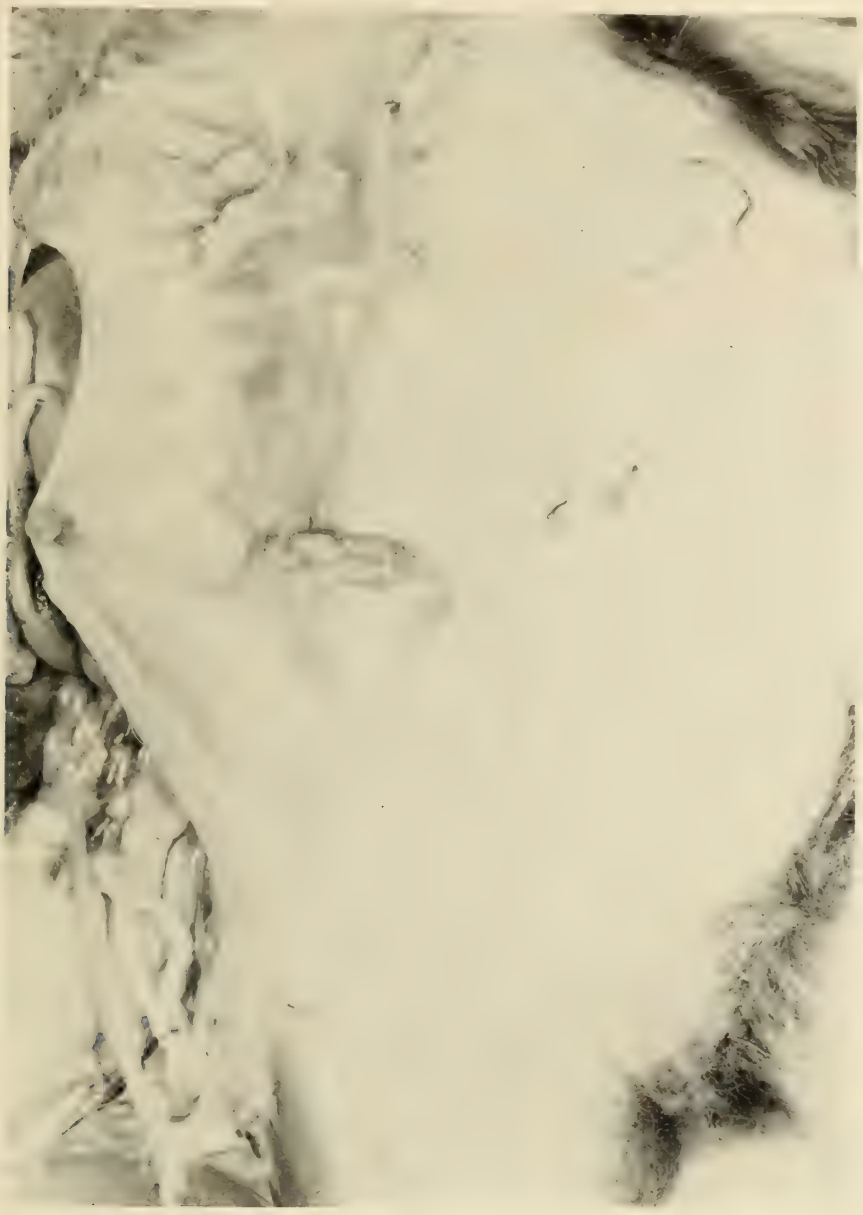

FIGURE 324. TOOTH OF PREVIOUS FIGURE BENEATH THE SKIN OF A RABBIT PRODUCED A SLIGHT LOCAL REACTION BUT RABBIT DEVELOPED ACUTE NEPHRITIS, AS SHOWN IN NEXT FIGURE.

quantity of the chips drilled from the tooth, had to take the chance of being obstructed or annihilated by the various defenses of the body, and all tissues had equal opportunity for making a defense, so far as other parts of the body were concerned. But notwithstanding this, the elective localization quality was suffi-

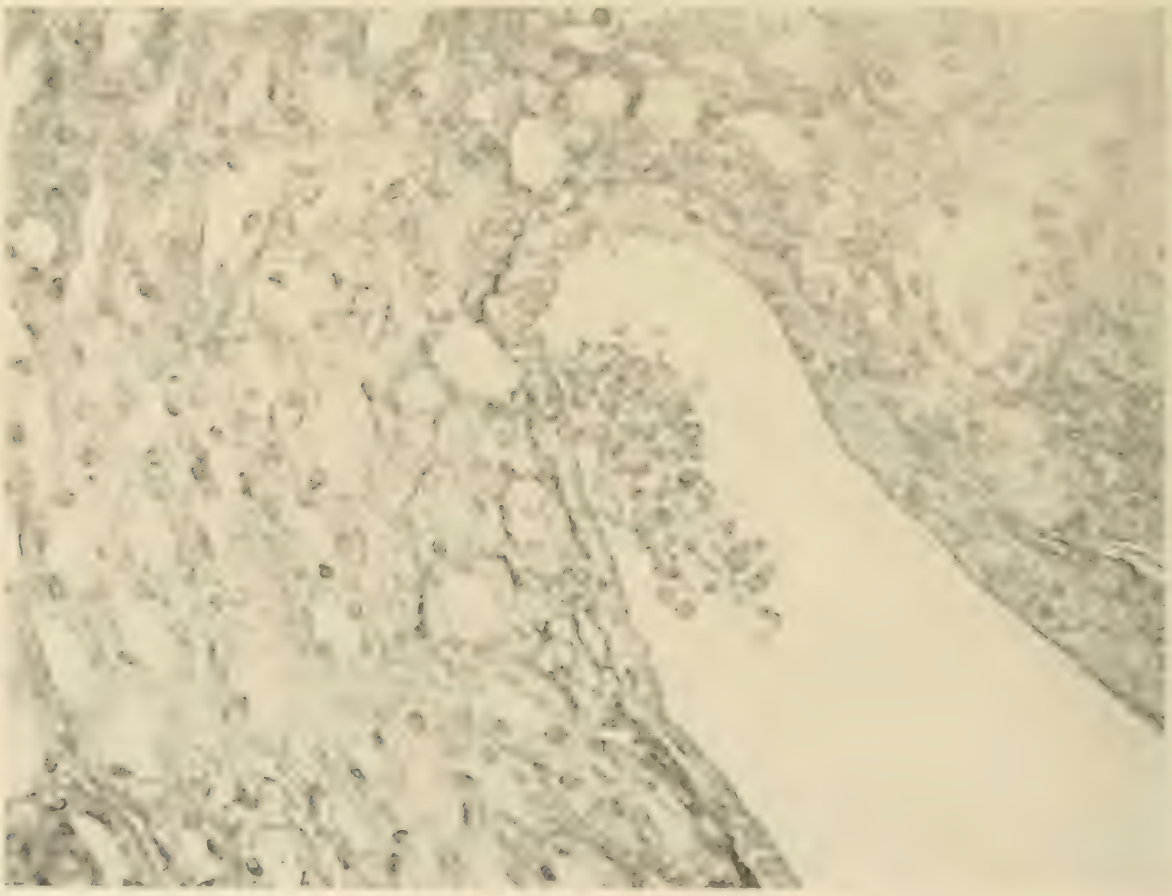

FIGURE 325. SECTION OF NEPHRITIC KIDNEY WITH PUS CELLS.

ciently strong for these organisms to select the kidney, as shown. The total quantity, by weight, of organisms injected with the fine borings would be less than a millionth part of a gram, yet they were sufficient. This is a fact we have demonstrated in many ways many times, and we are stressing it because of the misapprehension that the organisms growing in dental infections are, of necessity, of such low virulence that the quantity that would have to be injected into a man would be from a teacupful to several quarts.

It is very evident that this generation of dentists very much prefers to hear evidence that will justify the leaving of root-filled teeth and particularly justify the retention of teeth for operative procedures, such as crowns, bridges, inlays, etc., from which there could be no further income for the operative dentist after they have once been condemned and assigned to the exodontist and

the prosthetic specialist. I fear another generation of the profession, which we must expect will have much greater information on these subjects, will find it difficult to distinguish between the blindness of ignorance and the blindness of desire.

Kidney involvements express themselves quite differently from different strains. In the two previous cases shown, the hypertrophy of the kidneys was not great. In the next case (No. 573) we have that of a married woman, age forty-one years, suffering from rheumatism and heart trouble. Incidentally, as a part of this study, a urinalysis was made with the result that evidence of nephritis was disclosed. Her extracted tooth was cultured and a rabbit inoculated in the marginal ear vein with 1 cc. of the 24 hour culture. In 49 days the rabbit was posted with the result shown in Figure 326. D shows the two enormously enlarged kidneys of the rabbit, five times their normal weight for the weight of the rabbit, and a normal kidney beside them; A and B show the histological appearance of the kidney; and C shows a cast from the patient's urine. The following is the pathologist's interpretation of the sections from this kidney:

"*Inverted Ocular* shows a large wedge-shaped piece of tissue of a spongy character, stained with a light pink color. The large part of the section shows a great number of dilated spaces, resembling small cysts. Among them one can see the very small, shrunken down glomeruli. Most of those dilated, cyst-like spaces have a pinkish stained material.

"*Low Power.*—The cortical portion of the kidney is represented entirely by a great number of dilated tubules and glomeruli, giving the picture of a multiple cystic condition. Practically every one of the glomeruli is gone; only a small piece of the tuft is left and has lost its attachment to the Bowman's capsule. All these tubules are markedly dilated, the lining membrane gone, and the walls in between the tubules are only of a fibrous tissue. In some places some of the tubuli are seen to be compressed among the neighboring dilated tubules, their lining also disappearing and being represented as small empty vesicles. In some of the tubules, large dilated and small compressed, one can see a colloid material, in some instances mixed with a few desquamated epithelial cells. As one examines the tissue from the cortex down toward the medulla, the dilated tubes are larger and larger and in many cases two or three have joined together. The tubules in the medulla show degenerative changes, vacuolation in the cells

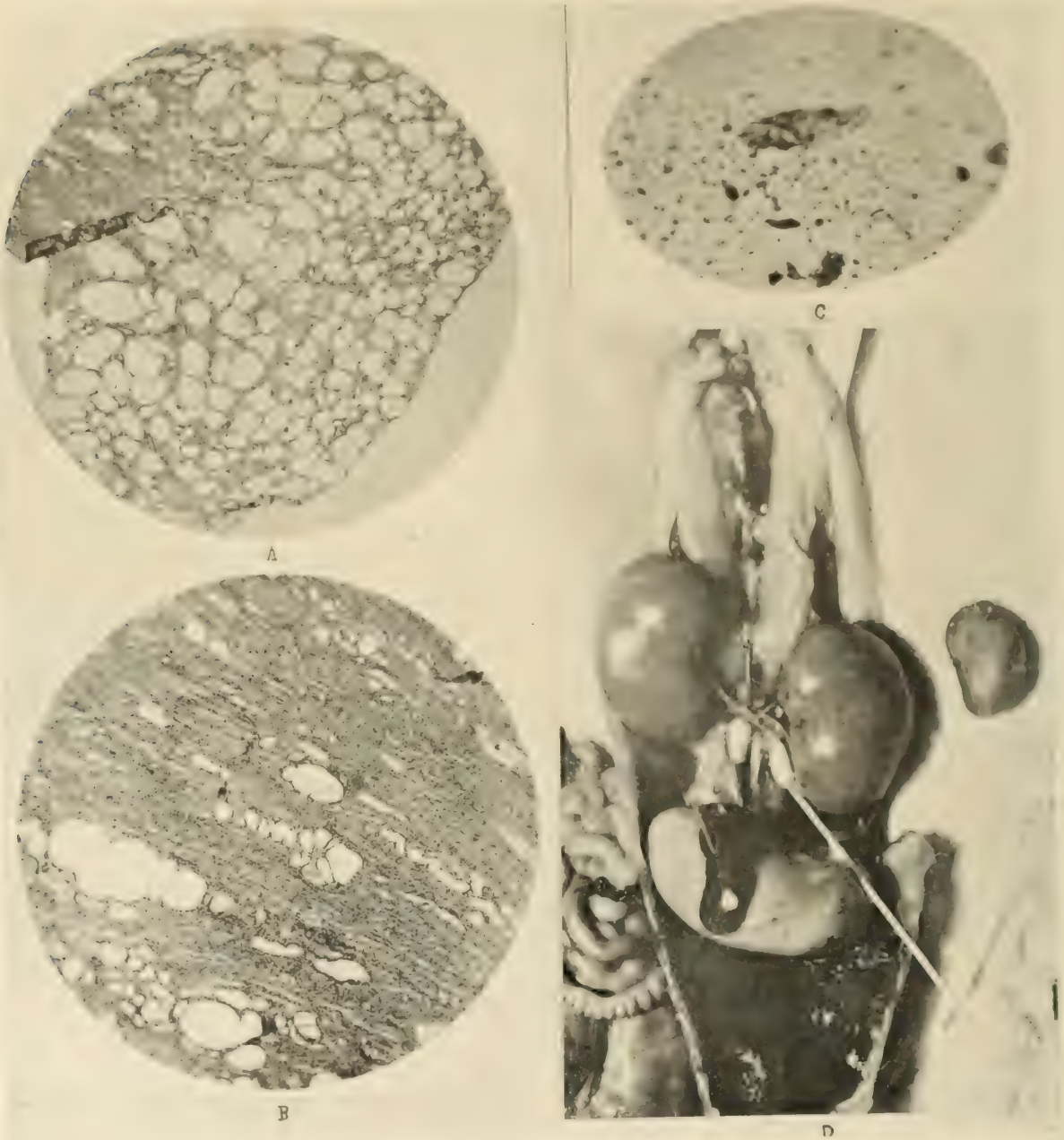

FIGURE 326. ACUTE INTERSTITIAL NEPHRITIS PRODUCED IN A RABBIT. A AND B, TISSUE SECTIONS SHOWING CELLULAR NECROSIS AND EDEMA. D, BOTH KIDNEYS OF INJECTED RABBIT, FIVE TIMES NORMAL SIZE. SEE NORMAL KIDNEY TO RIGHT, ALSO HYPERTROPHY OF ADRENALS. C, CASTS FROM PATIENT'S URINE. CASE NO. 573.

of the lining membranes. In some places many cells show complete cellular necrosis. The blood vessels are dilated.

"*High Power* shows the same changes as above.

"*Diagnosis.*—Acute interstitial nephritis with marked, acute edema of the tubules and glomerular structures of the cortex (especially)."

As this case is not reviewed in the heart cases, we will state that the patient's mother and mother's mother, and a brother and sister of her mother, all died of heart lesions. This was, accordingly, a susceptible tissue in this patient. Her lassitude, rheumatism, and nephritis all cleared up quite promptly and have been absent for three years so that she has again taken up her routine hard work as an office secretary and is carrying a very heavy overload without recurrence of her almost prostrating symptoms from which she formerly suffered. Two of the teeth that were extracted are shown in Figure 327, and you will note the marked



FIGURE 327. TWO OF THE TEETH OF PREVIOUS CASE PRODUCING KIDNEY INVOLVEMENT. NOTE CONDENSING OSTEITIS, NOT RAREFYING.

tendency to condensing osteitis and the absence of the rarefying osteitis so generally looked for. The culture was taken from the teeth shown in Figure 327, which was inoculated into the rabbit which produced the acute nephritis shown in Figure 326. Figure 328 shows the susceptibility chart of her case.

BLADDER.

Bladder irritations are frequently caused or aggravated by dental infections. This will be illustrated by the following case. A man of sixty-five was so distressed with cystitis that for five years he had been unable to leave his home to visit his family, and was required to void his urine from every thirty minutes to one hour or his distress would be unbearable. This, of necessity, greatly disturbed his rest. A bacterial examination of his urine showed an abundant staphylococcal infection. The teeth shown in Figure 329 were extracted and his cystitis improved within twenty-four hours, and in two weeks' time he was retaining his urine for five hours with so complete a relief of his distressing symptoms, that he went to New York to visit his son and remained several weeks without annoyance or discomfort.

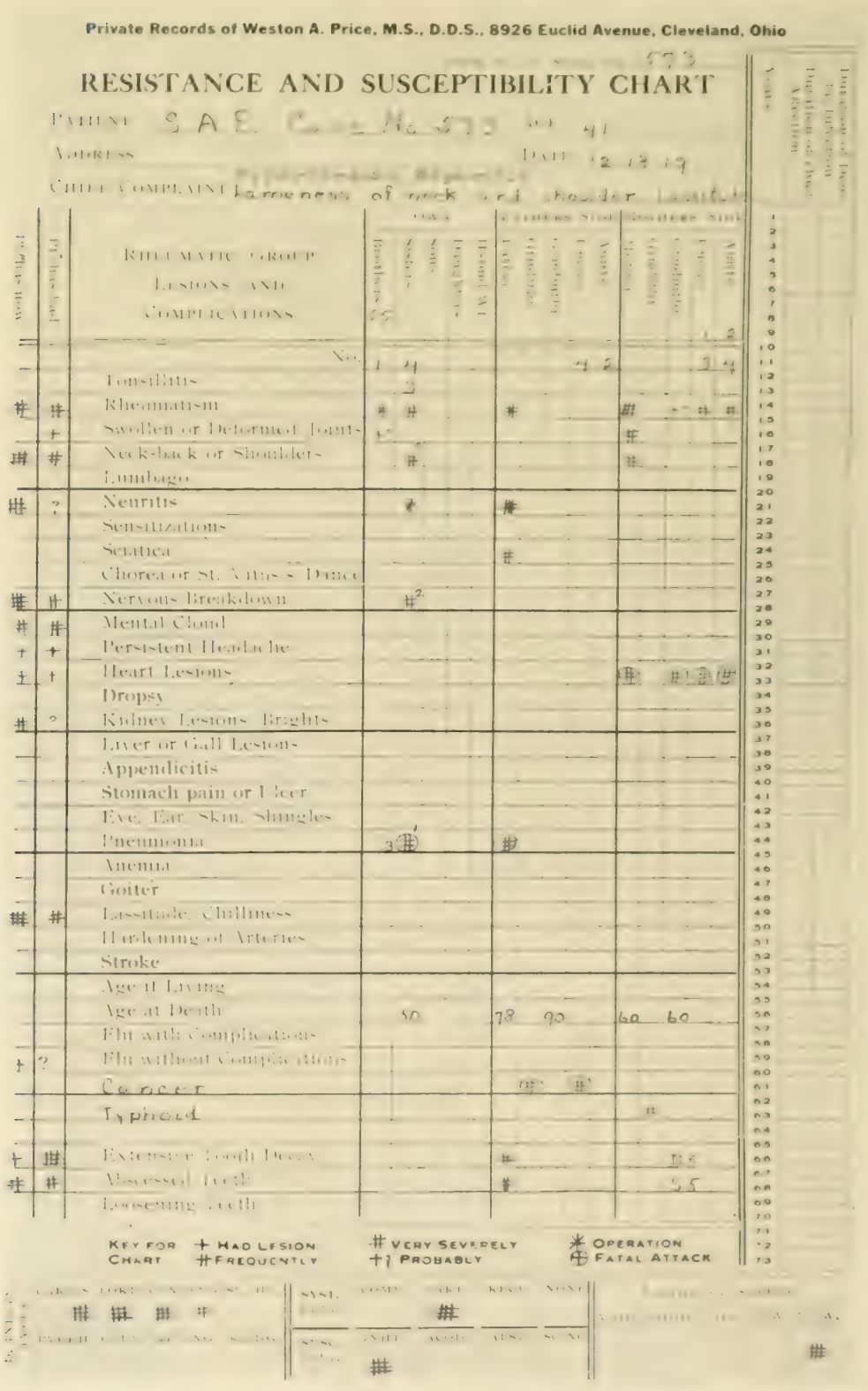

FIGURE 328 SUSCEPTIBILITY OF PREVIOUS CASE, NO. 573. NOTE FOUR CASES OF DEATH FROM HEART INVOLVEMENT ON MOTHER'S SIDE.



FIGURE 329. TEETH WHICH PRODUCED ACUTE AND CHRONIC CYSTITIS, WHICH PROMPTLY DISAPPEARED AFTER THEIR EXTRACTION.

In our experimental animals we frequently see very marked distention of the urinary bladder, following our inoculations, with ulcer formation on the bladder wall. Figure 330-B shows a bladder approximately twenty times its normal size. Figure 330-A shows a large ulcer on the inner surface of this bladder. This rabbit was inoculated with the culture of a tooth shown in Chapter 66 on the Central Nervous System, and the retention of urine was due to a complete paralysis from a lesion of the spine. The patient, from whose tooth the culture was taken, was suffering from recurring central nervous system disturbance. This rabbit had been affected with incontinence of urine prior to the development of retention. This lesion is of particular interest because of the recent important work of the surgeon, Dr. Richard Cabot, in which he has shown the importance of the prevention of retention of urine because of the important role it plays in the production of bladder lesions. It is very significant in looking over our records that, approximately, three per cent of the rabbits inoculated with dental cultures, show gross evidence of cystitis at necropsy.

The great importance of the susceptibility study and physical history of the patient will be shown in a review of Case No.781. The patient, twenty-eight years of age, presented for dental care. The only physical disturbance complained of was lameness in her back. A roentgenographic study of her teeth did not reveal conditions that were considered serious. A crowned molar was considered border-line. A susceptibility study, shown in Figure 331, was made. This and her history revealed that her personal condition had been good until her recent disturbance. Her father was living, was sixty-three years of age, and has had excellent health and freedom from all rheumatic group lesions. His father lived to eighty-five. Her mother's record, however, shows that she

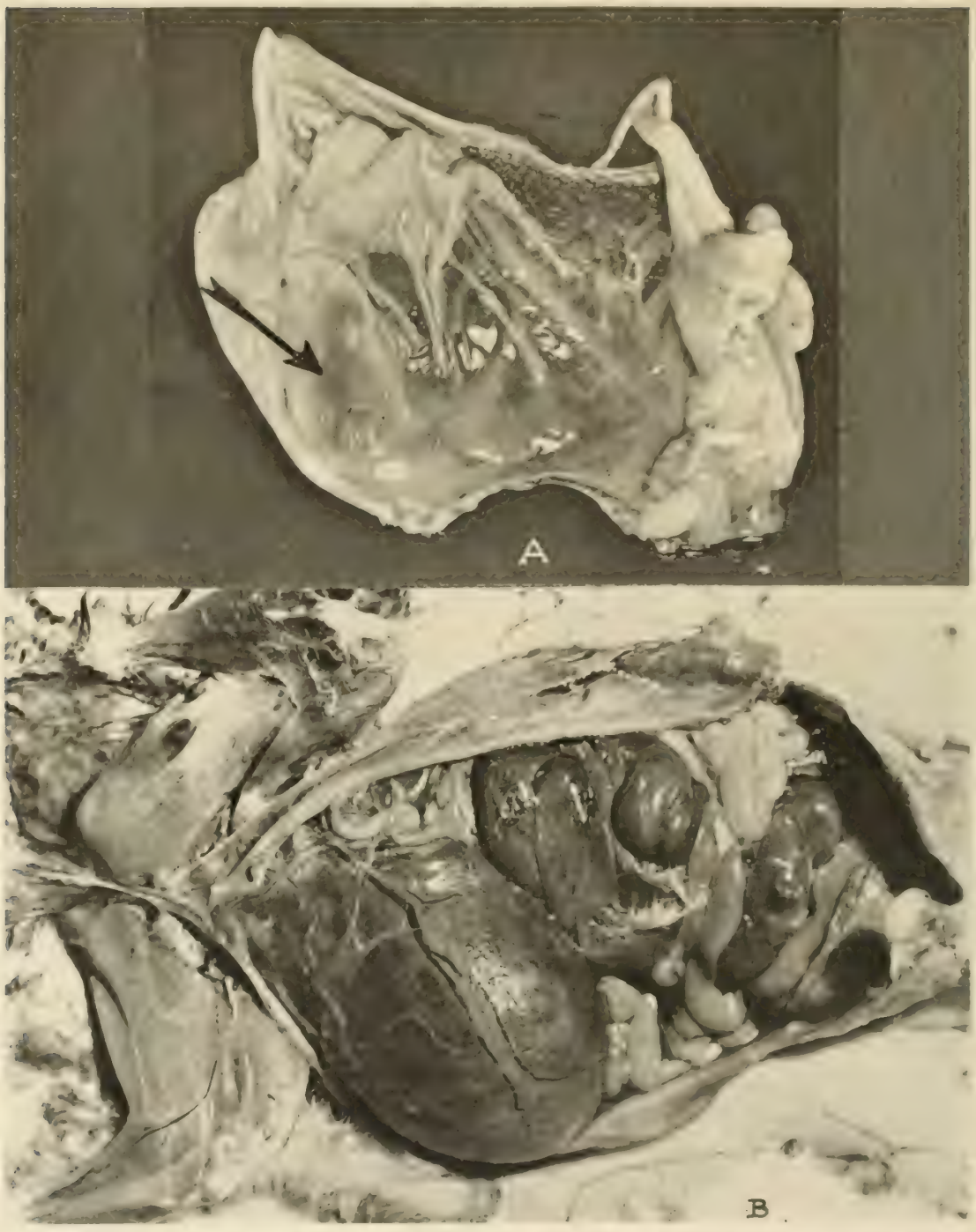

FIGURE 330. PARALYSIS OF THE BLADDER WITH RETENTION, PRODUCED IN A RABBIT BY DENTAL INFECTION. BLADDER IS TWENTY TIMES ITS NORMAL SIZE, AS SHOWN IN B. A SHOWS DEEP ULCER ON INNER SURFACE OF DISTENDED BLADDER.

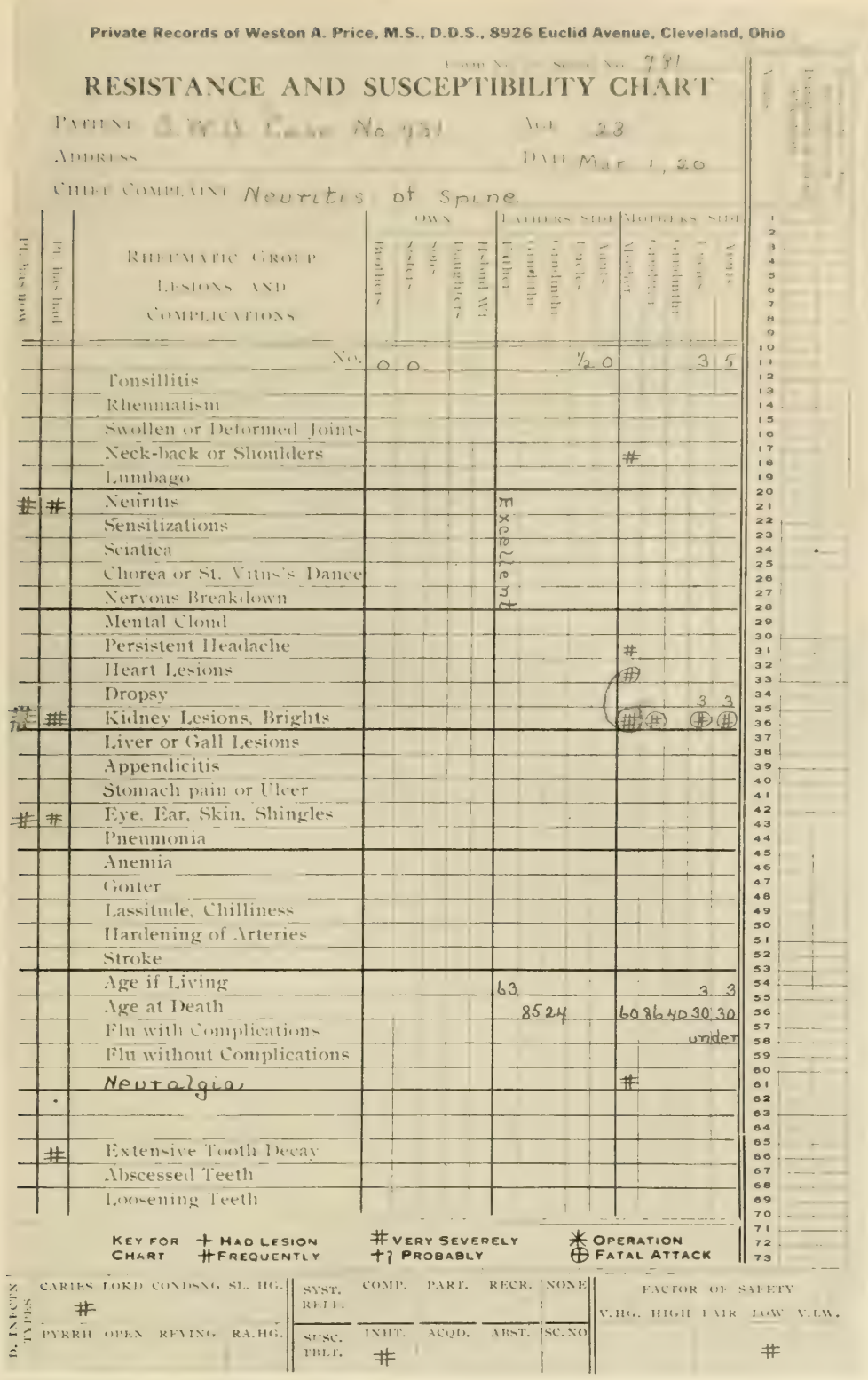

FIGURE 331. SUSCEPTIBILITY CHART OF APPARENTLY NORMAL PATIENT. NOTE EIGHT CASES OF DEATH FROM BRIGHT'S DISEASE ON MOTHER'S SIDE. EXAMINATION OF PATIENT SHOWED SAME ACUTELY DEVELOPED, THOUGH UNSUSPECTED, AT AGE TWENTY-EIGHT.

died at sixty of acute heart involvement and kidney involvement. Her mother's father died of Bright's disease as did three of her mother's brothers at about thirty years of age and three of her mother's sisters at about that age. In other words, of nine children of which her mother was one, seven died and their father died either because of, or with, Bright's disease, only two of the nine escaping. This strongly suggested that a careful examination and study be made of this patient's kidney function. This was done and it was found that she already was showing albumin and casts. She was accordingly referred to her physician for careful observation and treatment and the tooth in question was no longer border-line. It was extracted, for our interpretation, growing out of our experience, is that no person should be permitted to carry definite dental infection who has an involvement of an organ of which that infection would be likely to increase the severity, if that organ is one whose impairment would seriously injure or endanger the patient's life or health. In other words, I do not consider it safe for a patient having a distinct evidence of either heart or kidney involvement, to carry a root-filled tooth, because I do not know of any method which has stood the test as being competent to make such a tooth completely free from infection and source of toxin, and retain it so, and because I feel that patients with susceptibility to these affections will, of necessity, have a low factor of defense immediately about the tooth. In other words, they will not have the ability to maintain an adequate quarantine against either or both the toxic substances developing in the tooth or the bacterial infection from that source, if it should develop. I further believe that all root-filled teeth sooner or later, and most of them sooner, become infected to some extent, if they are not already so at the time of root filling, unless that patient has a very high defense and is able to maintain a high state of systemic defense and protection of the culture medium which develops in even well root-filled teeth from systemic infection.

There is a phase of kidney function which should be discussed in this connection and is related to a disturbance of the ionic calcium of the blood as a pathological condition of that fluid. Under normal conditions of sugar content of the blood there is an ample factor of safety which adequately prevents sugar from appearing in the urine. If, however, for such reasons as we shall present, sugar does appear in the urine without its elevation beyond the threshold of danger in the blood, it does not constitute a diabetes



FIGURE 332. HYPERTROPHIED KIDNEY AND CASTS FROM URINE OF A RABBIT WHICH DEVELOPED SEVERE NEPHRITIS IN SIXTEEN DAYS FROM THE IMPLANTED TOOTH SHOWN, WELL ENCAPSULATED.

mellitus. The secreting cells of the glomeruli which normally are impervious to the sugar of the blood as it passes through the adjoining venules, may become permeable by an increase in the ionic calcium of the blood above its normal. It is not yet established to what extent a loss of function of the island of Langerhans of the pancreas tends to increase the ionic calcium of the blood. It is, however, an apparently associated condition in that, as we have shown in other chapters in our study of the relation of periodontoclasia to diabetes, the ionic calcium of the blood is, practically, always high and tends to be pathologically so in both these conditions. We have then the suggested possibility, if not a probability, that disturbed kidney function through the medium of disturbed ionic calcium of blood may be directly related to periodontoclasia or pyorrhea alveolaris.

I have now had so many instances where rabbits developed acute nephritis from each of the procedures, the inoculation of cultures and the planting of teeth from patients with and without nephritis, but particularly so in patients with nephritis, that I find no way of escaping the placing of the responsibility of a great many of the kidney disturbances on this source. In Figure 332 will be seen the dissection of a rabbit which had a bicuspid tooth planted beneath the skin. It died in sixteen days with a loss of 310 grams, or approximately 25 per cent of its weight. On opening up the skin there was an encapsulated subcutaneous abscess about the tooth, a smear from which showed Gram-positive streptococci in individual forms and small chains, and also some Gram-negative organisms. The heart showed hyperemia of the myocardium, with ulceration of the aortic arch. The kidneys showed parenchymatous nephritis. The urine showed casts. In the illustration of this case, the encapsulated tooth is shown, and also the hypertrophied kidney and casts from the urine of this rabbit.

In Figure 333 will be seen a cast from the urine of a rabbit dying with kidney involvement from the planting of a tooth in two days after the planting of the tooth. (Rabbit 1144.) It is probable that any infection that will sufficiently overwhelm an animal or individual and produce death will, at death, so overload the kidney as to produce marked disturbance of function, and it must not be considered that the presence of casts will, of themselves, be an indication or proof of an acute or chronic nephritis. Their presence, however, is distinctly pathognomonic and, as such, have very clear significance.



FIGURE 333. CASTS FROM URINE OF A RABBIT DYING IN TWO DAYS WITH KIDNEY INVOLVEMENT, FROM THE PLANTING OF AN INFECTED TOOTH BENEATH THE SKIN.

CHAPTER LXIV.

SKELETAL AND MUSCULAR SYSTEM.

DISCUSSION.

It is exceedingly difficult, in the present state of our knowledge, to differentiate between lesions of the nervous and muscular systems, and it seems very probable that frequently both are involved in the same case. We shall, however, endeavor to adhere to our classification according to the biological classification of tissues. We will, accordingly, present the cases under the subclassifications of (1) acute rheumatism, (2) deforming arthritis, (3) synovitis, (4) osteomyelitis, and (5) myelitis.

It is not clear, as yet, to what extent the reactions are to toxins or to bacterial invasion. I will show cases in which I have secured the culture from the mycsitis of both the patients and the rabbits and show them *in situ* in sections of the tissues from both sources. The evidence is, therefore, convincing to me that the organisms do localize in the muscles in certain cases. This is not only true of muscles but of synovial membranes, for we have on scores of occasions located the same strain, which we have inoculated, by culturing from involved joints. A typical illustration of such is shown in Figure 334. I have shown in the experimental chapters of Part One, that these inflammatory processes very frequently have their first expression as zones of local ischemia, and the evidence is accumulating to emphasize the possibility, if not probability, of many of these localizations beginning as sensitization processes. In patients carrying focal infections, the presence of the toxic substance from these zones produces anaphylactic reactions. Such tissues, as in that patient, readily develop or occlude the antibody which combines with the antigen, thereby producing locally the various phases of sensitization reaction, one of the first of which is the marked and rapid relaxation or enlargement of the capillaries. This is followed by a rapid accumulation of leucocytes about the zone receiving the acute hyperemia. This may be followed by localized stagnation sufficient to develop degeneration or even necrosis of cells. The antigen producing this reaction may, I believe, be the toxic substance from the focal

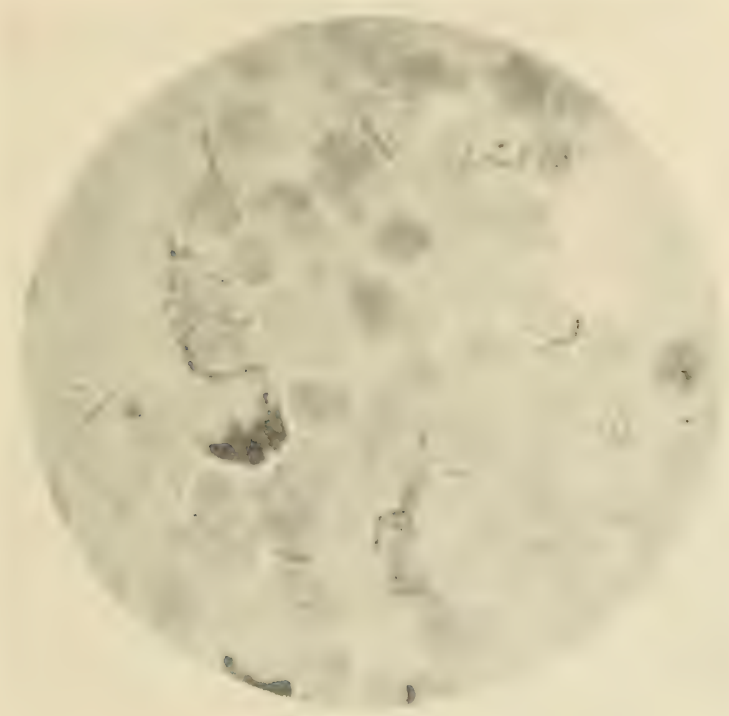

FIGURE 334. TYPICAL ILLUSTRATION OF STREPTOCOCCI AND DIPLOCOCCI IN JOINT FLUIDS OF ANIMALS INOCULATED WITH A DENTAL CULTURE.

infection without the presence of any bacteria. When, however, degeneration or death of a few or many cells has occurred, they readily become the pabulum for infection, and particularly for the strain producing that toxic substance. We have, therefore, as a secondary process, the infection of the lesion produced by the preliminary anaphylactic reaction.

In highly vascularized tissues it becomes readily possible for these degeneration products to be limited quite sharply and for an ultimate quite complete repair by the successive processes of inflammation. In the poorly vascularized tissues, however, such as bone, synovial membranes, dentin, etc., the repair is less simple and frequently less complete; and since mechanical destruction of hard tissue may involve much greater problems of readjustment and repair, fixation and deformity may readily develop. In these hard tissues we must recognize two distinct types of inflammatory reaction, one largely degenerative with the tearing down of hard structures, and the other proliferative with the building on on hard tissue and the calcifications of soft tissues, first as fibrosis and then a calcification of this tissue. It is not possible

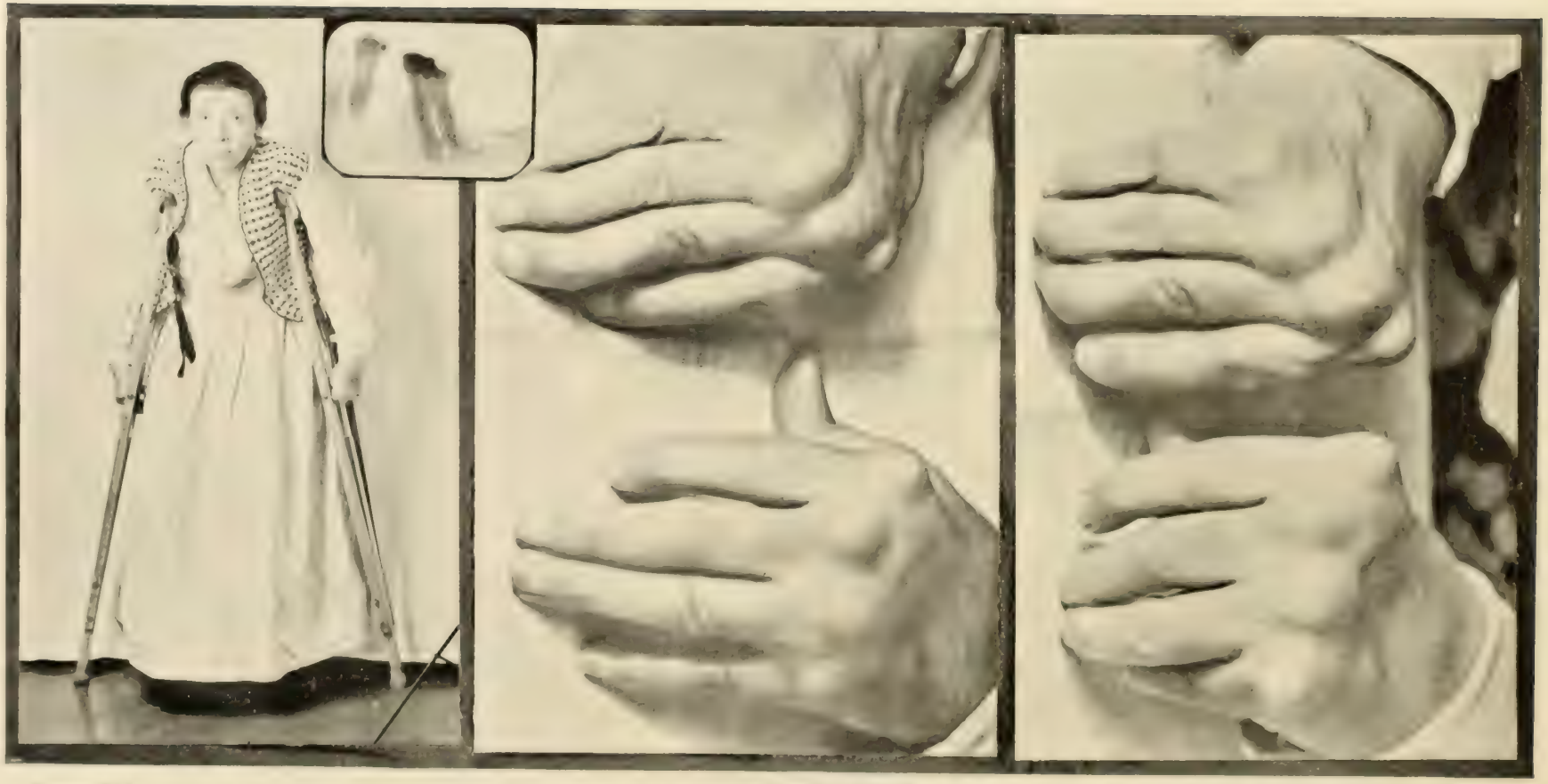

FIGURE 33.5. CHRONIC DEFORMING POLYARTHRITIS. THIS WOMAN WAS A BEDRIDDEN CRIPPLE, COMPLETELY HELPLESS FOR SIX YEARS. SHE NOW WALKS ABOUT HER HOUSE WITHOUT EVEN A CANE AND DOES BEAUTIFUL FANCYWORK. NOTE CONDENSING OSTEITIS, NOT RAREFYING, ABOUT TOOTH. CASE NO. 709.

yet, clearly to define and differentiate between these two types. I will, however, show illustrations of both, and with some will give some suggestions as to important etiological factors.

In Chapter 3 I have discussed the different types of bone change found in patients and produced in rabbits by inoculation of different strains. The problem of prognosis is very greatly influenced by the type of lesion that has been produced by the infection. Nature seems capable of making very complete repair of rheumatic group lesions in muscle tissue, and frequently very poor repair of lesions in bone tissues, particularly if the latter have involved the destruction of the vascularization. We have, accordingly, come to be very guarded in the matter of giving encouragement for marked relief in all cases of deforming arthritis, because of the serious structural changes, the abundance of the scar tissue (in this case of bony scar tissue), and the permanent susceptibility of such individuals; for it is generally recognized that in these lesions one attack predisposes another. This, however, can be said of most, if not all, of the rheumatic group lesions which are, apparently, associated with the biologic characteristics of these strains of the streptococcus group of organisms. We have, however, had some very marked improvements in even severe cases. Figure 335 shows such a case.

Case No. 709.—This woman, unmarried, forty-seven, was carried to us seven years ago with such extreme deforming arthritis that she had been bedridden for six years. When first brought to us, her spine, hips, knees, and neck were so stiff that she could be lifted by her head when lying down and without muscular effort could be raised to standing position; and if she had been leaned against the wall, she would remain there as incapable of moving as a broom handle leaned against a wall. She had not been able to feed or wait on herself for five years. Figure 336 shows the teeth that were extracted at that time. She was given an autogenous vaccine made from the extracted teeth. Improvement was so marked and rapid that in three months' time she was walking with crutches, and has continued to improve continuously for five years except at one time. She is now one of the busiest seamstresses in Cleveland and does most beautiful embroidery and drawn-work, takes care of herself and her room, and with the return of her health is one of the most grateful, happy souls one could ever find. Her hands that were as stiff as castings, or nearly so, have limbered up so she can thread needles and exe-



FIGURE 336. SOME OF TEETH OF PREVIOUS CASE OF DEFORMING ARTHRITIS, EXTRACTED SEVEN YEARS AGO.

cute most difficult lace patterns. Her work is eagerly sought because of its exquisite beauty. At one time she had a return of her symptoms for a few months. A careful examination disclosed a non-vital pulp, shown as an insert in Figure 335. This tooth was not painful to mastication, nor had she at this time any symptoms from it though there was a history of its having been hypersensitive to heat and cold several months previous. Note this tooth does not have an area of rarefaction about its apex expressed as radiolucency in the roentgenogram but, on the contrary, an area of radiopacity due to a condensing ostêitis. Her hands in two stages of her arthritis are shown in Figure 335. At the time of the extraction of this lower right first molar, a trephine was used to remove for sectioning a piece of the condensed bone. This is shown in Figure 337. Note its structure not unlike that of a curly maple. The blood vessels have been greatly reduced in size. A culture was taken from the pulp of this tooth and inoculated into rabbits, one of which is shown in Figure 338 with acute purulent arthritis with marked suppuration.

This patient is shown in this picture with her crutches, but we are glad to report that since writing the above we are advised that she is going about her home and yard without her crutches and is, accordingly, progressively improving whereas she had been progressively growing more and more bed-fast. It should be noted that the treatment of her case consisted not only in the removal of her dental infections but the use of an autogenous vaccine, which is a very important procedure in many of these cases whose defenses are just below the level needed for keeping them on the aggressive fight against the strain.

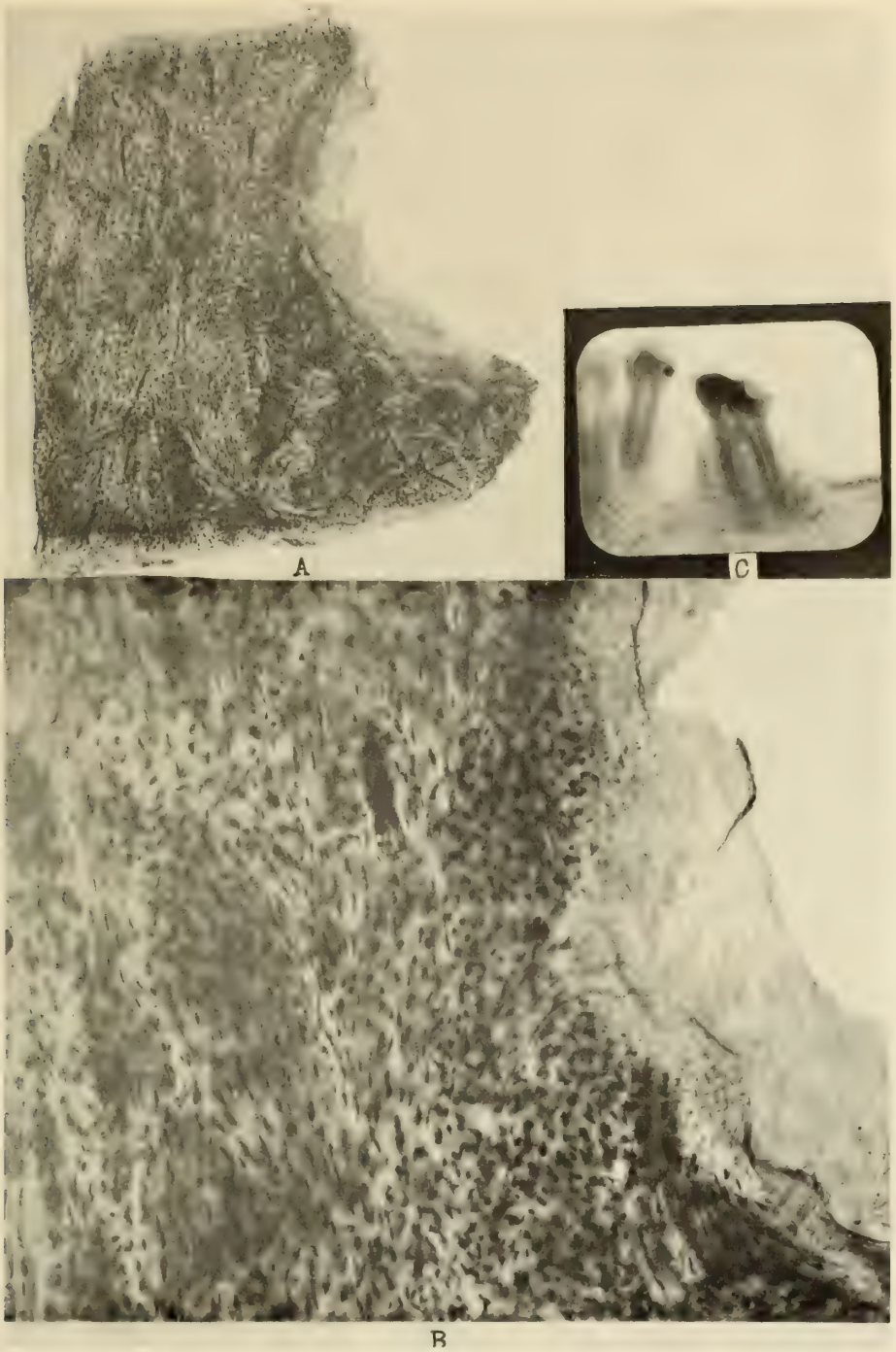

FIGURE 337. HISTOLOGICAL STUDIES OF PERIAPICAL BONE. A, PHOTOGRAPH OF TREPHINED CYLINDER. B, HISTOLOGICAL SECTION. NOTE DENSITY. C, ROENTGENOGRAPHIC APPEARANCE. CASE NO. 709.

Still another type of deforming arthritis, which would usually be considered to have a very bad prognosis, affects, chiefly, the spine, hips, and shoulders, without much involvement of the



FIGURE 338. ACUTE PURULENT ARTHRITIS PRODUCED IN RABBIT FROM CULTURE FROM TOOTH SHOWN IN C OF PREVIOUS FIGURE. CASE NO. 702.

extremities. We have, however, seen such marked relief in some of these cases, that we have come to be much more hopeful and encouraging, provided there is a locked dental infection of the type that we have come to consider particularly causative in this type of disturbance. Such a case is shown in Figure 339.

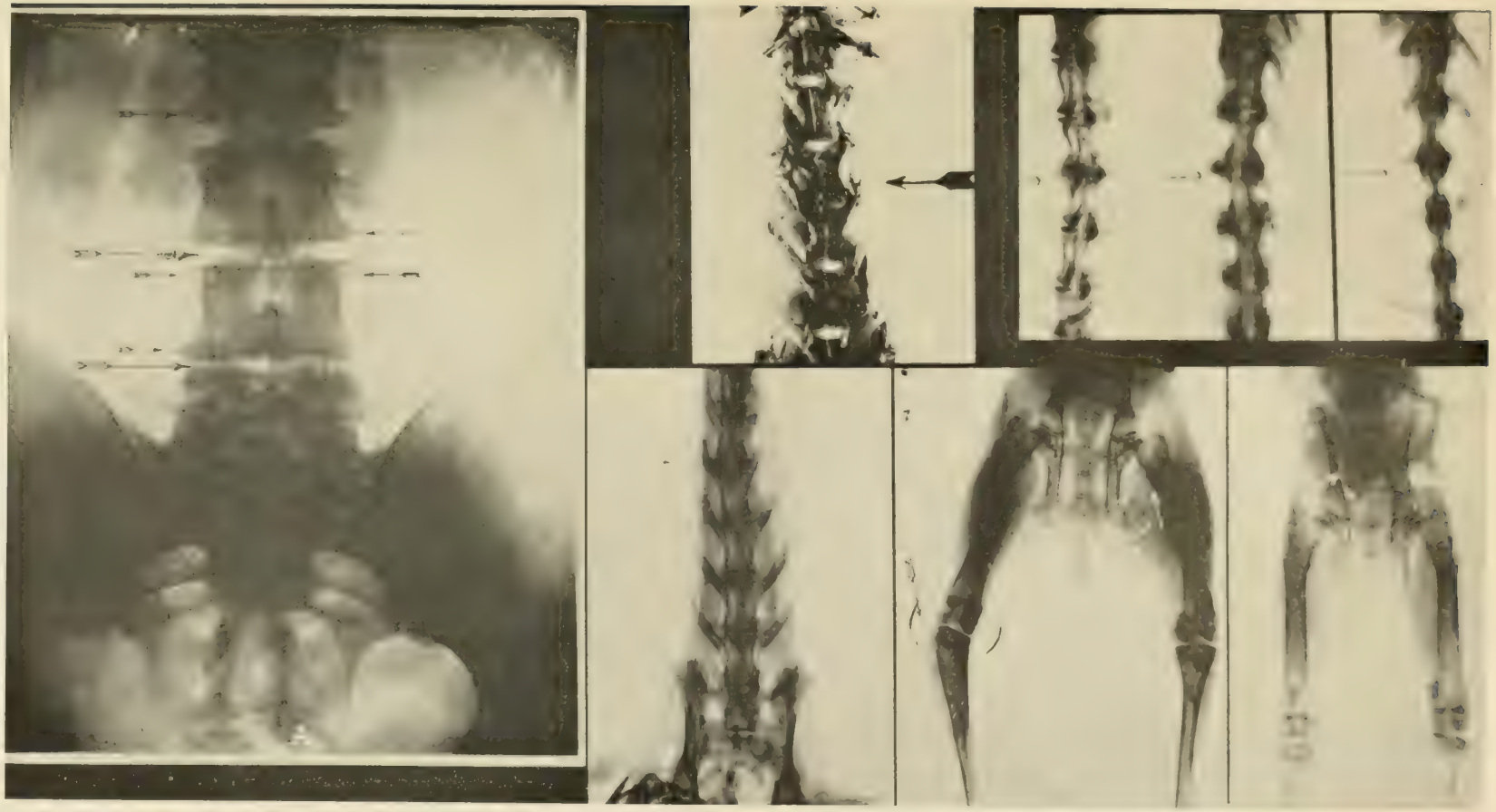

FIGURE 339. ARTHRITIS OF THE SPINE AND HIPS OF PATIENT SHOWN IN A, AND IN SPINES AND HIPS OF RABBITS INOCULATED WITH CULTURES FROM HIS TOOTH. CASE NO. 1125.



FIGURE 340. PUTRESCENT UNFILLED ROOT OF CUSPID. TOOTH HAD BUT SLIGHT APICAL ABSORPTION AND NO FISTULA.

Case No. 1125.—This case, a male, age forty-seven, laborer, is of particular interest because it seems to be very definitely related to bad dentistry; and while the profession of the past may not have been responsible for its ignorance, the time should soon come, and doubtless will, when the public will see to it that they shall not, because of ignorance, be given a lifetime of suffering, thus becoming dependent cripples. The dental condition in question, a very imperfect operation on a root canal of the upper left cuspid, is shown in Figure 340. The pulp chamber had been entered and a very incomplete root filling placed underneath the metal filling twenty-three years prior to the patient's presenting to us, with the extreme deforming arthritis with ankylosis of the spine. Seventeen years ago, he injured his back by lifting, this not being considered serious at first. Acute rheumatism set in in the injured tissue, stiffness began about fourteen years ago, and during this period he has had exacerbations with acute and painful processes, always followed by greater stiffness following the course of progressive arthritis. At the time of presentation eighteen months ago, he was not able to rotate the body or bend the spine, appreciably, from his hips to his head. He had been compelled to give up his work and was becoming very despondent. The pain was extending down the left sciatic with involvement beginning in the left leg. The tooth in question had the history of having been painful at recurring periods soon after it was filled, but had presented no symptoms whatever of discomfort for many years, the patient thought not since the rheumatism had developed. He had no other treatment than the removal of this infected cuspid which was surrounded by a zone of condensing osteitis outside a zone of rarefying osteitis. As shown in the roentgenogram, there is a zone of excementosis on the side of the root. His nervous symptoms had become quite marked at the



FIGURE 341. SHOWS IMPROVEMENT IN THE MOVEMENT OF THIS MAN'S SPINE IN THREE MONTHS' TIME AFTER EXTRACTION. A, LIMIT OF LATERAL MOVEMENT AT BEGINNING. B, IN THREE MONTHS. C, LIMIT OF FORWARD AND BACKWARD MOVEMENT AT BEGINNING; AND D, AFTER THREE MONTHS.

time of the extraction, the first effect of which was to aggravate them. However, in three months' time he could move his spine both forward and backward as well as make considerable rotation of it, as shown in the photograph, Figure No. 341, which

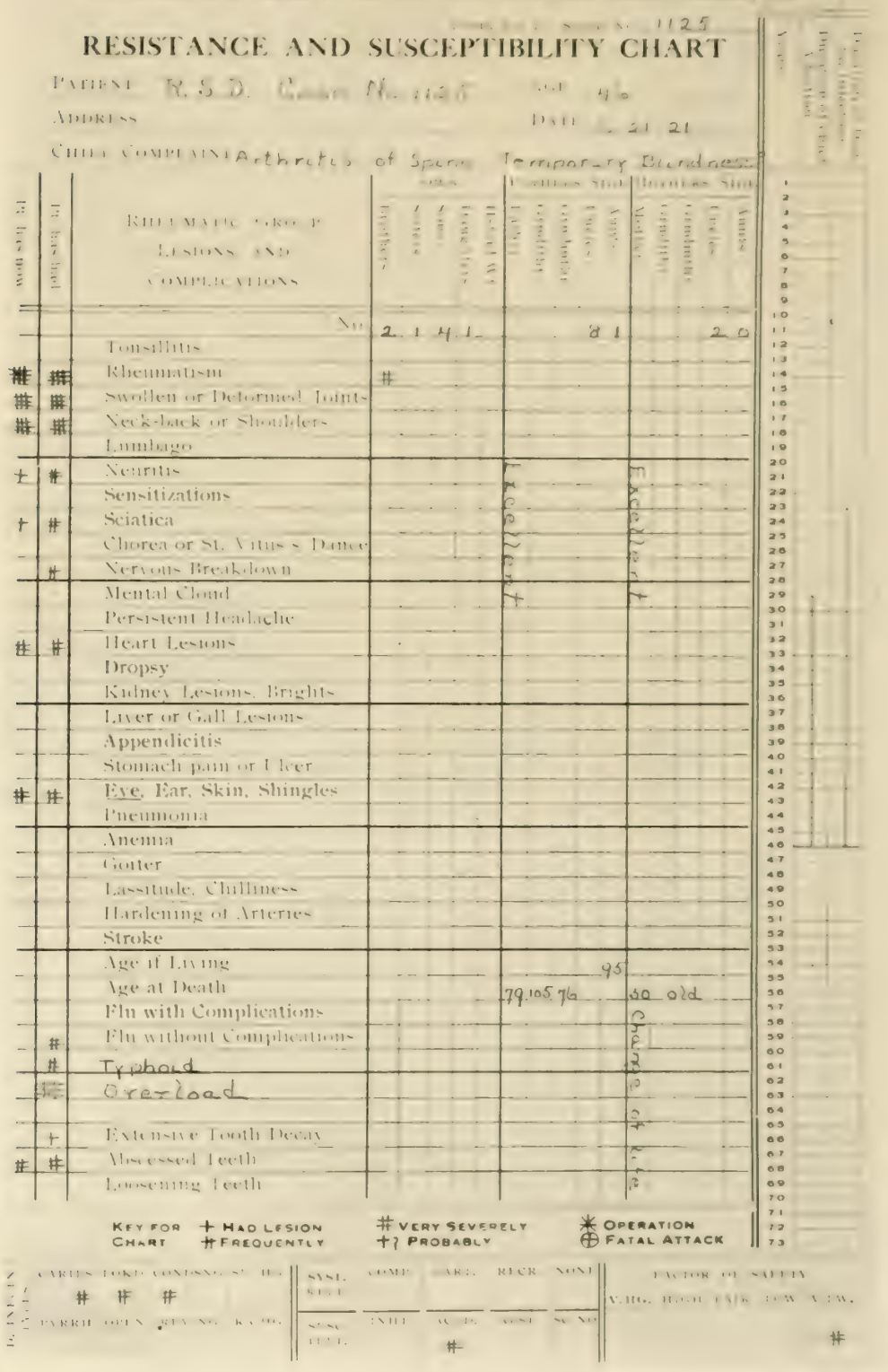

FIGURE 342. SUSCEPTIBILITY RECORD OF PREVIOUS CASE, NO. 1125. NOTE GOOD INHERITANCE. ALSO IN COLUMNS TO RIGHT, DURATION OF CHIEF AFFECTION WAS LESS THAN THAT OF THE DENTAL INFECTION. SPINAL DISTURBANCE FOLLOWED AN INJURY PLUS HIS FOCAL INFECTION.

shows the limit of movement sideways, forward, and backward, before and after this three months' period. He had complete relief from the acute rheumatic processes; and in about six months, he went back to work. Life had an entirely new prospect. He changed from progressively getting worse through a period of fourteen years, to suddenly getting progressively better. Nothing was done except the removal of dental infection. We shall expect, however, that this patient will readily develop arthritic processes again and it will be quite probable that his improvement will not be continuous or permanent after the development of such a severe focus, which is true of many, if not most, of these extreme cases.

A study of his susceptibility is particularly instructive. See Figure 342. His is a case of acquired susceptibility. He had about as bad a type of dental infection as it is possible to have: namely, the quantity of infection that may exist in a putrescent pulp and the entire dentin and tooth structure of a tooth for a long period of time. During the early period of the history of this tooth, when his resistance was high and he had no injured tissues, the reaction about the tooth was sufficiently good to protect him from this infection and expressed itself, locally, in extensive rarefaction, with an apical abscess and fistula. With a lowering of his resistance, he lost the ability to maintain the quarantine about the tooth and became injured by its contents. At this time the local reaction was much less efficient, the fistula healed and closed, and the old scar was plainly visible at the time we operated. It was like a quiescent volcano. The toxic material was now taking a new route: namely, through his system. It was injuring the most susceptible tissue which began with his injured spine. As shown in Figure 342, there were practically no rheumatic group lesions in the brothers or sisters, sons or daughters, or on either side of the ancestry, his father's father living to be one hundred five, his father to be seventy-nine. His mother died at fifty with nervous disturbance developing with the menopause. Her parents died old. There were no cases of arthritis on either side of the family. His father was one of ten children and the father's sister is still living at ninety-five. We should expect that if all his overloads could be removed, the prognosis should be very much more favorable than in a person whose normal defense should not be expected to be high, which his should be. Clinically, this type of susceptibility does not often



FIGURE 343. EXTREME DEFORMING ARTHRITIS PRODUCED IN A RABBIT INOCULATED WITH CULTURE FROM THE TOOTH SHOWN IN FIGURE 340. PREVIOUS CASE, NO. 1125

have an involvement, as deforming arthritis, and we would put considerable importance upon the fact of the type of tissue that was injured and which thereby became a prey to his infection. The marked symptoms of his nervous system were in accordance with the general experience in cases of acquired susceptibility.

Returning to Figure 339, it will be noted that there was a very marked tendency to the formation of osseous spicules on the spines and bodies of the vertebræ of the patient. It is very important that the type of reaction produced in animals, with the culture taken from this case, was quite like that in the patient. One of the rabbits developed acute involvement of the spine. (See Figure 339) and also spicula on pelvic bones. Another developed marked deforming arthritis with bowing of both hind legs, as shown in Figure 343. We have discussed this case in connection with the different expressions of bone changes, rarefying and condensing, etc., in Chapter 3.

Case No. 896.—In comparison with the two preceding cases with regard to the type of bone changes, we will present as the next case that of a woman, age at the time of this writing forty-eight, who presented two years ago with a type of multiple deforming arthritis in which there was much disfigurement without extensive arthritic deposits. This patient had not walked for five years, during most of which time she had not been able to feed herself. The extreme deformities of her feet and hands began about eight years ago and are shown in Figure 344, as she is propped up in a wheel chair for the purpose of having her photograph taken. Within four months from the time her dental infections were removed, which was followed by a vaccine made from an autogenous culture, she was able to feed herself and put her hands to her hair, which she had not done for many years. In five months' time she was able to walk out of the ward of our institution to go home to her family. This was the first time her five-year-old child had ever seen her mother standing on her feet or walking. This pregnancy occurred after she was laid up from rheumatism and contributed greatly to aggravating it. At this point, we wish to refer to the chapter in which we discuss the relationship of pregnancy as an overload (Chapter 21) and pregnancy complications (Chapter 34). In about six months' time, this woman was doing all her household duties except the laundry work. At one time when we called on her, she was making berry pie. Figure 345 shows the dental conditions. Note that there has been a tendency to both alveolar absorption and to condensing osteitis. The mesial root of the lower left first molar is shown overgrown with bone which is distal to, and close beside, the lower left second bicuspid, with a curved root and surrounded by much condensed bone. Also note the condensing of the bone below the zone of rarefaction beneath the root of the lower left second molar. You will also note a small zone of rarefaction just above the imbedded root of the lower left first molar. This imbedded root was removed and was found to be covered by a full eighth of an inch of very dense bone. A section of it was removed by operation in order to expose the root, which bone was sectioned and is shown in Figure 346. While the bone is a compact homogeneous mass so far as trabeculæ and medullary spaces are concerned, the original trabecular structure can be traced, as shown in Figure 346-A. The medullary spaces had been filled in with a very compact bone, as shown. In Figure 346-D, a blood vessel is shown, the lumen of which has been so reduced in size that it is



FIGURE 314. CASE OF DEFORMING ARTHRITIS, BEDRIDDEN FOR FIVE YEARS, PROGRESSIVELY GETTING WORSE, SO GREATLY RELIEVED BY REMOVAL OF HER DENTAL INFECTION AND USE OF A VACCINE THAT SHE NOW DOES HER OWN HOUSEWORK AND HAS FOR SEVERAL YEARS. CASE NO. 896.

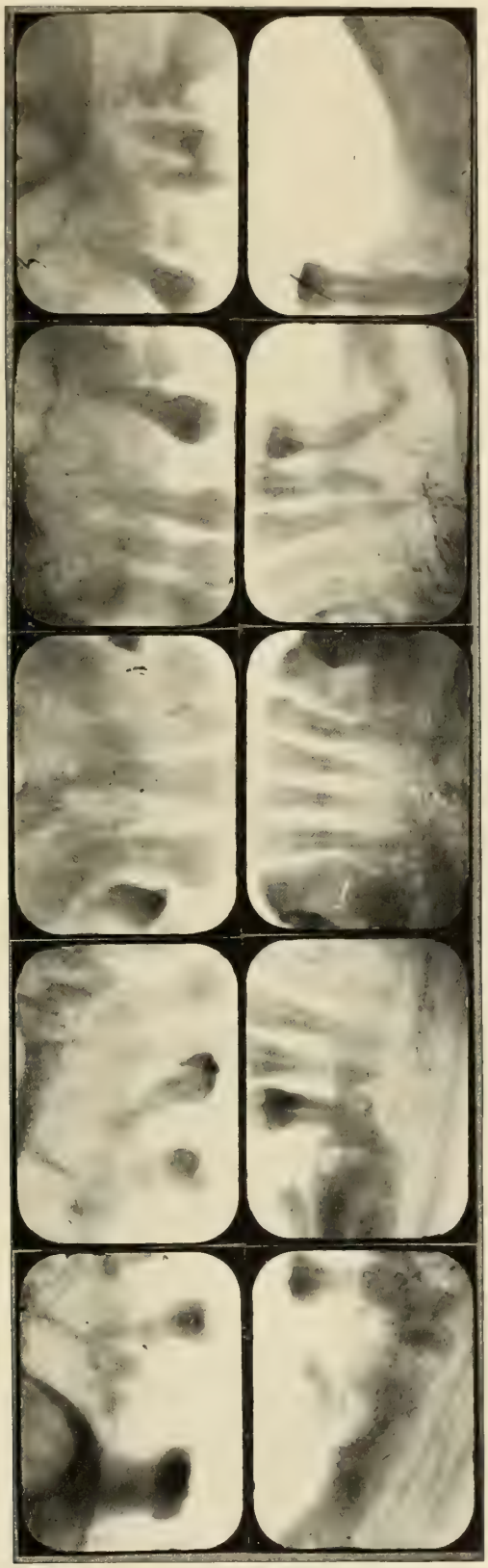

FIGURE 345. ROENTGENOGRAPHIC APPEARANCE OF TEETH OF PREVIOUS CASE. THIS PATIENT HAD THE DEGENERATIVE TYPE OF ARTHRITIS, NOT PROLIFERATIVE. NOTE DIFFERENCE IN ALVEOLAR CHANGES. AN OVERGROWN SEGMENT OF MESIAL ROOT OF LOWER LEFT FIRST MOLAR WAS UNCOVERED BY TREPHINING. THE BONE CHANGES ARE SHOWN IN NEXT FIGURE.

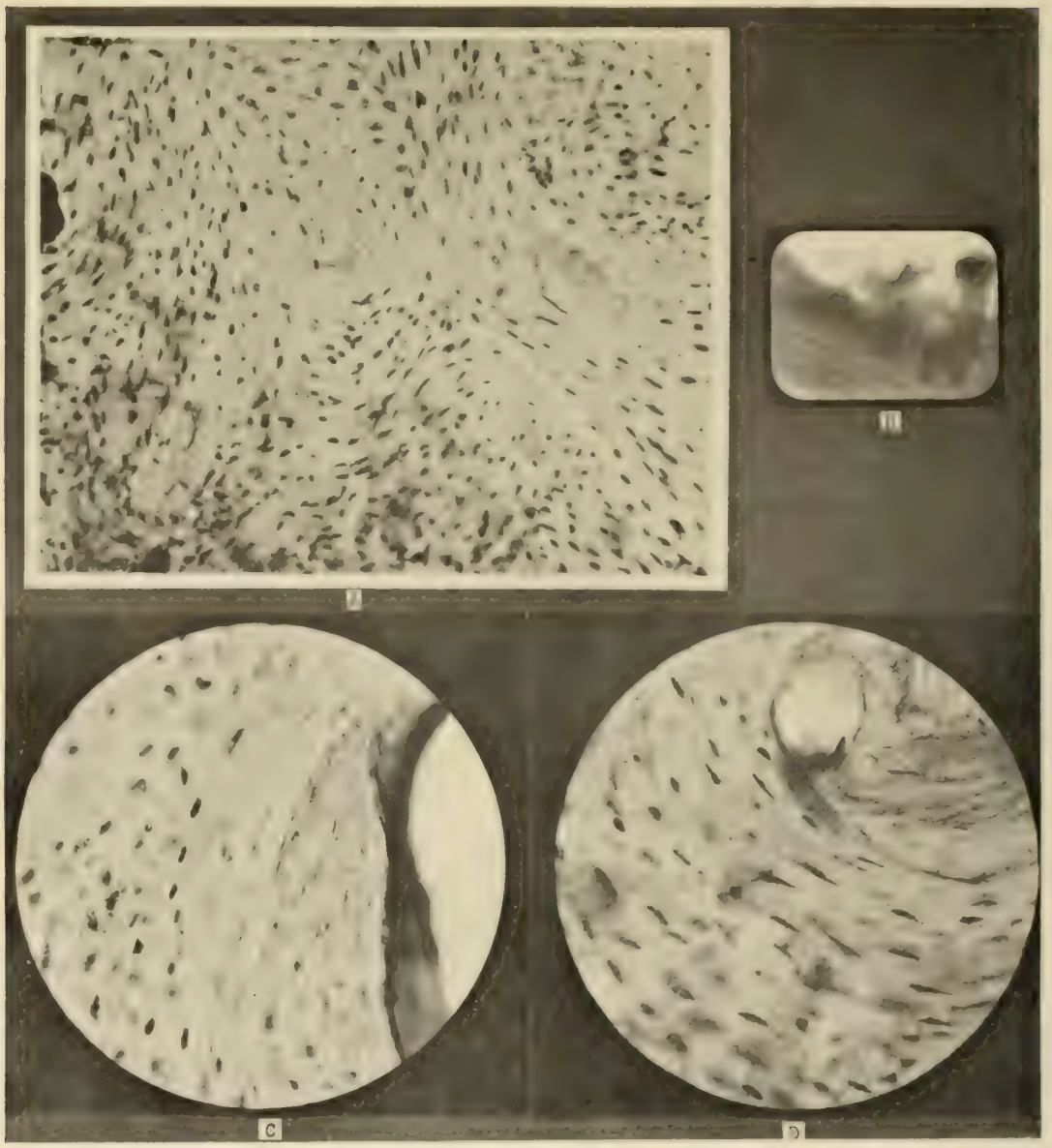

FIGURE 346. B, THE OVERGROWN ROOT REFERRED TO IN PREVIOUS FIGURE. A, SECTION OF BONE SHOWING ORIGINAL OUTLINE OF TRABECULÆ; C AND D, CONCENTRIC LAMINATION OBLITERATING A BLOOD VESSEL.

now but a fraction of its original cross section; and in Figure C, will be seen the successive layers of the laying down of bone within the lumen of a blood vessel. This root was cultured, the organisms growing from which were injected into rabbits, one of which, Figure 347, developed paralysis from the center of its spine backward, followed by a marked structural change, as shown in the roentgenograms, Figure 348. This rabbit lost complete control of the sphincters for urine and fæces for several weeks, and dragged

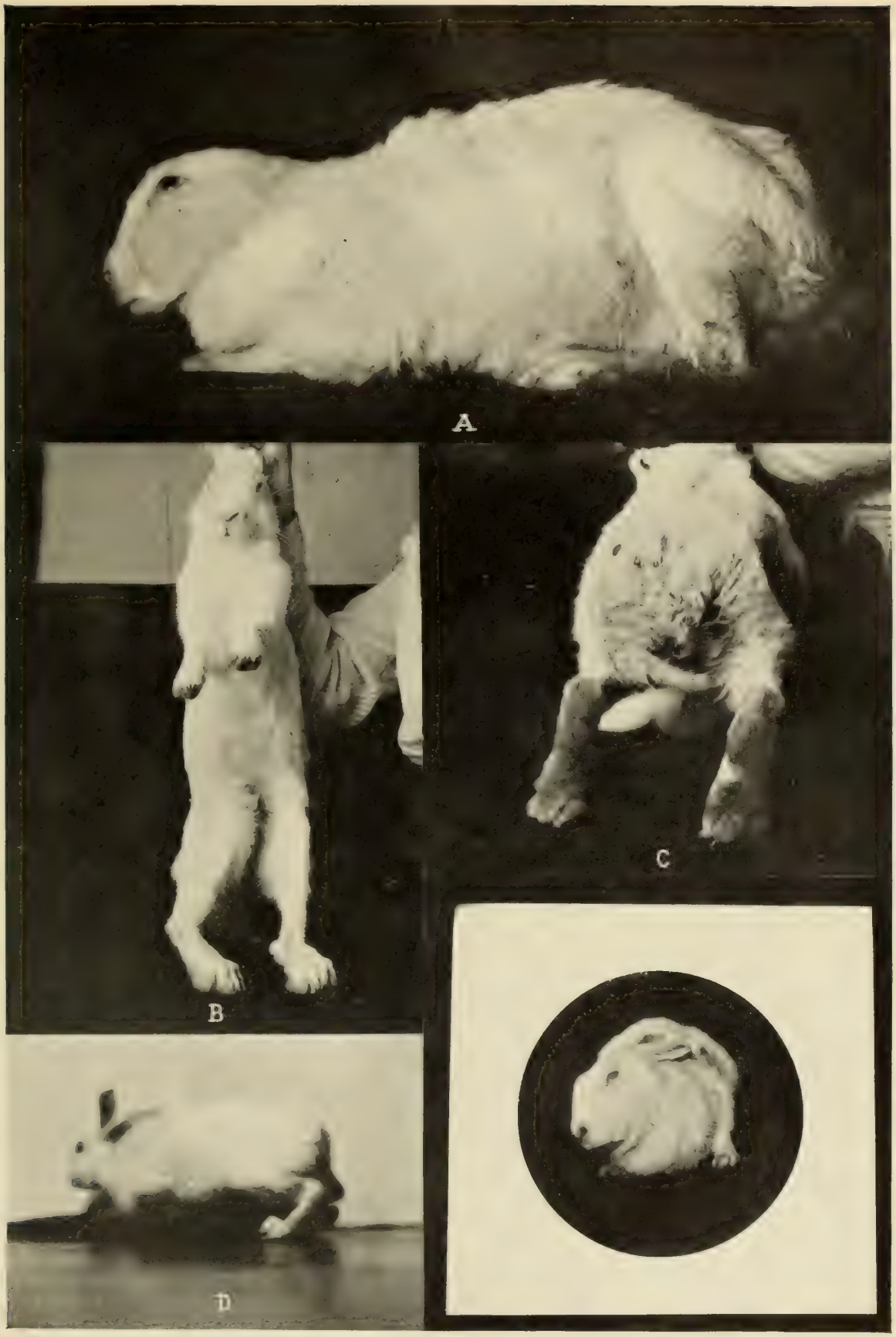

FIGURE 347. VARIOUS VIEWS OF A RABBIT PARALYZED BY AN INOCULATION FROM DENTAL CULTURE FROM PREVIOUS CASE, NO. 896.

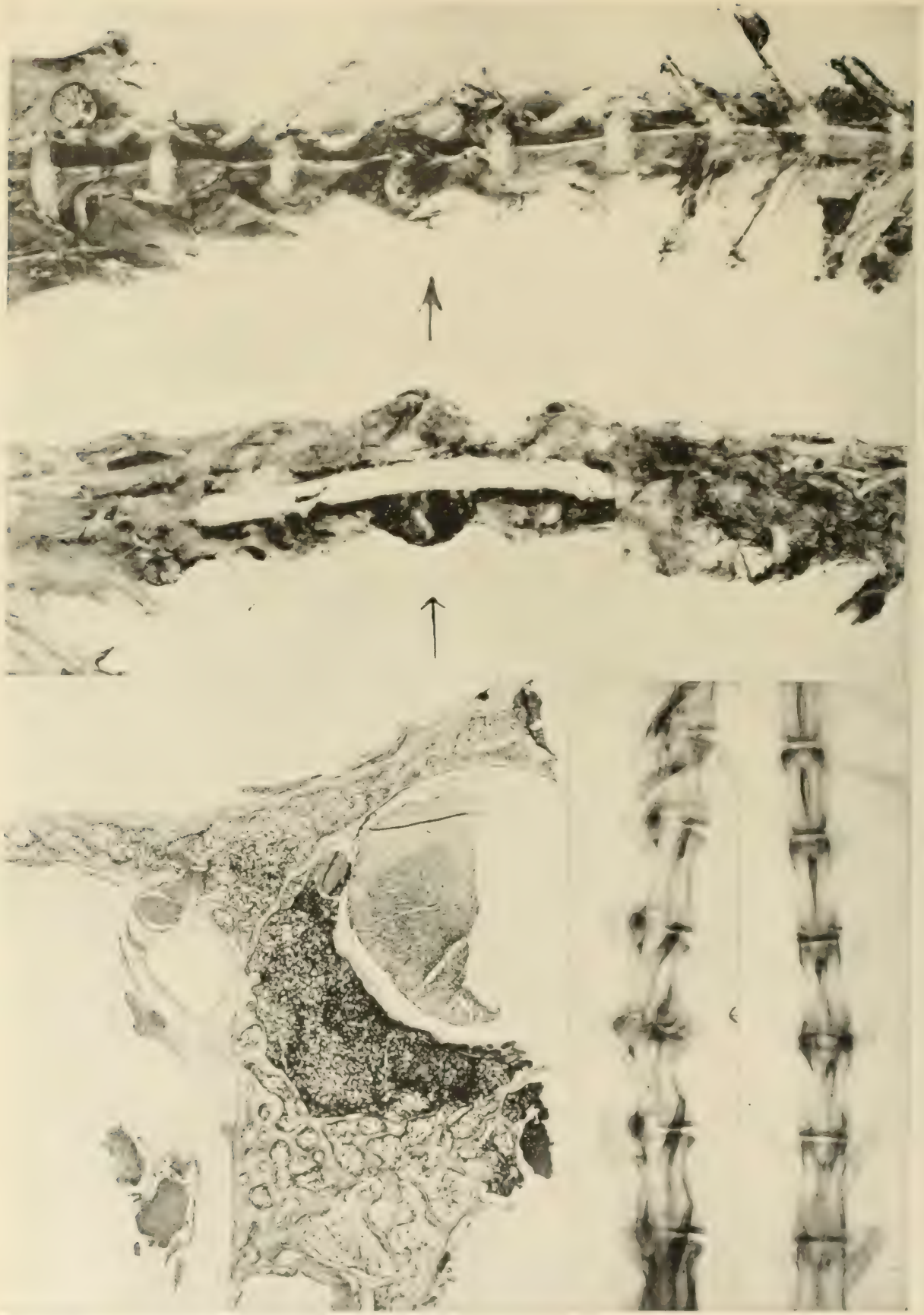

FIGURE 348. LESIONS OF SPINE OF RABBIT SHOWN IN FIGURE 347. A AND B, PHOTOGRAPHS SHOWING DISEASED VERTEBRÆ. C, DEGENERATIVE NECROSIS OF VERTEBRÆ ADJOINING THE SPINAL CORD. D AND E, ROENTGENOGRAPHIC APPEARANCE.

its hinder parts as though they were something foreign to it. It was not particularly sick, ate well, and made an apparently complete recovery except that it walked with difficulty, having a permanent impediment, similar to a child that has had infantile paralysis. We have motion pictures of this rabbit and many others in various stages. This rabbit is discussed in Chapter 21, in which it was used to study the effect of maternity on an apparently healed infection, with very striking results, as will be seen by that text. The structural changes in the vertebræ and spinal column are shown in cross section in Figure 348, our pathologist's report of which is as follows:

"*Inverted Ocular* shows a large, irregular-shaped piece of tissue, representing on one side bony tissue with its marrow and one side the spinal cord cut half. The cord stains with a pink color; the bony structure is stained with a reddish color, while the marrow is pale pink. In between the cord and the bony structure there is a large blood vessel, and next to this the marrow of the bone is of a muddy color.

"*Low Power.*—The cord proper tissue appears mushy, the nuclear structures are very few, with a large amount of the interstitial tissue, which appears more or less spongy, mushy. There will be seen many places where the neurogliar cells appear vacuolated, nuclei staining poorly. Same changes can be seen also in the gray matter. All the blood vessels at the periphery of the cord are well dilated and some filled with blood cells. In some instances there can be seen a few of what appear to be round cells, around the blood vessels. The spinal cord membranes are detached, somewhat thickened. The periosteal covering of the bony part of the vertebral column is thickened in some places and all the blood vessels are markedly dilated and filled with red blood cells. There appears to be a marked loss of bony tissue at the center where the spinal cord is in contact with the bony structure, a condition of bone resorption present; the bone marrow is increased in amount, likely due to the loss of bony tissue; otherwise, the marrow tissue proper appears rarefied, loss of cellular structures, and takes a darker stain. Everywhere there are many dilated blood vessels in the marrow. In other places the marrow tissue has nearly disappeared, only a few cells left. Those spaces between the bony structures stain with a very light bluish stain.

"*High Power* shows the same changes as above.

"*Diagnosis.*—Chronic osteomyelitis of the vertebral column (lumbar region) with degeneration (parenchymatous) of the spinal cord."

This patient had been progressively getting worse with recurring exacerbations from which she suffered severely. She has been almost completely without pain since very shortly after the teeth were extracted and is progressively improving. We have motion pictures of her doing stunts and she is shown in Figure 344. To those dentists who have not found a supremely compensating joy in the practice of dentistry, we would suggest that the satisfaction of having been able to assist even one mother like this (of whom we have had many,) so that she has been enabled to go back to her home and carry on the duties of the household, and mother her several children, is sufficient to compensate for a lifetime of effort and in a way that no monetary consideration can reward. Unfortunately, a large number, if not a large per cent, of these individuals are financially incompetent even to take care of the incidental expense, let alone remunerate.

Diagnostic and Prognostic Interpretation.—A study of this woman's history shows that her first attack of rheumatism began following childbirth, fifteen years prior to her coming to us. She had another attack following the birth of her second child eight years preceding. She was unable to walk for a period after her attack of arthritis which followed her first childbirth fifteen years ago, and again with an attack that occurred after the birth of a child eight years ago. Each of her six pregnancies has been followed by acute rheumatism. The history further shows that her mother suffered from rheumatism and died of pneumonia at fifty-nine. Her one brother died at thirty-nine of heart involvement. Her only involvements have been rheumatism and arthritis. Figure 349 shows the marked disfigurement of the hand, due to the shortening of the flexor and adductor muscles.

While it is too early to differentiate between the pathology or the etiology of these different types of arthritis, as shown in the last three cases, we wish to note that the last patient studied is of the degenerative type, while the two preceding are the proliferative type. In the experimental chapters I have shown many different phases of disfunction of tissues and organs which seem definitely to be related to calcium metabolism. The fact, that patients with the proliferative arthritis tend to have a lowered ionic calcium at the time of the active process, whereas those with the degenerative arthritis tend to have a higher than normal ionic calcium, strongly suggests that the process is not primarily one of a quantitative presence of either calcium or ionic calcium, but of its availability and utility in the process of metabolism. In



FIGURE 349. DEGENERATIVE ARTHRITIS OF HAND OF PATIENT, CASE NO. 896, WITH DISLOCATION DUE TO SHORTENING OF FLEXOR AND ADDUCTOR MUSCLES.

Chapter 43 I have shown that the available calcium in ionic form is largely dependent upon the demands made upon it for neutralizing improperly reduced acids, which substances normally should not exist in the blood and body fluids in a perfect metabolic state, nor should their neutralization use up the available ionic calcium so requisite for metabolic processes.

But if there is a pathos in the development of deforming arthritis of adult life, it is doubly a tragedy if both the childhood and adult life are clouded by this misfortune. In the chapter on heredity, we emphasized that in cases of marked hereditary susceptibility from both sides, the affection tended to develop, not only more strongly, but earlier in life in the offspring. A striking illustration of this is seen in the following case.

Case No. 381.—Figure 350 shows the patient as he appeared at seventeen years of age when we were called to see him at the hospital. At that time, his mother said to me repeatedly that she believed she would be the happiest mother in the world if she could see her suffering child die and end his misery, for he cried by



FIGURE 350. ACUTE DEFORMING ARTHRITIS IN BOY SEVENTEEN YEARS OF AGE, BEDRIDDEN MUCH OF THE TIME FOR FOUR YEARS AND CRYING BY THE HOUR WITH PAIN. ALMOST COMPLETE ABSENCE OF ALVEOLAR ABSORPTION ABOUT PUTRESCENT TEETH. CASE NO. 381.

the hour from acute pain, and was mere skin and bone. The extreme deformity of his hands is shown in the picture. His history showed that there had been very acute rheumatism on both his father's and mother's sides. His father died at fifty-six from cerebral hemorrhage, from which affection both the father's father and mother died. One of the father's brothers died of



FIGURE 351. SAME BOY AND SOME OF HIS HANDIWORK, NOW GREATLY IMPROVED BUT DEFORMED FOR LIFE. IS HE HAPPY?

heart, one of heart and rheumatism, and two had rheumatism severely. The mother's father had very severe rheumatism, as did also the mother's sister. The boy's father was an invalid as a young man. This boy's acute rheumatism began at four years of age and he was in bed for eight months. Another attack at five years of age made him bedridden again for many months. At seven years of age, he fell through the ice into ice cold water and before he could get his clothes off, his trousers froze on him. This severe exposure was followed by severe rheumatism which lasted for one year. His right leg was drawn up. It became rigid. At nine years of age, he learned to ride a tricycle, which took the stiffness out of both limbs. During the ninth year, he had both scarlet fever and measles, after which his rheumatism reoccurred. His attacks of acute rheumatism were preceded by acute nausea. At about twelve, when trying to fly a kite, he sat in his stiffened condition on the damp ground, which exposure was followed by pneumonia and acute rheumatism. At twelve years of age, he was carried to a dentist with severe tooth-ache. A devitalizing paste was placed in the tooth to devitalize the pulp. The boy was so frightened and hurt that he did not go back. The dentist warned him that the medicine should be removed, but it

was not done. The mother states that the dentist told her that if the medicine was left in the tooth, it would rot every bone in his body. Owing to his fear, she could not persuade him to go back. After this incident his arthritis was progressively worse. At the time we took his case it was at the request of the hospital staff as they suggested they were at the limit of their resources and he was receiving morphine to control his pain. He was entirely helpless and had to be fed through a tube or with a spoon, the ankylosis of the mandible being so complete that nothing thicker than a spoon handle could be placed between the teeth. We took him to the x-ray room and made roentgenograms of his teeth, with very great difficulty, since films could only be placed flat between the two incisal planes. These poor and distorted pictures were sufficient, however, to give much important evidence, as shown in the inserts in Figure 350. The most striking thing is that, while several of these teeth had such extensive caries, that the pulps had been exposed for a long time and were putrescent, there was exceedingly little evidence of apical rarefaction and none of his teeth were sore or had been painful. Seven were non-vital. He was placed under a general anæsthetic and with exceeding difficulty the non-vital teeth were removed. The ankylosis of the mandible was so severe and rigid that it was impossible to open, even by force under the anæsthetic, for fear of fracturing the mandible. All extractions had to be done through the alveolar border, and the teeth were surrounded with much condensing osteitis. The incisors and bicuspids could be reached, but it was with great difficulty that the roots of the first permanent molar, upper left, could be reached. A tendency to cyanosis and to ceased breathing kept the anæsthetist and myself in the most extreme anxiety, and several times the operations had to be temporarily stopped to resuscitate the patient. The buccal roots of this molar were found very close to a very low maxillary sinus, as shown. The fact that his mouth could not be opened, made the operation almost impossible, both because of the difficulty of access and of maintaining anæsthesia. Following this operation, he made most remarkable improvement for a few weeks, when he had a new attack of acute rheumatism in his left ankle, which was the only important joint that had not been seriously crippled. Because of the difficulty of taking care of him in a general hospital which is not adapted either in its equipment or in the training of its nurses for the care of these special dental cases, we trans-



FIGURE 352. RABBIT WITH ACUTE RHEUMATISM, INOCULATED WITH A CULTURE FROM A PUTRESCENT LATERAL SHOWN IN B. NOTE THE NEARLY COMPLETE ABSENCE OF APICAL ABSORPTION.

ferred him to a private room, four miles nearer the office, from which we could conveniently carry him to the office surgery for care and treatment. (We did not then have a private dental hospital with specially trained nurses, which we do now.) He was coming to know some of the thrills of a boy's heart. Some of his joints, particularly his knees, were so severely ankylosed as to be almost entirely rigid, one completely so. His improvement since that time has been nearly continuous except for a setback from pneumonia during the past winter. He rolls himself about in a wheel chair, sells confections and papers, and does remarkable carvings, some of which are shown beside him in Figure 351. He has made with his jacknife and handsaw, the aeroplane and pistol which, with its coat of aluminum paint, is so realistic that he came nearly being arrested for carrying firearms. The handkerchief

Private Records of Weston A. Price, M.S., D.D.S., 8926 Euclid Avenue, Cleveland, Ohio

Form No. 14 Serial No. 381

RESISTANCE AND SUSCEPTIBILITY CHART

PATIENT R.L.R Case No. 381 AGE 20

ADDRESS DATE 4-4-21

CHIEF COMPLAINT Multiple Deforming Arthritis

Present Illness	Past History	Rheumatic Group Lesions and Complications	Own: Brothers	Own: Sisters	Own: Sons	Own: Daughters	Own: Husband or Wife	Father's Side: Father	Father's Side: Grandfather	Father's Side: Grandmother	Father's Side: Uncles	Father's Side: Aunts	Mother's Side: Mother	Mother's Side: Grandfather	Mother's Side: Grandmother	Mother's Side: Uncles	Mother's Side: Aunts	Years
		No.	1	2							4	3						1
	+?	Tonsillitis		#									#					2
##	##	Rheumatism		+?				#		(#)			##				#	3
##	##	Swollen or Deformed Joints																4
##	##	Neck-back or Shoulders																5
		Lumbago																6
#	##	Neuritis																7
		Sensitizations																8
		Sciatica																9
		Chorea or St. Vitus's Dance																10
		Nervous Breakdown																11
		Mental Cloud																12
		Persistent Headache																13
+	##	Heart Lesions																14
		Dropsy																15
		Kidney Lesions, Brights																16
		Liver or Gall Lesions											#					17
		Appendicitis																18
##	##	Stomach pain or Ulcer											#					19
		Eye, Ear, Skin, Shingles																20
		Pneumonia		#														21
		Anemia																22
		Goiter																23
#	##	Lassitude, Chilliness																24
		Hardening of Arteries																25
		Stroke						(#)	(#)	(#)								26
		Age at Living												80				27
		Age at Death						56	82	70								28
		Flu with Complications																29
		Flu without Complications																30
																		31
																		32
																		33
#	#	Extensive Tooth Decay																34
#	#	Abscessed Teeth																35
		Loosening Teeth																36

Duration of Focal Infection

Duration of chief Affection

KEY FOR CHART: + HAD LESION; # FREQUENTLY; #VERY SEVERELY; +? PROBABLY; * OPERATION; ⊕ FATAL ATTACK

D. FOCUS TEETH: CARIES # | LOOSE # | CONDSNG # | SL. HG. #; PYRRH | OPEN | REATNG | RA HG

SYST. RELT. | COMP. | PART. # | RECR. | NONE

SUSC. TREL. | INHT. ## | ACQD. | ABSL. | SC. NO

FACTOR OF SAFETY: V. HG. | HIGH | FAIR | LOW | V. LW. ##

FIGURE 353. SUSCEPTIBILITY OF THE PRECEDING CASE, NO. 381. NOTE DOMINANCE OF RHEUMATISM ON BOTH SIDES OF FAMILY.



FIGURE 354. ROENTGENOGRAPHIC VIEW SHOWING THE FREE MOVEMENT OF MANDIBLE WHICH BEFORE DENTAL EXTRACTIONS WAS ANKYLOSED CLOSED.

box is also a remarkable evidence both of his genius and of his wonderful dexterity with hands that previously were so stiff that he could not hold a pencil or spoon.

Our first surgical operation on his case occurred about five years ago. The mandibular ankylosis entirely disappeared. He returned to the South and we did not see him for a couple of years. He came back two years ago, at which time he was having some return of his rheumatism. He had had no further care of his mouth and was wearing a denture with which we replaced the missing teeth. A lateral was found with deep caries, with a pulp non-vital, but without periapical absorption of such extent and type as would be expected with this amount of infection, as shown in Figure 352. The culture was taken from the pulp of this tooth and inoculated into a rabbit which developed very acute rheumatism and is shown in Figure 352 with its right hind leg drawn up and which it carried when it hopped.

DIAGNOSTIC AND PROGNOSTIC INTERPRETATION.

The susceptibility chart for this boy is shown in Figure 353. We would consider, as shown, that his factor of safety is very low for he has by inheritance a marked susceptibility, in which condition his best will always be low. Since each attack of streptococcal infection, such as rheumatism, heart, etc., seems to make the individual ultimately more susceptible, he has, in addition to his inherited low defense, an increased acquired susceptibility, and every new infection of this type will tend to bring about a recurrence of the old symptoms. We have no thought that he ever can be a normal man, but he is happy to be free from pain and to have even the joys that a boy can have with his companions, with his pictures, and his business, for he has at last become an asset to his mother whose chain of misfortunes had left her completely destitute and who could not leave him for an instant to go to earn. But he has come to be one of the happiest souls you could meet, for everything in this world is by contrast. The improvement in his mandibular articulation is practically complete, as illustrated by the roentgenogram of his head showing the mouth open. Figure 354.

OSTEOMYELITIS.

In Chapter 3 we have discussed the different types of bone lesions produced by streptococcal infection of dental origin and presented cases and also rabbit tissues illustrating the different

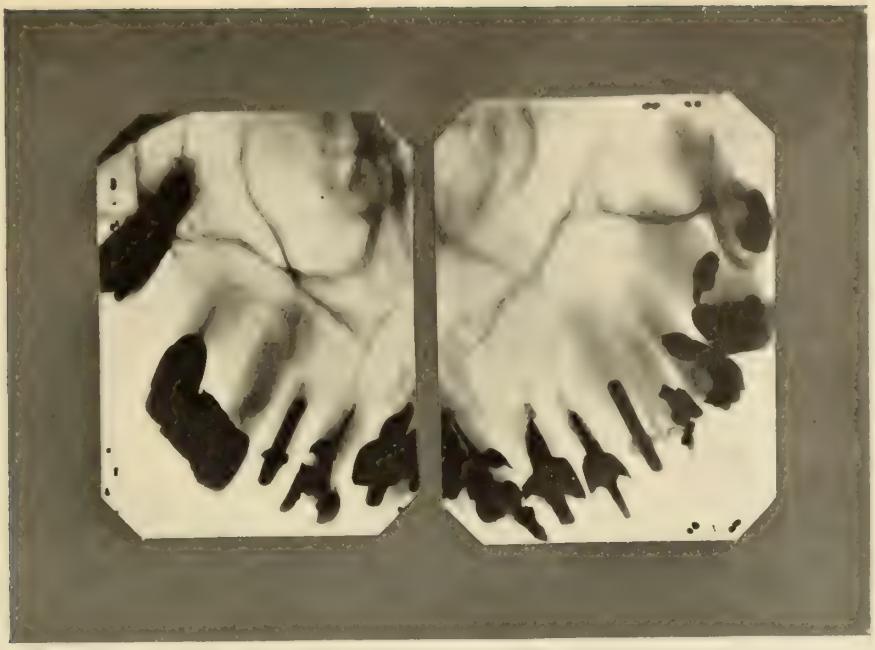

FIGURE 355. EXTREME EXCEMENTOSIS. CASE 311 WITH CARDITIS.



FIGURE 356. OVERGROWN BICUSPID ROOT OF CASE 311.

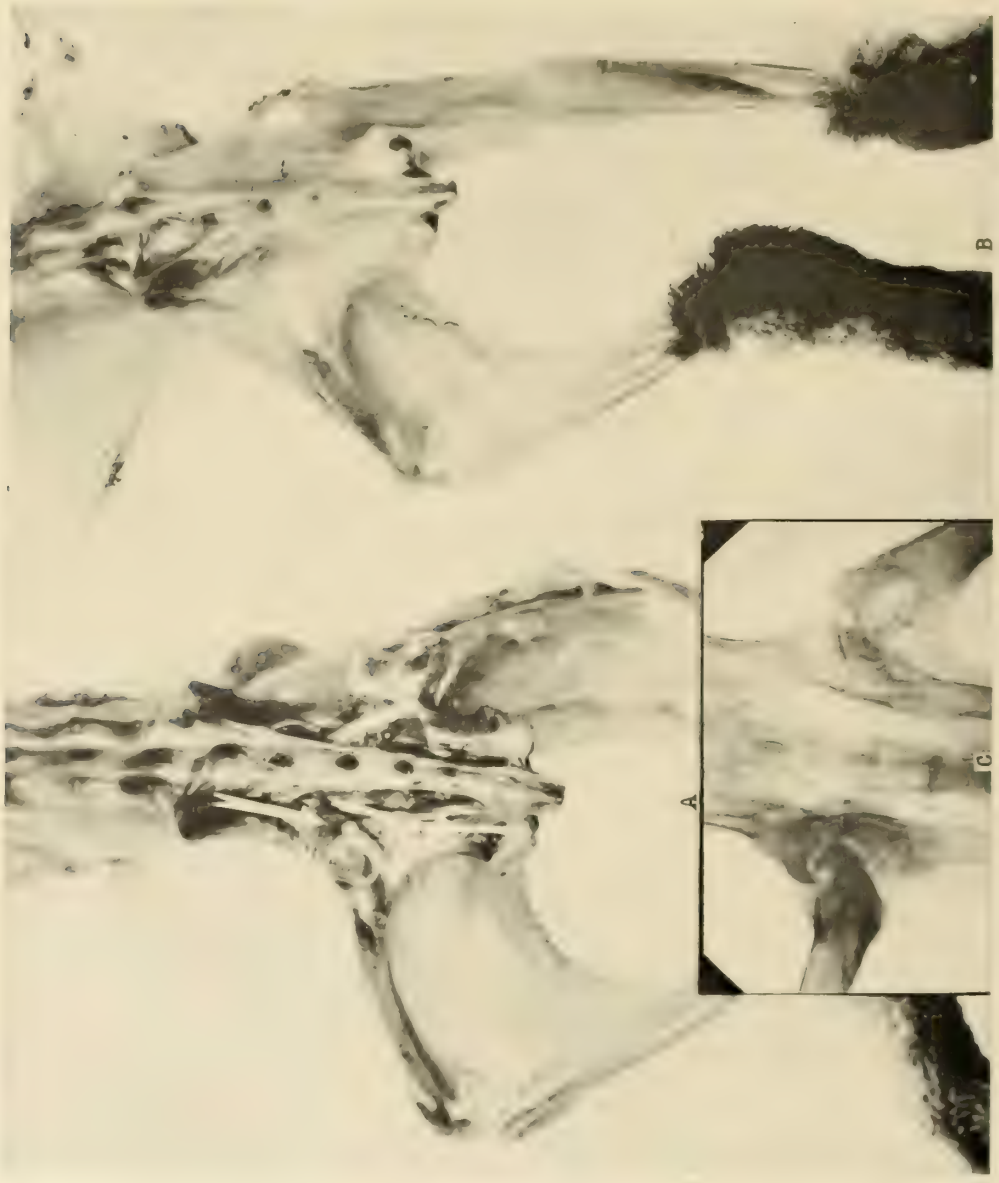

FIGURE 357. OSTEOMYELITIS IN A RABBIT'S HIP, PRODUCED BY THE CULTURE FROM THE OVERGROWN ROOT TIP SHOWN IN FIGURE 356.

types. We present here, under skeletal and muscular system studies, the history of a case and result of animal inoculation as a matter of interest and information.

Case No. 311.—The patient, at the time of this writing seventy-one, has had recurring attacks of rheumatism with very severe cardiac disturbance, extending over a period of several years. The appearance of the structural changes, as revealed in the roentgenograms of the teeth, is particularly instructive. These are shown in Figure 355. Note the very extensive excementosis. This type of local reaction is very important. We have discussed the significance of this type of pathology in other chapters and would stress here the clinical rather than the histopathology. This patient did not suffer from marked rheumatism or from joint lesions with deposits. The root shown in Figure 356, left after a difficult gas extraction, made at the time she was suffering from a severe heart involvement, was cultured internally and the strain injected into rabbits. One of these is shown in Figure 357 with marked osteomyelitis. In A the flexed position of the limb is shown. The animal carried it and the limb seemed painful to touch. B shows the mechanical displacement of the sciatic nerve, due to the swelling. It also shows the femur with the destruction of the shaft and part of the head. C shows a roentgenogram of both femurs with the partial destruction of the head of one femur and the zones of rarefying and condensing osteitis. Figure 361 shows a longitudinal section through a zone of osteomyelitis.

MYOSITIS.

While neck and shoulder involvements are among the most frequently found lesions related to dental infection, they are very largely nerve involvements. Some of them, however, have very definite myositic lesions. This may take the form of torticollis with a simple muscle spasm, or with petechial hemorrhages in the muscles, with or without considerable local infection. In the latter form the involvement is very painful and slow of recovery. Some of the most striking lesions, produced in our animal inoculations, have been the reproduction of neck involvements with the culture taken from dental infections of patients suffering from acute neck involvements. This will be illustrated in the following case.

Case No. 455.—This is the case of a woman fifty-seven years of age. Some years ago she had the roots of a broken tooth smoothed off and a plate was extended over them. These roots became in-

fected and with the pressure of the plate, which prevented the drainage from the suppuration around the teeth, this infection was forced more or less directly into the tissues in the circulation. During a period of two years a neck involvement developed with recurring and increasing severity until it finally became so severe that she was compelled to sit in a chair for eight days and nights, not able to lie down because of the extreme pain and discomfort. Because of her weakness the roots were extracted under a general anæsthetic. They were cultured and animals were inoculated. Several of these rabbits developed myositis. In order to determine whether the infection in the muscle tissue corresponded with that in the tooth, a local anæsthetic was used in the neck and a piece of the trapezius muscle removed, both for section and for culture. Great care was used in removing the tissue without contamination. The section of muscle, about five millimeters square, was removed, one-half of which was ground in sterile sand and inoculated into culture media. The other half was sectioned and is shown in Figure 358. In this section there will be seen streptococci in diploid and chain form within the sheath of the muscle fibres which are seen in cross section. The culture grown from the tissue was inoculated into a group of rabbits, several of which developed myositis and two of the rabbits showed marked neck involvements. A was inoculated with the culture from the tooth and B was inoculated with the culture from the muscle. We have motion pictures of several of these rabbits which, at one time, had marked involvement of neck muscles with their heads turned sideways and with serious nervous disturbances. The patient's condition improved promptly and completely after removal of the infected roots, and she had no return of these or similar symptoms for two years, when suddenly the condition developed in her neck on the opposite side, the right side. At this time, infection was found in the pulp of an infected molar, the pulp being invaded by caries underneath an old gold crown carrying a bridge, shown in Figure 359. With the removal of this infection, her neck involvement ceased completely within twenty-four hours and she was again free from infection for approximately two years at which time she developed symptoms again in her neck and swelling in her left hand, as shown in Figure 360. A putrescent pulp was found in the lateral shown in Figure 360-B, and the extent to which the rarefying osteitis extends behind a condensing osteitis is illustrated by

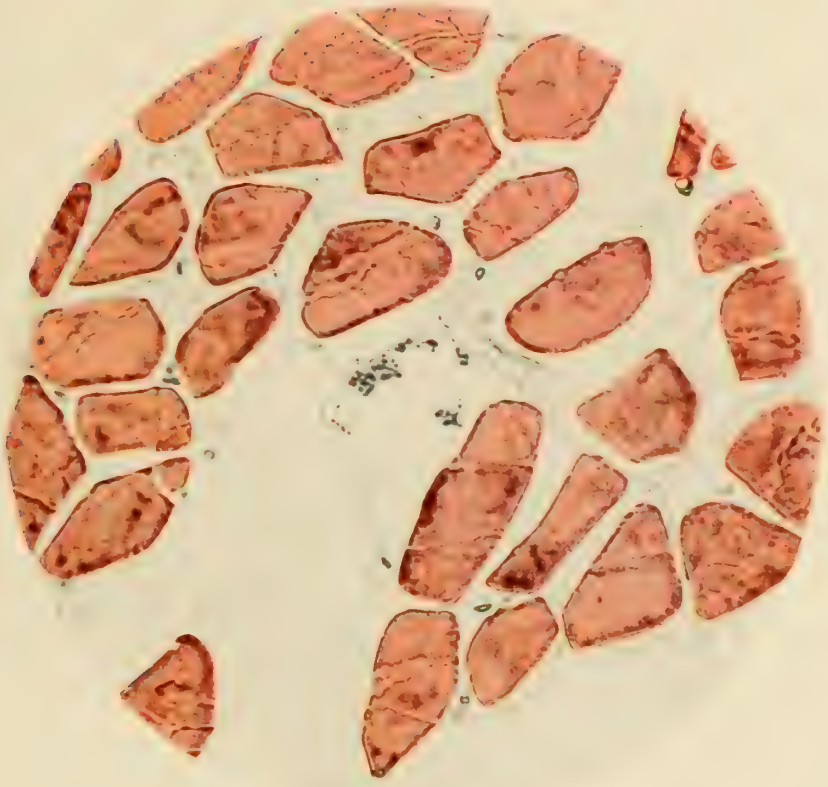

FIGURE 358. A CROSS SECTION OF MUSCLE FIBERS WHICH WAS DISSECTED FROM THE TRAPEZIUS MUSCLE OF THE NECK OF A PATIENT WITH ACUTE TORTICOLLIS, WHICH SHOWS THE STREPTOCOCCI AND DIPLOCOCCI WITHIN THE SHEATH OF THE MUSCLE FIBER. CASE NO. 455.



FIGURE 359. ROENTGENOGRAPHIC APPEARANCE OF A TOOTH WITH CARIES BENEATH A BRIDGE WHICH TWO YEARS LATER PRODUCED TORTICOLLIS ON OPPOSITE SIDE OF NECK OF CASE 455.



FIGURE 360. ABOUT TWO YEARS LATER, PATIENT AGAIN SUFFERED FROM TORTICOLLIS AND RHEUMATISM. B SHOWS PUTRESCENT LATERAL INCISOR APPARENTLY PRODUCING SAME; A, THE PATIENT'S SWOLLEN WRIST JOINT. D AND E, RABBITS WITH SWOLLEN FEET AND JOINTS WITH ACUTE RHEUMATISM, INOCULATED WITH CULTURE FROM PUTRESCENT LATERAL. C SHOWS A LEAD BAR IN THE TOOTH SOCKET. NOTE THE DECEPTIVE APPEARANCE OF APICAL AREA OF LATERAL IN B.



FIGURE 361. OSTEOMYELITIS PRODUCED IN RABBITS FROM CULTURE FROM TOOTH IN PREVIOUS FIGURE: A, NORMAL; B, PATHOLOGICAL; C, SECTION NORMAL; D, SECTION PATHOLOGICAL

the lead wire placed in the alveolus after the extraction. Rabbits inoculated with the culture from this tooth developed acute rheumatism so that they carried a foot or hopped with great difficulty. Two of these are shown in D and E. One of these rabbits would cry with pain when the other rabbits in the cage would crowd it, making its rheumatic infection painful. There was no tendency to depositions in the joints of the patient; and the infection, when placed in rabbits, tended to produce an osteomyelitis, a striking illustration of which is shown in Figure 361, A normal, B diseased, C sectioned normal, and D sectioned diseased femur.

In the cases of this and the preceding chapters, discussing the practical cases, we have given the detailed history of the case and the findings, including animal reactions first, and then followed these with the physical and susceptibility studies. Let us reverse this order and proceed as we would were the patient presenting for study.

Case No. 1081—The case in question, a woman forty-two years of age, presents very much underweight with the complaint of acute pain in the right shoulder just below the inner lower border of the scapula, which had been troubling her for about five years and which, at times, during the past two years, was so severe that she had to have medical aid on different occasions. She has also been troubled with headaches. The problem is: Are her teeth probably related to her disturbance, and what are the prospects of improvement from interference or surgical procedure in that line? One of the first steps of course, is complete roentgenograms and the making of the susceptibility chart which is shown in Figure 362. It will be noted that her pain in the shoulder and headaches have been the chief disturbances. She has had three brothers and two sisters, one brother having had rheumatism. Two brothers and one sister died of tuberculosis. Her father and mother are both living, the former seventy-two and the latter sixty-nine. The father has diabetes. The mother has had excellent health and has not been afflicted with any of the rheumatic group lesions. Her father has had some kidney and digestive tract disturbance, but no neuritis or rheumatism or headache in the father and his three brothers and three sisters, or the mother and her two brothers and one sister. It, therefore, is not a family characteristic. The roentgenograms of her teeth,

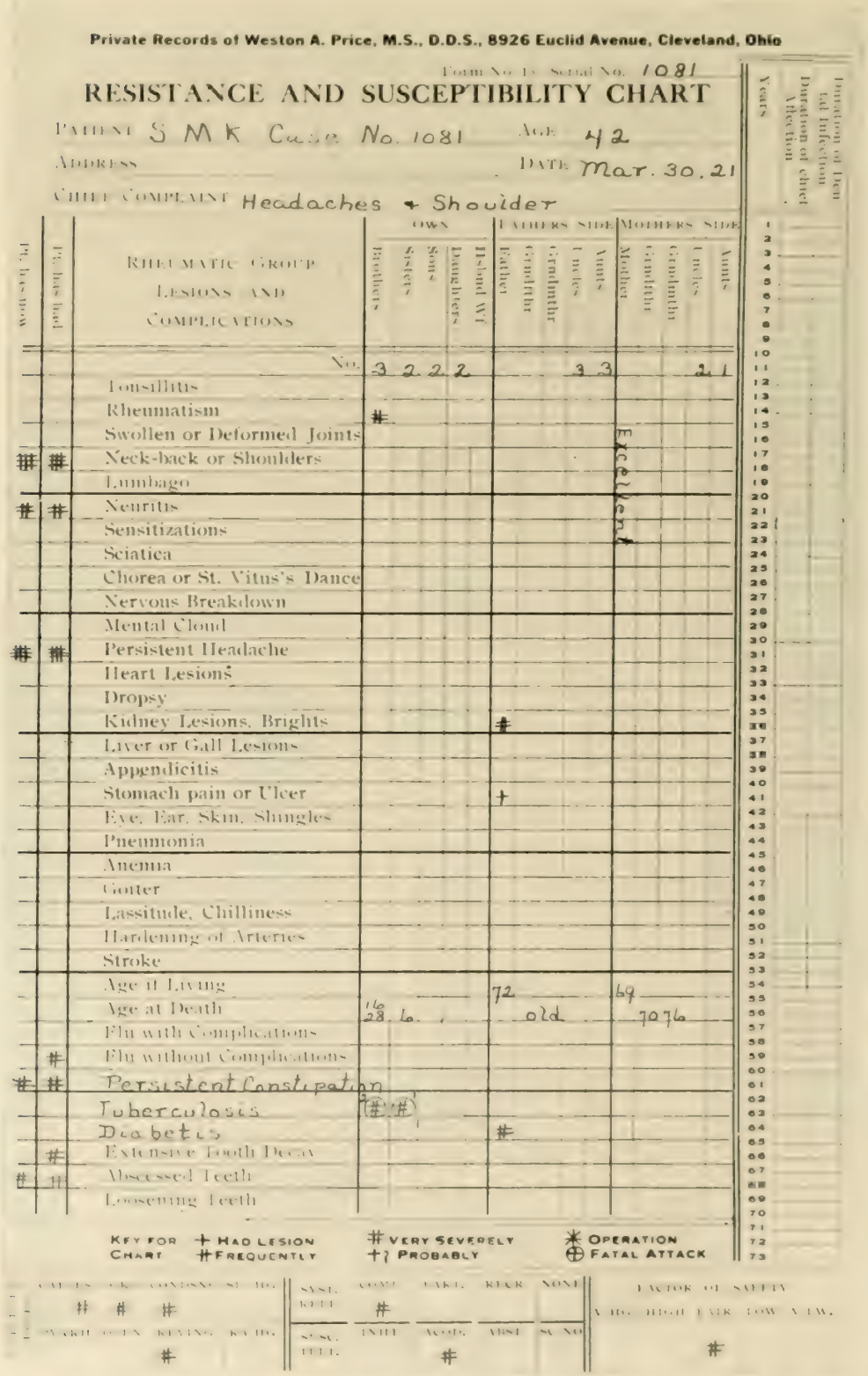

Private Records of Weston A. Price, M.S., D.D.S., 8926 Euclid Avenue, Cleveland, Ohio

Form No. 1 Serial No. 1081

RESISTANCE AND SUSCEPTIBILITY CHART

PATIENT S M K Case No. 1081 AGE 42

ADDRESS DATE Mar. 30, 21

CHIEF COMPLAINT Headaches + Shoulder

Duration of Dental Infection

Duration of chief Affection

Years

Pt. has had	Pt. has had	Rheumatic Group Lesions and Complications	Own: Brothers	Own: Sisters	Own: Sons	Own: Daughters	Own: Husband Wf	Fathers Side: Father	Fathers Side: Grandfthr	Fathers Side: Grandmthr	Fathers Side: Uncles	Fathers Side: Aunts	Mothers Side: Mother	Mothers Side: Grandfthr	Mothers Side: Grandmthr	Mothers Side: Uncles	Mothers Side: Aunts
		No.	3	2	2	2					3	3				2	1
		Tonsillitis															
		Rheumatism	#														
		Swollen or Deformed Joints											Excellent				
##	##	Neck-back or Shoulders															
		Lumbago															
#	#	Neuritis															
		Sensitizations															
		Sciatica															
		Chorea or St. Vitus's Dance															
		Nervous Breakdown															
		Mental Cloud															
##	##	Persistent Headache															
		Heart Lesions															
		Dropsy															
		Kidney Lesions, Brights						#									
		Liver or Gall Lesions															
		Appendicitis															
		Stomach pain or Ulcer						+									
		Eye, Ear, Skin, Shingles															
		Pneumonia															
		Anemia															
		Goiter															
		Lassitude, Chilliness															
		Hardening of Arteries															
		Stroke															
		Age at Living						72					69				
		Age at Death	16 28 6.					old					1976				
		Flu with Complications															
	#	Flu without Complications															
#	#	Persistent Constipation															
		Tuberculosis	(#) #														
		Diabetes						#									
	#	Extensive Tooth Decay															
#	#	Abscessed Teeth															
		Loosening Teeth															

KEY FOR CHART: + HAD LESION; # FREQUENTLY; # VERY SEVERELY; +? PROBABLY; ✱ OPERATION; ⊕ FATAL ATTACK

CALCIUM IN CONSTANT SUPPLY: # # #

SYMPTOMS IN KEEPING WITH: #

SYSTEMIC KEEP: SUSCEPTIBLE:

CONST. INFECT: #

EARLY ACCOMP.: #

REACT. FIRST:

NONE SUCCUMB:

FACTOR OF SAFETY: X HIGH HIGH EVER LOW X LOW: #

FIGURE 562. SUSCEPTIBILITY STUDY OF CASE 1081. NOTE ABSENCE OF INHERITED SUSCEPTIBILITY FACTORS.

Figure 363, indicate that much dental work has been done. There are two gold crowns with long standing apical involvements and no periodontoclasia. None of these teeth are painful or uncomfortable. An analysis of the oral pathology and systemic susceptibility, which is shown on the bottom of the susceptibility chart, (Figure 362) shows as the dental infection types a previous tendency to caries, locked and condensing osteitis, also rarefying osteitis; the systemic relief after dental operation—complete; classification of susceptibility—acquired, factor of safety—fair. A more careful study of the roentgenograms, shown in Figure 363, will reveal that the long standing apical involvements which earlier in life had expressed themselves in extensive rarefying osteitis, as shown particularly in the upper right second bicuspid, right central, upper left first bicuspid, lower left first bicuspid, lower right molar, have been followed by the development of a zone of condensing osteitis. (See particularly the upper right second bicuspid and upper left second bicuspid, also shown other places in less marked degree.)

What diagnosis and prognosis are suggested (by these data) on the presumption that the data herewith presented and the basis of interpretation are based upon fact? My interpretation of this case on this information is as follows: Her normal defense by inheritance should be expected to be high and there is evidence that it was high until recent years. Her overloads have been the raising of her family of four, two of whom were twins, the two pregnancies following closely. This woman's classification in regard to inheritance is acquired, and my investigations have shown (See Chapter 4) that when individuals with normally a high defense for rheumatic group lesions do break because of a combination of dental infections and overload, of which the dental infections may be a very large part, the break tends to be in the nervous system. We have also shown that when people with an acquired susceptibility, whose defense normally should be high, have their overloads removed, when they are chiefly dental infections, they tend to rebound splendidly; in other words, the prognosis is particularly good. These conditions must always be considered in conjunction with all other factors, one of the very important of which is the menopause in women. The structural changes about the roots of her teeth suggest that she has changed from a condition of good reaction at the apices to one of poor reaction, the former being an expression and therefore somewhat of a measure of the activity of the extent of some of the processes



FIGURE 363. ROENTGENOGRAPHIC APPEARANCE OF TEETH OF CASE 1081. NOTE ZONE OF CONDENSING OSTEITIS SURROUNDING RAREFYING, PARTICULARLY OF UPPER RIGHT SECOND BICUSPID, CHARACTERISTIC OF A HISTORY OF A BROKEN HIGH DEFENSE. PATIENT SUFFERING FROM ACUTE PAIN AND LAMENESS IN RIGHT SHOULDER.

and the completeness of the quarantine. I do not interpret the condensing osteitis surrounding the rarefied areas as being a part of Nature's defensive mechanism. Nature does not have that type of intelligence. Tissue cells react to various changes of environment in all stages of irritation, stimulation, depression, and exhaustion, and the same irritant may only bring the response of stimulation at one time, which, under more perfect reacting conditions, will produce sufficient irritation to produce the taking up of lime salts instead of their deposition. Therefore, the building of a zone of condensed bone about the area of rarefaction is an expression of the change in cell membrane permeability and function. The toxic substances developed in these teeth not only are not escaping through a fistula, neutralized by the blood plasma and exudate furnished as a part of an efficient local warfare, but are passing the first defense without ample obstruction and are going to all parts of the system in the fluids of the tissues through the hematogenous and lymphatic circulations. We would, therefore, expect from the change in pathology, evidencing a change in the defensive efficiency about the tooth, that the patient has lost the ability to establish and maintain the quarantine about the infected teeth; and if she is not already breaking in some tissue, she is in great danger of doing so. The fact that she is already breaking, as shown by the history, is just what we should expect.

PROGNOSIS. Since this individual's history, as shown in her own and her family record, and her history, as written in the bone changes revealed in the roentgenogram, indicates that her normal defense has been high, that it has been broken, that there is an ample source of dental toxin and bacterial infection, and that there has been a contributing physical overload, therefore, if the various overloads can be removed, she should be expected to come back to her normal which is high, and, therefore, since the dental infections form an important part of the overload and can be removed, the prognosis is good.

The subsequent history of her case is as follows: These dental infections were removed by the removal of the teeth and curettement of the sockets. This was done eighteen months prior to the writing of this text and during this time she has not had a single recurrence of the disturbance in her right shoulder, which had been almost continuous for the two years previous and, at times, very severe. Her headaches have also dis-



FIGURE 361. FOUR VIEWS OF A RABBIT INOCULATED WITH CULTURE FROM THE TEETH OF CASE NO. 1081. UNDER ANESTHESIA THE NECK MUSCLES RELAXED. AT RIGHT, SECTION OF THE CORD AND CERVICAL NERVES.

in the roentgen-appeared. When the teeth were removed, they were cultured and rabbits were inoculated, one of which is shown in Figure 364. This rabbit developed this involvement of the neck and shoulders in six days after the inoculation of a very small quantity of the culture. It gained ten grams in weight and was very little disturbed in its habits in eating. When placed under an anæsthetic, which was done for experimental purposes, the muscle spasm entirely disappeared and its head ceased to be drawn to the side. As soon as it would come out of the anæsthesia, the muscle spasm would return and the head would go back into that position. The different head positions are shown in the illustration. Figure 364-E shows a dissection of the neck and spinal cord with some of the cervical nerves. Definite pathology was found in the muscles, as shown in Figure 364 and also in the nervous system, as shown in Figure 365. It is significant first that this rabbit, when alive, maintained its head continually in a rotated position after the development of the lesion except when under the influence of a general anæsthetic which unhitched the nervous system temporarily, in which condition there was no physical evidence of a lesion. The lesion was, therefore, quite in the nervous system. It is, therefore, important in this connection to review the microscopic pathology of this condition, which is shown in Figure 365. The histological description and microscopic diagnosis of the pathologist were as follows:

"Rabbit 291. Spinal Cord. Microscopic Study.

"*Inverted Ocular* shows a small circular-shaped piece of tissue of the spinal cord, stained with a pinkish blue color. There are apparently no changes to be seen.

"*Low Power.*—The spinal cord is cut transversely. In the gray matter there are no changes of any kind to be noticed except at the proximal ends of the motor roots, there can be seen here and there small vacuolations, especially of the interstitial tissue. The blood vessels do not show any changes. The central canal with its ependymal lining does not show any abnormal changes.

"*White Matter.*—All around the border of the section there can be seen here and there many vacuolations in the interstitial tissues, also some changes in the nerve fibres. The axis-cylinders in many cases are seen to be pushed out from their central locations and in many instances only wide clear spaces can be seen, without any axis-cylinders. There are no changes to be seen in the blood vessels of the periphery of the cord.

"*High Power* shows the same changes as above.

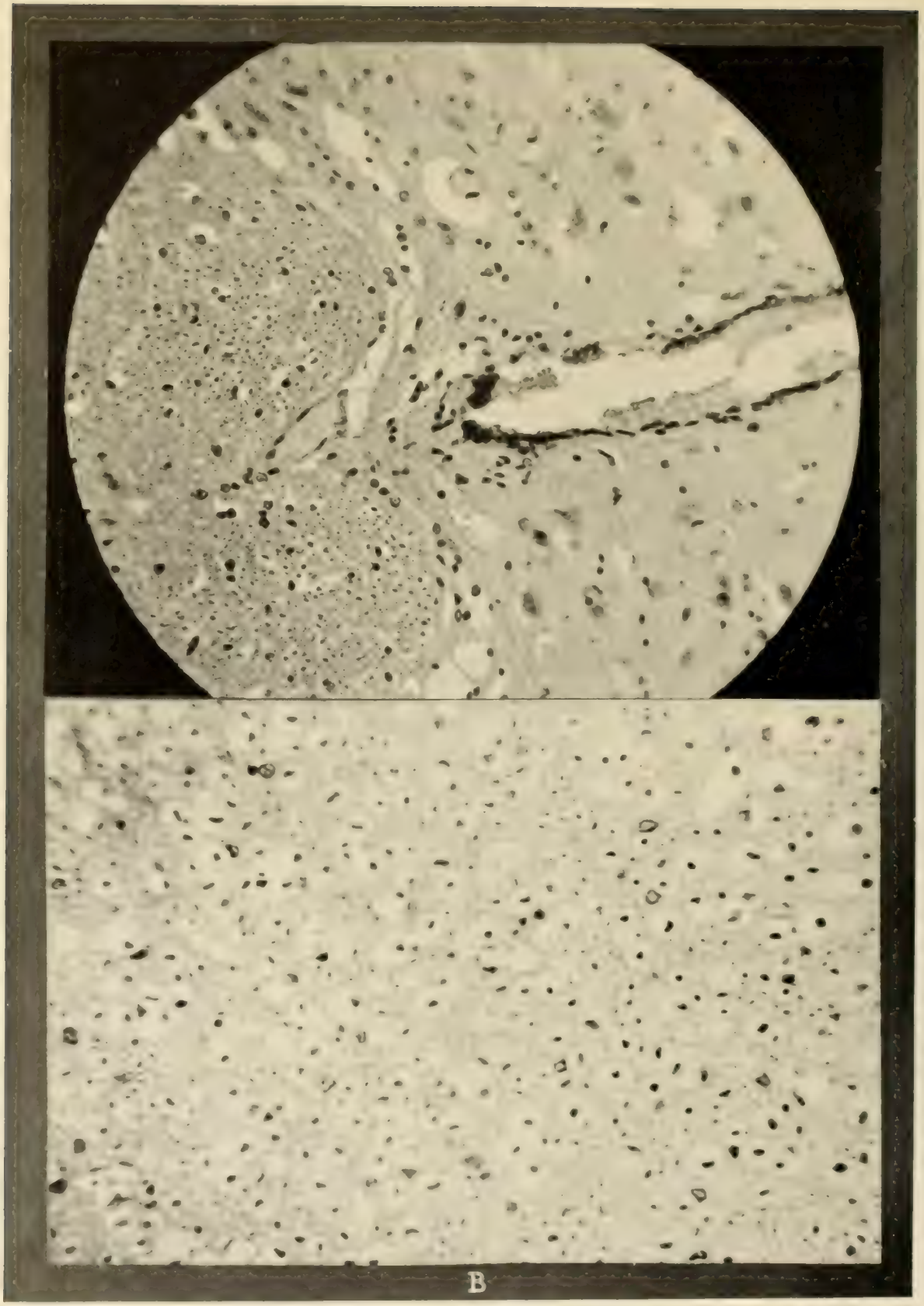

FIGURE 365. CHRONIC DEGENERATIVE MYELITIS OF THE SPINAL CORD OF RABBIT OF PREVIOUS FIGURE.

"*Diagnosis.*—Chronic degenerative myelitis (focal) of the spinal cord."

This patient had also suffered from catarrhal and maxillary sinus involvement of the right side of her face, which has not recurred since the removal of the dental infection. This case has responded just as we should expect it to do in accordance with these interpretations, and it is because of the many hundreds that have responded in accordance with these interpretations that I feel sufficiently confident now to present them as the most logical explanation for the observed data. Whether our interpretations will be found correct in all details must be left for extensive observations by many competent observers. However, there are so many contributing factors that those who observe must have a very wide knowledge of dental and general pathology. Whereas in the last case with neck involvement, the lesions were strikingly in the nervous system, in other instances we have found them chiefly in the musculature. In Figure 366, A, B, and C, will be seen sections of the muscle of the neck of a rabbit also suffering from rotation, in which three different areas of muscle tissue are used, each of about equal width. In the photograph they blend as pieces of a veneering of mahogany would tend to blend. In each of these there is marked degenerative and destructive involvement. In some muscle cells the nuclei do not stain well. The picture was one of acute myositis with degeneration of the muscle cells. In high power the organisms can be seen in some of these cases, as, for example, in Figure 358.

CYST AND MUSCLE SPASM.

Another type of dental lesion, which frequently contains toxic substances which seem to have very marked reaction on certain muscle and nerve tissues, is the dental cyst. We have seen a very large variety of systemic disturbances produced by these. A typical case is shown in the following.

Case No. 978.—Figure 367-D shows the location of the disturbance in the muscles of the neck and back where it had been becoming progressively more severe for two years, the last nine months of which the patient could not raise his hands higher than his shoulders. The trouble began seven years previously as rheumatism acutely in his right arm. Roentgenograms of his face showed a large cyst below the lower left bicuspids and molars, apparently, directly related to mesial root, partially root-filled, of the first molar. Its extent is also clearly shown in the roentgen-



FIGURE 366. THREE SECTIONS OF MUSCLE TISSUE FROM NECK OF ANOTHER RABBIT SUFFERING FROM TORTICOLLIS.

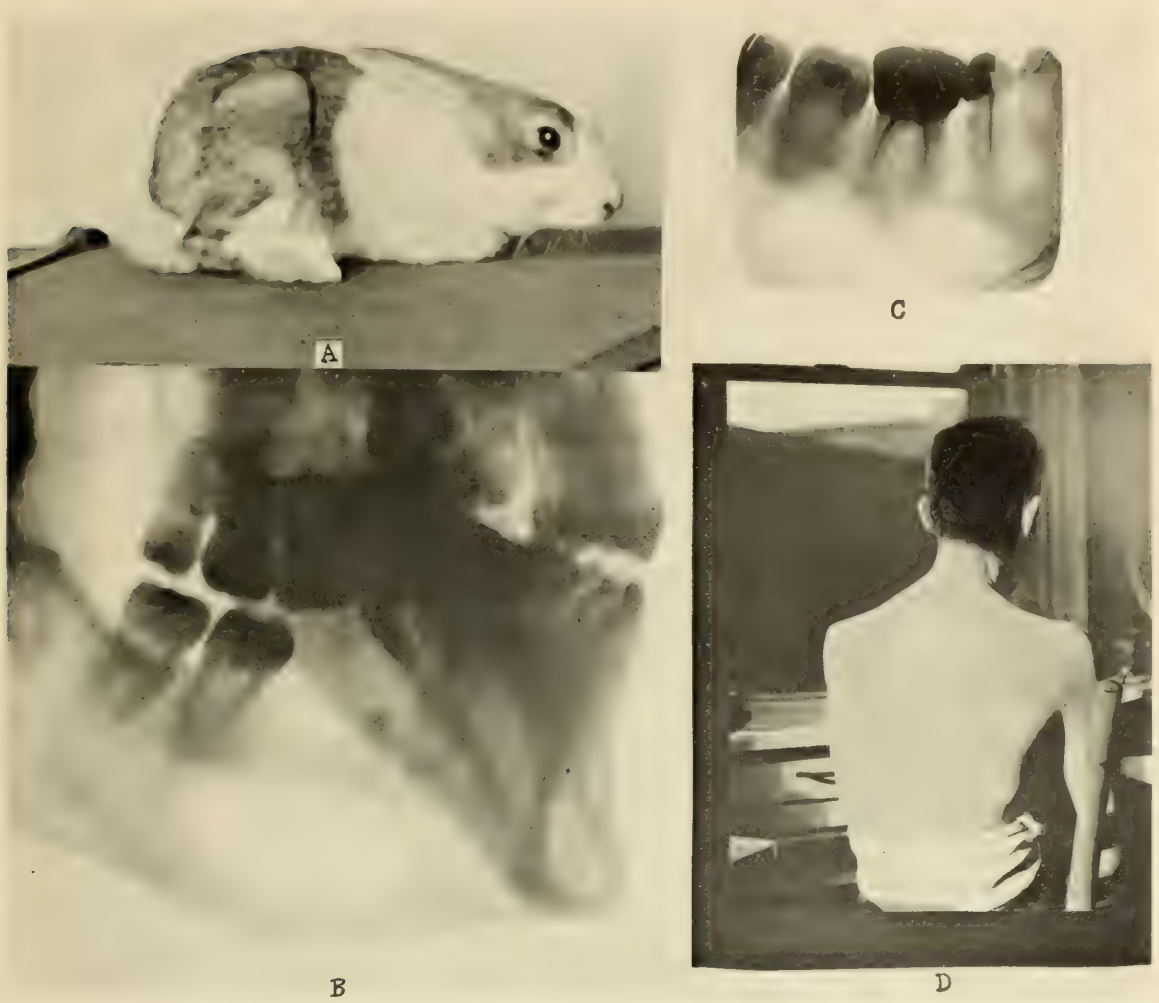

FIGURE 367. AN ACUTE INVOLVEMENT OF THE MUSCLE OF THE NECK AND SHOULDERS SHOWN IN D, RELATED TO THE CYST SHOWN IN C AND B. OPERATION FOLLOWED BY RAPID AND MARKED IMPROVEMENT. A, A PARALYZED RABBIT INOCULATED FROM CULTURE OF SAME.

ogram of the mandible, made after the extraction of the teeth. The surgical treatment of this case was as follows: Owing to the involvement of the inferior dental nerve and the blood vessels which would, of necessity, be injured, if not destroyed, by a complete curettement of the cyst chamber, a liberal section of the alveolar wall was removed and the membrane of the mouth allowed to develop into the cyst chamber and replace the cyst membrane. Where the cyst wall was trephined, the tissue and membrane were removed intact for sectioning, shown in Figure 368. The pathological picture is very interesting. Where the cyst membrane is in contact with the alveolar bone, extensions are

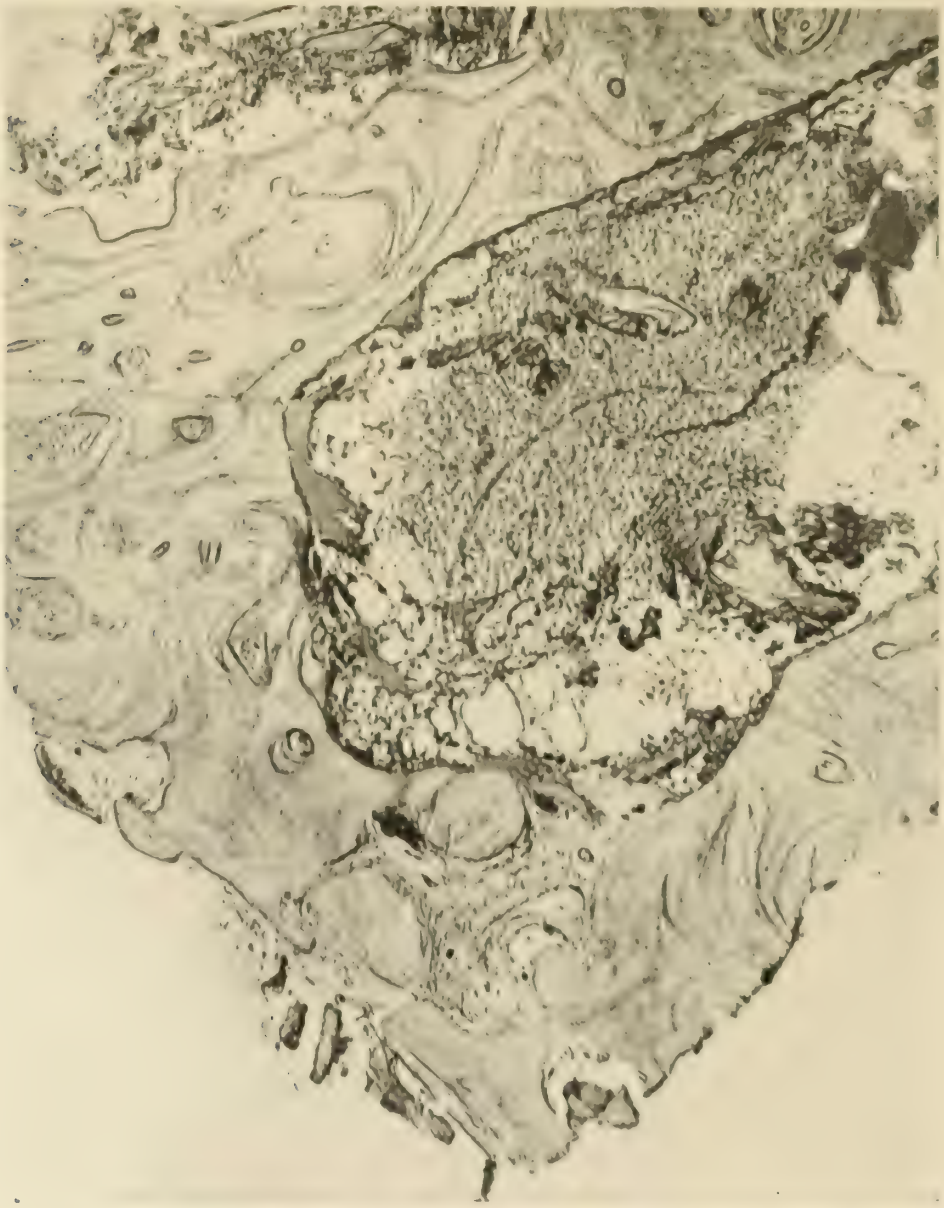

FIGURE 368. A SECTION FROM THE CYST WALL OF PREVIOUS FIGURE. NOTE OSTEOCLASTIC ACTIVITY.

seen thrusting themselves into the bony structure in the process of undermining and absorbing it. Osteoclasts and giant cells are seen, in the higher powers, in the act of taking down the bony structure. The detailed pathological interpretation is as follows:

"*Inverted ocular* shows a circumscribed area of bluish stain,

surrounded with a narrow zone of a red color. The greater part appears to be composed of a dense, compact tissue and a swollen portion, resembling very much gland tissue. *Low power* shows a great portion of the section to be composed of a large number of connective tissue fibres, arranged in a wavy manner. A large number of blood capillaries, distended and filled with blood, can be seen. The tissue, which resembles a gland under inverted ocular, shows the epithelium stratified. The papillæ show degenerative processes with many young blood vessels. At some places, there are areas of proliferative cells accumulated around blood vessels."

The pathological studies of the cyst are discussed under Chapter 69. A very important factor of this case is the following: Within five hours after the opening and draining of the cyst chamber, the patient felt the distinct relaxation in the tension and spasm of the muscles of his shoulders. He could already raise his hands higher than for some time previously. In twelve hours there was a marked improvement, and by the next day he could place his hands high over his head. It is now two years since this operation was made; and while his trouble was not entirely corrected, his condition was very greatly improved and has remained so with but one marked recurrence, the details of which are particularly important and were as follows: In order to protect the cyst chamber and its delicate tissues, for the inferior dental nerve and arteries and blood vessels were clearly visible passing along the floor of the cyst, a removable restoration was made replacing the missing teeth by supporting on clasps on the teeth adjoining the space. This not only restored occlusion, but prevented the food from getting into the cyst chamber which for some days after the operation was packed and irrigated with normal salt solution daily. This became so comfortable that the patient forgot to remove the denture and irrigate the cyst chamber twice daily, as directed, and it received no attention for several days. He presented at the office with considerable alarm because of evidence of return of the old distressing symptoms. When asked if he was irrigating the chamber with a special wash as directed, he realized that he had not done so for several days. The symptoms promptly and entirely disappeared again with the reestablishment of the irrigation, which emphasizes the importance, as we have seen in many other cases, of maintaining com-

plete freedom from retention of the fluids of the cyst until Nature has replaced the cyst membrane with the extended mucous membrane of the mouth. A culture was made from the cyst fluid which was inoculated into a rabbit which is shown in Figure 367-A, carrying its hind leg.

A photograph showing the cyst contents is seen in Figure 369. The large crystals are cholesterol. These cyst fluids are discussed in Chapter 69 under Cysts.

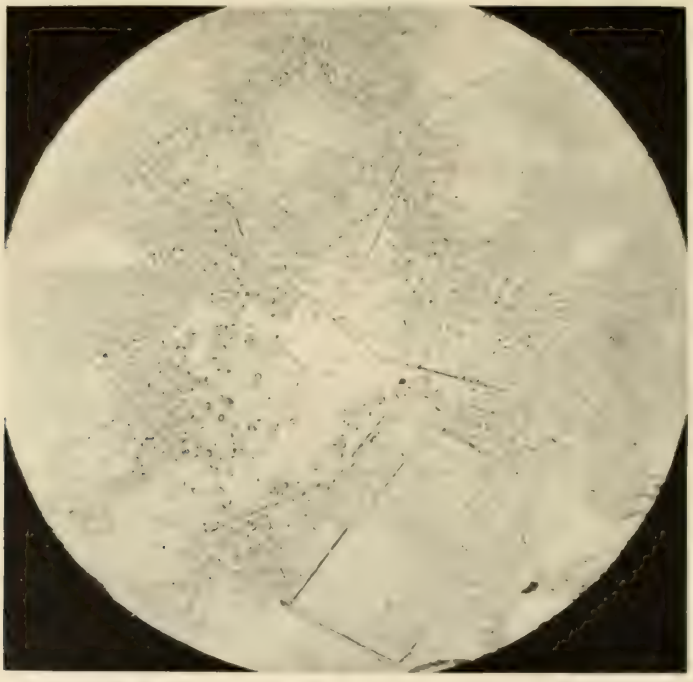

FIGURE 369. A PHOTOGRAPH OF THE CONTENTS OF THE CYST SHOWN IN FIGURE 367. LARGE CRYSTALS ARE CHOLESTEROL.

RETAINED GRANULOMA AND RHEUMATISM.

In former years, owing to the little knowledge of dental pathology, little or no attention was paid to the sockets after the extraction of teeth. If the granuloma remained attached to the tooth, the tooth was considered particularly dangerous because it had the so-called pus sac. If it chanced to remain in the alveolus, its presence was not discovered. The accumulating evidence of these old cases strongly suggests that many individuals have suffered serious harm because of the lack of proper curettage at the time of extraction and the proper treatment of the sockets.



FIGURE 370. A SMALL DENTAL CYST BEFORE AND AFTER OPERATION, POSSIBLY ORIGINALLY A DENTAL GRANULOMA.

Such a case is shown in Figure 370. A shows an overgrown granuloma in the position formerly occupied by the right first permanent molar, which was extracted thirteen years previously, and which, during the patient's memory, was abscessed. Of late years, the patient had suffered from rheumatism. An operation was made by me to remove this overgrown granuloma by trephining a section of the dense alveolar bone from directly over its point of nearest approach from the buccal aspect. The bone surrounding the granuloma was exceedingly dense and the bony chamber, when it was enucleated, had a dense glistening surface that to a sharp pointed instrument felt almost like glass. After the removal of this granuloma and the curettement of the surrounding condensed bone, this patient's rheumatism, the cause of which had been obscure, disappeared and has not returned as such for four years.

In the light of my various studies I would be inclined to interpret this patient as having a low factor of safety from other causes, and the removal of the granuloma might relieve the system of the source of infection to complicate the general picture, but would not relieve it of the other contributing factors. Indeed, this is borne out in this very patient's history in the fact, that she developed nephritis; and while her nephritis may have been related to other dental conditions, (I think, however, here again they were only contributary,) the granuloma that we removed probably was not an important contributing factor in the development of her nephritis, since it apparently developed after the

removal of the granuloma. There probably is great danger that, because of our limited knowledge of the symptom complex of a patient and of either normal or abnormal tissue reactions, we will look for causes as being more simple and isolated than are the facts.

In Chapter 60, under Circulatory System, I cite a case of very marked muscle atrophy, rheumatism, and heart, associated with a type of rheumatism which is very painful. This patient, Case No. 1009, had, as I noted, suffered an attack of infantile paralysis in childhood, from which she quite completely recovered, had a normal life as a girl and young woman, married, and had several pregnancies and miscarriages close together, which so reduced her vitality that she developed a type of arthritis which I have discussed as degenerative in form. In Figure 289 will be seen the roentgenograms of the teeth of this patient.

I wish to call attention particularly to the fact, that, whereas, I have said over and over in this book that people with strong rheumatic tendencies tend to have very slight rarefying osteitis either at apices or at gingival margins as the result of irritations, yet, in this case there is very marked evidence of periodontoclasia. This will be particularly noted about the molars and bicuspids of the lower jaw and the incisors of the upper. I wish to stress that this is not a contradiction, but an illustration of the exception to which I have referred in several chapters as the type with the degenerative form of arthritis instead of the proliferative form, and which is accompanied by a normal or even high ionic calcium of the blood in contrast with the depressed ionic calcium of the proliferative type. It seems very probable that the type of calcium metabolism disturbance associated with this lesion is distinctly different from that of the other type. I have discussed this in relation to the role of calcium in neutralizing acid products of the blood when the blood itself is carrying these imperfect products of oxidation and when bases less costly to the organism or to the individual are not available.

The following items should be noted in this case, which is typical of a group containing many individuals: The process of sacrificing bony structures, when the available supply of calcium is not adequate, with the development of periodontoclasia and the degenerative types of osteitis about joints, is in keeping with this general group of symptoms. In this connection it is also of interest to note that while this patient had suffered from atrophy

of certain muscles, as a result of her infantile paralysis of childhood, these had not been structurally conspicuous and inconvenient handicaps until the development of this degenerative type of rheumatic arthritis. During this process the muscle atrophy developed to such an extent that if her head would accidently swing back too far, she would be entirely helpless to raise it again unless someone would come to lift it to a balanced position above her shoulders, due to the almost complete loss of function of the sternomastoid and associated muscles. After the removal of her dental infections, by the removal of the teeth with the periodontoclasia pockets, and the use of the vaccine, which, as I previously noted, produced so marked a change in all of her symptoms, including the improvement in her badly infected heart, and although she had been an invalid for a couple of years, she was restored to very comfortable health and capable of walking distances where previously she had to be carried or taken in a wheel chair.

I would stress again that we must not think of calcium metabolism disturbances as being so simple as that a depressed ionic calcium is directly a measure of the disturbed metabolism. In Chapter 66, I have discussed in detail a case (No. 484) of very extreme muscle atrophy, involving the right arm so that it was only about one-half the size of the left and was so nearly helpless that the individual could not carry five pounds with it. After the removal of the dental infections, this man's arm so greatly improved that he could swing a pail full of water over his head and could use a heavy sledge hammer, a thing he had not been able to do for twenty years. The relation of this type of muscle atrophy to the enervation of these muscles is discussed in detail in that chapter; and we must think of the muscle lesions, which we are discussing in this chapter, as being very frequently related to involvements of the nervous system.

A discussion of the lesions of the muscular and skeletal structures would not be complete without the inclusion of a discussion of the relationship of the systemic involvement, expressing itself in general deforming arthritis, and the health and comfort of the teeth of the individual. In Chapter 40 on Dental Involvements Caused by Arthritis, I have presented researches directed specifically to the disclosing of this relationship. These revealed that in a manner quite similar to that in which arthritic processes involve and destroy synovial membranes and adjacent structures of

joints, so that same systemic involvement may injure and involve the supporting structures of the teeth and their pulps. I have cited in that chapter several cases illustrating this direct expression of the systemic disturbance in the dental conditions.

One of the most striking of these is Case No. 355, in whose mouth a number of teeth have become involved in succession, some of them coming finally to have non-vital pulps, without that destruction process being related to caries, trauma, or other natural causes. To save repetition I will not repeat here the illustrations, but will refer to them in Figure 29, Chapter 3. I do, however, feel it necessary to repeat the important substance that the roentgenogram of the upper right second bicuspid, shown in Figure 29, which was made in 1901, revealed a zone of very definite radiolucency, indicating a periapical absorption. I, at that time, treated the tooth and filled its root in accordance with the best knowledge of that period. Kindly note that from the standpoint of usual interpretation, there is every evidence that my operation was a success, since the rarefied area became normally radiopaque by the year 1914. By 1916, when my researches had advanced to a point where I was fearful for the safety of patients carrying such conditions, it is important to note that the periapical bone had become more than normally dense. During these fifteen years this patient had been getting progressively more and more involved with deforming arthritis, having come to a condition in which she was almost helpless, having to be carried or move herself with very great difficulty on crutches. It is also important to note that when this tooth was extracted by a method which was deemed adequate to destroy all living organisms—namely, the use of an electric cautery to sear as deeply as it could reach into the tissues about the neck of the tooth before its extraction—the periapical tissues showed, on culture, the presence of a diplo- and strepto-coccus, which organism was also found in the bone for a distance of one-fourth of an inch beyond the alveolus. These cultures, when inoculated into rabbits, produced joint lesions, which, in itself, is not strikingly significant, since streptococcal infections from various types of dental sources tend to produce involvements of joints. The percentage, however, is much higher when the culture is taken from patients suffering from acute processes.

With the removal of this patient's involved dental conditions, which existed at that time and which have developed since, there

has been, continually, evidence of a direct relationship, both demonstrating that the teeth were causative in her case in making the systemic involvement worse, and also that her systemic condition attacked the teeth with structural and functional changes in the peridental membrane, with absorption of cementum and fibrosis and calcification of the dental pulps. In one of the last teeth extracted, also illustrated in Chapter 40, the pulp chamber was practically entirely obliterated by one huge pulp stone, with the remarkable coincident condition that the tooth was not only still hypersensitive to thermal change, but to instrumentation and irritation of the dentin at its gingival border. This patient has been so confident that the removal of her involved dental conditions has improved the systemic, that no compensation in the world could induce her to have one of these teeth back if she could. Her marked systemic improvement following these dental involvements has seemed to justify this confidence on her part.

That dental infections are directly related to osteomyelitis seems to be abundantly illustrated by the many instances of progressive involvement of the medulla of the bone. On culturing, these usually show streptococcal involvement. Their progressive invasion of normal tissue may be so rapid as to involve the entire mandible or one or both maxillary bones, or any part thereof. That these are related directly to streptococci has, as I suggested, been very frequently observed and reported. I wish to present here a case which, however, seems very definitely to be related also to a spirochete invasion.

Case No. 1417.—This young man, age twenty, presents with the following symptoms and history. Following the extraction of the left central incisor, because of an apical abscess, a very acute infection spread to and involved the maxilla and all the teeth, including the first molars, and so violently that he was taken to the hospital instead of returning to the exodontist who made the extraction. He lost twenty-five pounds in a week, and when brought to me by his dentist, while he was sufficiently improved to walk, pus was discharging from the roof of the mouth and from five fistulæ on the buccal and gingival surfaces of the alveolus between the central incisor and the left first molar. Several of the teeth were so loose that it seemed they could be picked from his mouth with the fingers. These are shown roentgenographically in Figure 371, and some were made with flexible gutta-percha points to aid in the differentiation. The bone seemed non-



FIGURE 371. ROENTGENOGRAPHIC APPEARANCE OF AN OSTEOMYELITIS OF THE MAXILLA FOLLOWING AN EXTRACTION. SEE CHAPTER 43, VOLUME ONE.

vital for some distance about several of these fistulæ. The smears from the aspirated material revealed under the dark field a profuse culture of spirochetes in addition to the streptococci. This has suggested immediately the possibility, if not probability, that his infection had been an extension of a periodontoclasia to the alveolus. A bacterial examination of his gingival infection revealed an abundance of a similar spirochete.

It is interesting to try to visualize what has taken place in this young man's condition. Both his age and the type of reaction about his teeth would suggest a good capacity for defense. Why, then, did his invasion become so rampant? When we review his clinical history we find that an effort had been made by treatment and root filling to save this tooth which had an infected pulp and which latter produced the violent apical involvement immediately following the placing of a gold inlay. When infection is retained under pressure, there must either be a tremendously active reaction and inflammatory combat in the immediate vicinity, with an adequate vent for discharge, or the toxic substances will enter the system. If the high defense shall be maintained, the toxic products of the warfare will be discharged into the lymphatic and hematogenous circulations. But in this young man's case, his abscessing incisor was retained long enough for his eye to be swollen nearly shut before the extraction of the

tooth. There was, accordingly, a great deal of local and therefore, of necessity, systemic involvement with the toxic substance of this warfare.

We also note from the history that he lost twenty-five pounds in eleven days, 17 per cent. This again suggests just such a reaction in loss of weight as we have demonstrated to occur in rabbits when the infection of planting the tooth is permitted to overwhelm them, for his percentage loss per day was approximately 2 per cent, which was the amount we have shown to occur in rabbits, and represents such an infection and toxic invasion as will very greatly reduce the defensive powers of the blood and very greatly reduce the ionic calcium. It is, therefore, of interest to note that just as a reduction of 15 to 20 per cent in the weight of a rabbit will usually represent a reduction in the ionic calcium of the blood of at least 10 per cent, just so this young man's ionic calcium was reduced approximately 10 per cent. But even more important, there was a pathologically combined calcium of 3.35, which is very unusually high for even pathological cases. The alkalinity index of his blood was reduced to 2.66, and in a few days' time had increased to 34.

We have, then, a suggested means for reinforcing his defense; and it is also of interest to note, that placing him on a regime for the increasing of his ionic calcium and the reinforcing of his defense, has almost immediately checked the activity and spreading of the infective invasion. He was placed on parathyroid extract with quite rapidly diminishing dosage, three-tenths the first twenty-four hours, two-tenths the second twenty-four hours, and one-tenth per twenty-four hours daily for a few days, together with calcium lactate, three tablets with each meal, and in a week's time his ionic calcium was back to normal and his general systemic condition practically normal.

But a matter of perhaps greater interest is the following: Whereas, in this type of case the usual procedure would be to extract all the involved and loose teeth and make extensive curettage, no teeth were extracted, thorough and frequent irrigations being used through the fistulæ in order that such of these teeth as might remain vital and be retained, could do so. This program was adopted, based on my experience of several years, in which I have found that, frequently, teeth, that would be considered so

seriously involved as to be utterly incapable of reattachment, have been retained and their vitality retained. This program, however, would not be adequate unless there accompanied it a very careful interpretation of the reactive capacity of the patient, by studying the bactericidal properties of the blood *in vitro*, as well as determining the ionic calcium and the other factors such as blood morphology. I present this case to illustrate how that with a better knowledge of the pathological processes involved, and a study of the efficiency of the mechanisms of defense, very much more conservative programs will not only be justified but urgently indicated, for fundamentally this bush-fire type of infection is primarily dependent upon a temporarily broken defense.

Another indication of the toxic phase involved in this case is the fact, that his polymorphonuclears were 59 per cent, his small lymphocytes 30 per cent, with his total leucocyte count 8,400, which relationship was changed in one week's time to polymorphonuclears 70 per cent, small lymphocytes 20 per cent. The bactericidal efficiency of his blood was approximately 50 per cent of normal at the time of his serious involvement and one week later had increased to 80 per cent.

He has been saved the serious deformity which would have attended the extensive extractions and curretage of all involved tissue, for the palate and alveolar ridge have been permitted to rebuild in its original form, and whether the teeth are retained for most of his lifetime or not, the ridge is retained, and therefore his facial expression has been conserved, and this to no disadvantage. Later one tooth was extracted and the sequestrum surgically removed, the teeth being supported by a splint while new bone was being formed.

In Volume I, I have discussed in various chapters, factors that are involved, and which contribute to determining the type of expression of dental infections, particularly the changes that develop in the hard structures. These involve variations in defensive factors of the patient, which modify the local expression directly and indirectly by modifying the organisms involved since the organism tends to develop characteristic qualities dependent upon the pabulum or culture medium furnished by the host. The arthritides may be expressed with extensive proliferations with osseous hypertrophies, or may be characterized quite largely by degenerative destructive wasting processes which later involve not only the involved surfaces but a decalcification of the body of

the bone. In some instances both of these conditions will be in progress at the same time in different parts of a joint or in different joints.

It is remarkable how rapidly these progressive degenerative processes may develop and progress. This can be illustrated by reference to many of the illustrations in these two volumes, most of which, however, have not been sectioned or presented to illustrate this point. It can well be seen in Figures 372 and 373, which show the articulating surfaces of the knee joint of a rabbit in each the normal and the arthritic involvement, and are larger views of the frontispiece of this volume. Twelve days after the rabbit was inoculated with 1 cc. of the anaerobic strain grown from an infected tooth of Case No. 1414, it developed a swelling of the left knee joint and favored that limb. Twelve days later it was chloroformed and the tissues taken for section, Figure 372 showing the normal right knee and Figure 373 the involved left knee. By reference to the normal, it will be noted that the articulating surfaces of the heads of the femur and tibia have smooth even surfaces, supported by the well developed trabecular structure of the epiphyses. The joint capsule, medial meniscus and the synovial membranes are all in excellent condition and can readily be differentiated.

In comparison with this it will be seen by referring to Figure 373, that the arthritic knee has undergone very extensive change. First, it should be noted that there is slight difference in the plane from which the sections are taken, which does not, however, modify the pathological picture. The difference in size is due to swelling. In the arthritic joint there has been very extensive inflammatory destruction of the joint capsule, with its rupture. The pus escaped when the tissues were prepared. The trabeculæ of the epiphyses are undergoing decalcification and the articulating surfaces and their cartilages have been very seriously mutilated by the inflammatory process. The posterior cruciate ligament appears in this section though but slightly in the former. Its attachments have been seriously injured and its body is undergoing necrosis.

It can easily be understood how such an inflammatory process, destroying the synovial membranes, joint cartilages, ligaments, and capsule, would in a proliferative process tend to throw down a deposit of bone quite regardless of form and function, and would tend to produce a condition which would be entirely im-

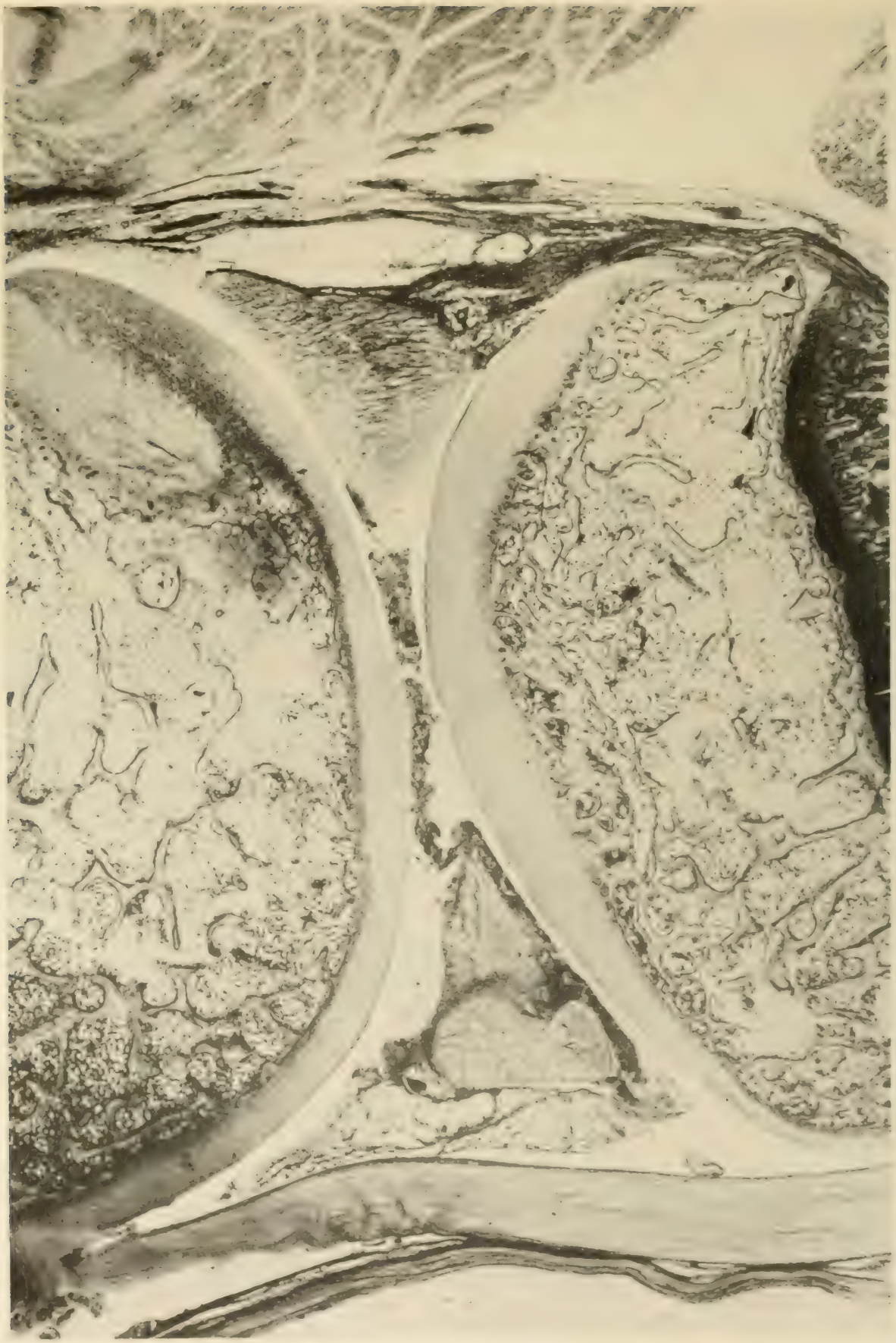

FIGURE 372. NORMAL ARTICULATING SURFACES OF RABBIT'S KNEE. NOTE EXCELLENT CONDITION OF CARTILAGES, CAPSULE, AND JOINT STRUCTURES.



FIGURE 373. PATHOLOGICAL ARTICULATING SURFACES OF RABBIT'S KNEE WITH ACUTE RHEUMATISM. SLIGHTLY DIFFERENT PLANE FROM PREVIOUS FIGURE. NOTE NECROSIS OF POSTERIOR CRUCIATE LIGAMENT AND CARTILAGES.

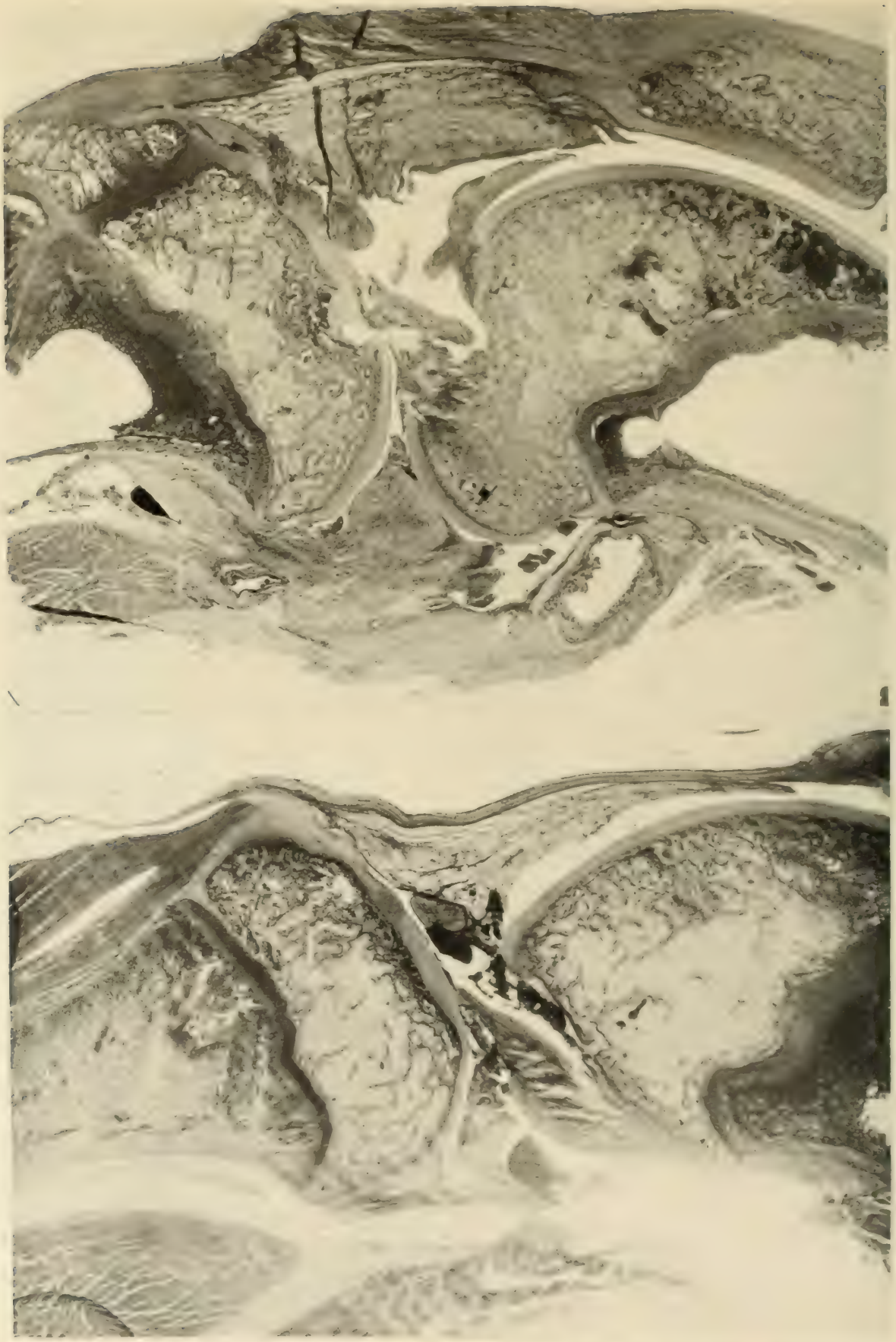

FIGURE 374. COMPARISON OF NORMAL AND ARTHRITIC KNEE JOINTS OF RABBIT IN NEARLY CORRESPONDING PLANES AND DIFFERENT PLANES FROM THE PRECEDING FIGURES: UPPER, PATHOLOGICAL; LOWER, NORMAL.

mobile, if not a continuous dense bone from one long bone to the other. When we realize that this degenerative process which would with certainty have destroyed the function of this knee was produced from the inoculation of a quantity of germs, which, when separated from the solution in which they were suspended, would not have a bulk half as large as the head of a pin, and which would weigh approximately one or two thousandths of a gram, we realize somewhat of the potential possibility of these organisms, particularly when we realize that they were thrown into the entire blood stream with its relatively large capacity for defensive process. I have shown in Chapter 42 of Volume I, the difference in the defensive qualities of different bloods. The organisms injected into this rabbit would pass by way of the circulation to practically all organs and tissues of the animal's body and would survive in those tissues only, which had the low capacity for attacking them, assuming some of them failed to be killed by the blood stream.

When we realize that this reactive response of the blood may call from the leucocytes the bactericidins within one minute's time after the injection of the organisms, we realize how quickly the germs must get into some protected position if they will ultimately survive. Unfortunately for humanity the streptococcus contains in its protective mechanisms, defenses which are very hard to overcome even under favorable conditions. When, however, these organisms find a lodgment in tissues that have very pure vascularization and deficient in defensive fluids, they tend readily to proliferate. Their method of warfare is not, however, entirely a defensive one, for, as I have illustrated in Volume I, they generate toxic substances which tend to paralyze the leucocytes and thereby incapacitate them for their normal function. The warfare, therefore, may be a progressive one with very extensive degenerative processes, or there may be a truce in which the organisms will be surrounded by bactericidal and physical obstructions which will compel them to limit their activity to a balance between their own toxicity and supply of nutriment on one side, and the defensive mechanisms of the host on the other. The streptococci in this form may take on a very low grade vitality in which they will produce exceedingly little irritation to the host, under which conditions the host withdraws, or fails to develop its defensive fluids to resist the organisms and their toxins. This apparently quiescent process may then become a

new primary focus from which new infections will proceed to attack other tissues near or far, and it is doubtful if an individual so attacked can ever be sure that the infection has been entirely destroyed, for the evidence seems very conclusive that these processes tend to light up again when irritated. Goadby[1] has shown that streptococci in wounds in bone may lie dormant for years, and on so trivial an accident as the bumping of the shin and thereby starting an inflammatory process, the encysted streptococci may begin an active aggressive process and kill the host. Every individual, therefore, who has had an attack of rheumatism or heart involvement, or other streptococcal organ and tissue invasion, may be handicapped for life and always live in the presence of an impending great danger, and on the strength of statistics must be considered to have his or her life prospect and possibly duration definitely reduced. It is therefore not an unimportant matter to wait until a dental infection has produced evidence of harm before eliminating it. No course is a truly efficient one in the treatment of disease which does not prevent it.

A very serious and frequent effect produced by cultures taken from teeth, when inoculated into rabbits, is the production of osteomyelitic processes of the spine. One of the very distressing disturbances which the surgeon encounters, is a Pott's disease involving the vertebral column so seriously as to produce gross deformity and grave disturbance. In Figure 375 will be seen a number of lesions of the spine which have developed in rabbits so inoculated. B shows a roentgenographic view of the spine of a rabbit in which paralysis was produced, and it will be noted that there is a marked condensing osteitis with a destruction of the intervertebral cartilage and a condensing deformity of the proximating surfaces of the vertebræ. A shows the dissection and the pinching of the spinal cord produced by this bacterial invasion. B shows the roentgenographic appearance from the lateral aspect. E shows the photograph of a ventral surface of a spine of another rabbit. Note the destruction of the intervertebral cartilage and a localized zone of inflammation and hypertrophy. D shows a lateral view of this case after the lateral walls of the vertebræ had been removed, and it will be seen that there is distinct nodule formation on the ventral surface of the cord, involving the bodies of two vertebræ. A cross section of the spinal column and cord, involving the bodies of the vertebræ, will be seen in Figure 348,

[1] See bibliography

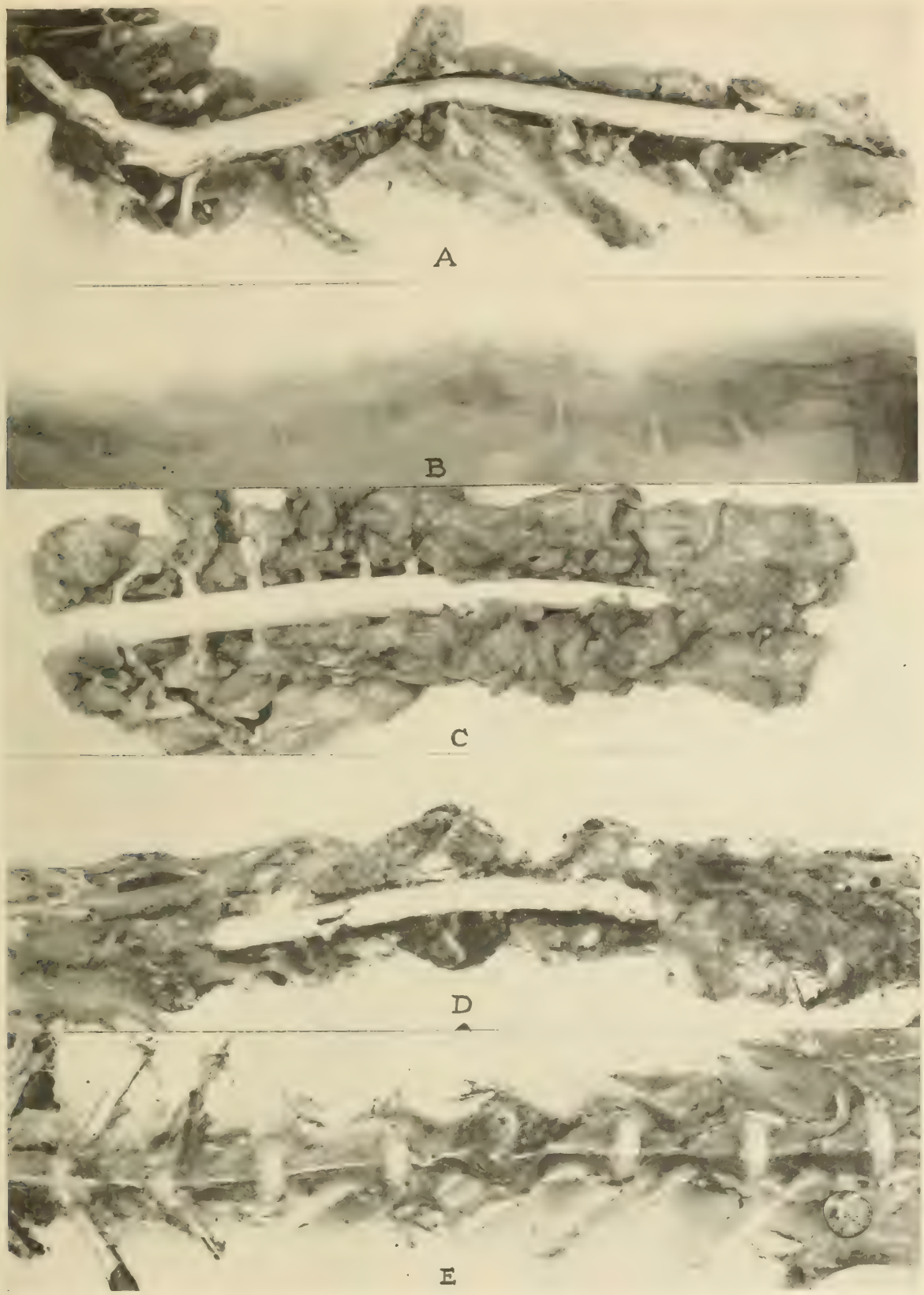

FIGURE 375. SEVERE SPINAL LESIONS PRODUCED IN RABBITS BY THE INJECTION OF CULTURES FROM DENTAL INFECTIONS.

where it is discussed under skeletal and muscular system in deforming arthritis. C shows another spinal involvement.

We have made progressive studies of some of these spine lesions, a typical illustration of which will be seen in Figure 376. This rabbit shows in A the beginning of a distinct condensing osteitis involving three vertebræ and two articulations. This rabbit had been inoculated with the culture from the teeth of Case No. 1178, the rabbits of which case nearly all developed joint and bone, and nervous system involvements. There was a progressive increase of the condensing osteitis, as shown in B and C, the latter being four months later than the first.

This is particularly instructive since many, if not most, of the members of the dental and medical professions, and therefore of the laity who have been instructed by them, expect an infection process in bone to express itself with the removal of bone and the formation of a chamber, and therefore a radiolucent area. In humans, as I have shown, we find the type of bone change that is produced is dependent upon the type of reaction of that individual and will be different in the same individuals at different times in accordance with his or her capacity for reaction, hence a condensing osteitis surrounding a zone of rarefying osteitis, etc. I have also shown that this quality is one that is characteristic of families, and, therefore, in part a mendelian trait and subject to the laws of heredity. In rabbits we do not find a difference in reaction in different litters, which would correspond to the human type of reaction. There is strong evidence, however, that if the organisms are transferred from the human in sufficiently young generations, they will carry over to the new host somewhat of the same tissue elective localization quality which that strain *acquired* in the previous host. Rabbits like most of the biological units tend to adapt themselves to any fixed conditions and environments and, as I have shown in the chapters on blood chemistry, infections, whether introduced by intravenous or subcutaneous injections, readily present changed factors of resistance and therefore of safety, and just as individuals, who have once broken seriously with streptococcal infection, tend to be more liable to infection of the same type in the future, similarly, rabbits that have had developed in their bodies arthritis, seem never to regain again their original defense.

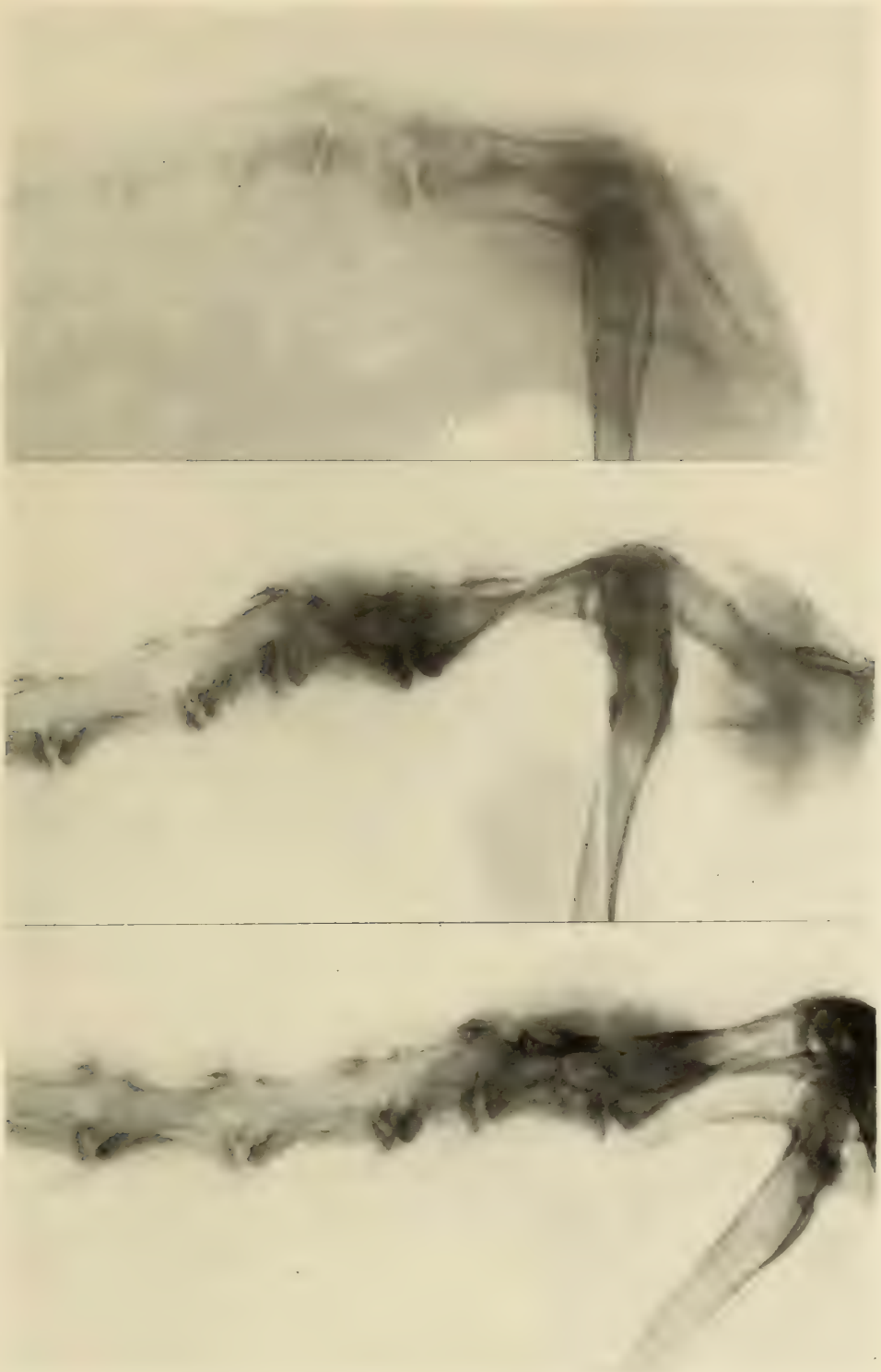

FIGURE 376. PROGRESSIVE DEVELOPMENT OF A SPINAL DISEASE RESEMBLING POTT'S, FROM INOCULATION OF A DENTAL CULTURE.

OSTEOMALACIA.

There are many gradations in degree of the tendency to build up and take down bone in the various pathological lesions, ranging from the extreme arthritides, in which in some instances practically every joint of the body is obliterated and a skeleton becomes one continuous casting of bone, often with extensive hypertrophic deposits, to the gradual and extensive decalcification of bones producing an equally severe lesion as an osteomalacia. In order that this may be more clearly understood, I have presented in Figure 377, three hands representing these two extremes with a normal in the middle. The ages of these individuals do not differ sufficiently to enter seriously into consideration. B is the normal, and it will be noted that the carpal bones are all quite uniformly dense but with distinct separating cartilages. The metacarpal bones, like the other long bones of the body, show a splendid calcification of the shaft and have their epiphyses completely ossified and attached with almost complete obliteration of the junction of the epiphysis with the shaft. In comparison with this will be seen that in A there is a very marked accentuation of the deposition of lime salts, as represented by the greatly increased radiopacity. The contraction of the muscles has tended to produce much deformity, and there are hypertrophic deposits around nearly all articulations. The carpal bones are fused together and have largely lost their unit characters. In C we have the hands of a patient with osteomalacia. In general, there is much less opacity to the Roentgen-rays throughout all the bones. The carpal bones not only have less density but have abnormally thick cartilages separating them. The epiphyseal junction of the shafts of the long bones is still quite visible in many of the ossifications.

The three groups which will be represented by these three individuals have several characteristics. Those of Group A seldom, if ever, have periodontoclasia and but slight reaction about teeth resulting from local irritants, such as crowns and food packs. Those in Group C tend very rapidly to periodontoclasia in its most extreme and obstinate forms. Those in Group B react to irritants with absorption in a moderate degree and respond well to treatment. Almost universally it would be said of the group in A that their teeth extract with great difficulty and are slow in healing, amounting frequently to so-called dry socket. The teeth of the individuals in Group C extract exceedingly easily.



FIGURE 377. THREE TYPES OF OSSIFICATION: B, NORMAL; A, PROLIFERATIVE ARTHRITIS; C, OSTEOMALACIA.

Anesthesia is produced with great ease, and except in the advance stages there is little after-trouble from sockets. The individuals in Group A, whether suffering from deforming arthritis or a mild tendency to it, tend readily to develop excementosis. Those in Group C not only do not produce excementosis but on the contrary produce a marked thinning of the cementum of the tooth, as we shall show later. Those in Group A tend to develop calcifications of the pulp with pulp stones, whether suffering from arthritis or simply of that group classification, not having broken. The individuals of Group C practically never have pulp stones or pulp calcifications while in that state.

At this point I should stress that individuals may have a marked tendency to periodontoclasia as an active process, at which time they will have a characteristic physical condition as expressed in their blood chemistry, and which physical condition may completely change in a few months' time, and they will go into a state in which their reaction would be entirely different from that which previously obtained. To the casual observer so-called pyorrhea pockets would look the same in both these stages, yet, pathologically and clinically, they are entirely different and unlike. This I have discussed in Chapter 28 in Volume 1. From the standpoint of our present information it would be so difficult as to be practically an impossibility to produce the same type of results in the treatment of gingival irritations in individuals of Group C as those of either Group A or B.

To illustrate further the difference in the individuals in these groups, I have shown teeth from individuals representing Groups A and C in Figure 379. The tooth marked A in that figure was extracted from the patient whose hand is shown in C of the previous figure. Note that the cementum has been thinned down to a very thin covering shell and almost entirely destroyed at places. This has not been the action of the bathing pus, but is a characteristic of all of the teeth of this individual. The roentgenographic appearance of her teeth is shown in Figure 378, and it will be noted not only that there was extensive periodontoclasia, but that there was a marked characteristic of slenderness. In contrast with this I have shown in B a tooth from a patient who belongs in the class which I have discussed under A of the preceding figure, and it will be noted that there has been exceedingly extensive depositions of layer upon layer of cementum in this latter case until the diameter of the root a little distance from

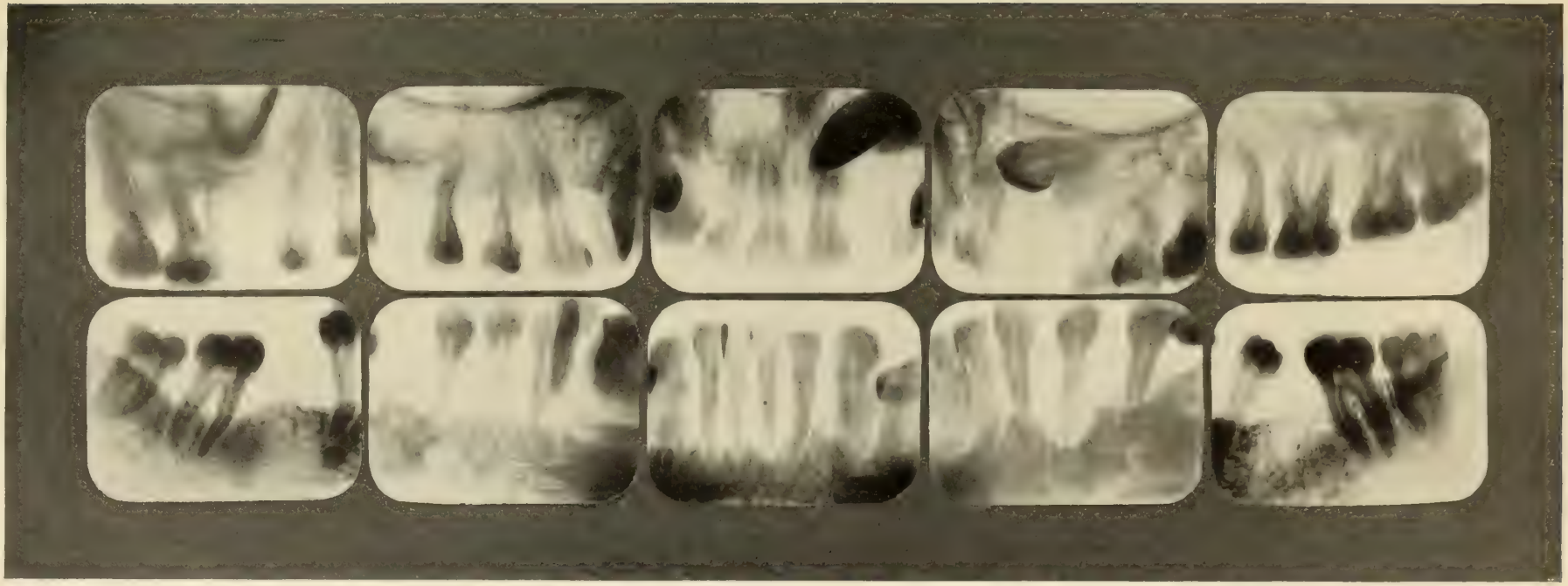

FIGURE 378. EXTREME TENDENCY TO PERIODONTOCLASIA OF PATIENT SUFFERING WITH OSTEOMALACIA. THE SYSTEMIC BACKGROUND MAKES THIS CONDITION EASILY PROGRESSIVE AND THEREFORE RESISTANT TO TREATMENT.



FIGURE 379. TWO OPPOSITE TYPES OF REACTION IN CEMENTUM: A, HYPOCEMENTOSIS WITH DESTRUCTION OF CEMENTUM IN OSTEOMALACIA AND SEVERE PERIODONTOCLASIA; B, HYPERCEMENTOSIS WITH EXTREME EXCEMENTOSIS IN PATIENT WITH BROKEN DEFENSE.

the apex is probably approximately four times that of its original. The roentgenographic appearance of this tooth is shown in Figure 432, the mesial root of the upper right molar. This patient was suffering from very acute eye trouble. It would be a physical impossibility for any form of irritant to produce the effect shown in B on any tooth in the mouth of a patient from which the tooth shown in A was extracted until that patient could be changed from the present physical background to that which obtained in the patient from which B was extracted.

We have, therefore, not only the type and quantity of irritant to consider, but we have always the type of reaction and characteristic defensive mechanisms of the host. In Chapters 43 and 44 of Volume 1, I have discussed the relation of the alkalinity index of the blood of these individuals to the ionic calcium and to the type of systemic reaction. We must come finally to view these patients in terms of their blood chemistries and their capacity for metabolic and catabolic processes. The patient from whom A was extracted and whose hand is shown in C of the previous figure was suffering from osteomalacia. That, however, does not mean so much as does the significant fact which is a background to her condition—namely, that her alkalinity index ranged from 26 down to 20—and it is not surprising that when she, as a seamstress, pricked her finger, she was laid up for weeks with a bush-fire type of infection. She is living all the time on the edge of a precipice and her safety lies continually in an intelligent effort to restore normality in so far as possible, first by reducing the acidosis, and for this, while drugs may be ultimately called upon for assistance, the diet is, of course, the first and most essential factor.

CHAPTER LXV.

ALIMENTARY TRACT AND ASSOCIATED ORGANS.

DISCUSSION.

We are grouping together the lesions of the various organs and tissues of the alimentary tract, both because of the biologic classification and because our various studies have shown that susceptibility to the rheumatic group lesions of these tissues seem to show a definite relationship between them. For example, individuals and their families will frequently show susceptibilities in digestive tract only, sometimes as gall-stones, other times as appendicitis, both associated with attacks of indigestion not accounted for by the food, or the latter only. This was illustrated in Chapter 22. Very frequently attacks of acute indigestion, or chronic digestive disturbances affecting either the stomach or the large or small intestines, will be associated with acute nervous disturbances. We have thought of these as being largely due to irritation of the sympathetic nervous system. This view, however, does not explain some strange things that have come out in our animal inoculations. One of these is illustrated in Case No. 965.

Case No. 965.—This woman, age forty-three, virtually had been an invalid for about six years, her affliction expressing itself chiefly as nervousness, neuritis, nervous indigestion, associated with neuralgic pains at the waist-line. There was marked evidence of a susceptibility of these tissues from the mother's side, as shown in the susceptibility chart Figure 380. The father is still living at eighty-four and the father's side of the ancestry has been free from rheumatic group lesions. Her mother had died at seventy-seven and her mother's father and mother were ninety-four and seventy respectively, indicating that there had been a great deal of endurance in the mother's family. The difference between the actual conditions and those indicated in the roentgenograms was very great. In Chapter 1, Figure 4, we used a tooth from this case to illustrate the inability of the roentgenogram to disclose even an extensive granuloma if it is surrounded by a zone of dense condensing osteitis. The complete set of

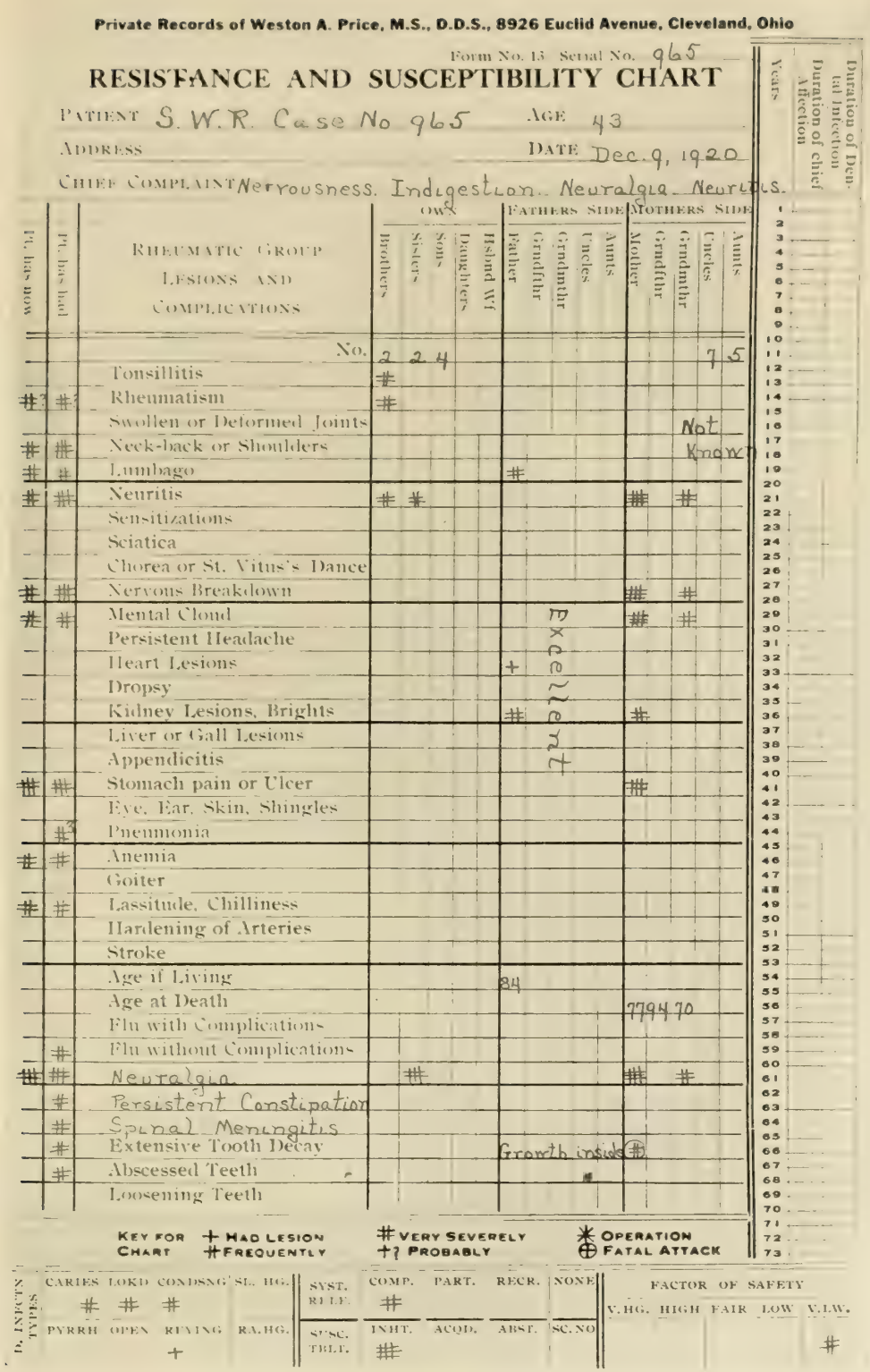

Private Records of Weston A. Price, M.S., D.D.S., 8926 Euclid Avenue, Cleveland, Ohio

Form No. 13 Serial No. 965

RESISTANCE AND SUSCEPTIBILITY CHART

PATIENT S. W. R. Case No 965 AGE 43

ADDRESS DATE Dec. 9, 1920

CHIEF COMPLAINT Nervousness. Indigestion. Neuralgia. Neuritis.

Pt. has now	Pt. has had	Rheumatic Group Lesions and Complications	Own: Brothers	Own: Sisters	Own: Sons	Own: Daughters	Own: Hsband Wf	Father's Side: Father	Father's Side: Grndfthr	Father's Side: Grndmthr	Father's Side: Uncles	Father's Side: Aunts	Mother's Side: Mother	Mother's Side: Grndfthr	Mother's Side: Grndmthr	Mother's Side: Uncles	Mother's Side: Aunts
		No.	2	2	4											7	5
		Tonsillitis	#														
#?	#?	Rheumatism	#														
		Swollen or Deformed Joints														Not Known	
#	##	Neck-back or Shoulders															
#	#	Lumbago						#									
#	##	Neuritis	#	#									##		#		
		Sensitizations															
		Sciatica															
		Chorea or St. Vitus's Dance															
#	##	Nervous Breakdown											##		#		
#	#	Mental Cloud											##		#		
		Persistent Headache															
		Heart Lesions						+									
		Dropsy															
		Kidney Lesions, Brights						#					#				
		Liver or Gall Lesions															
		Appendicitis															
##	##	Stomach pain or Ulcer											##				
		Eye, Ear, Skin, Shingles															
	#?	Pneumonia															
#	#	Anemia															
		Goiter															
#	#	Lassitude, Chilliness															
		Hardening of Arteries															
		Stroke															
		Age if Living						84									
		Age at Death											77	94	70		
		Flu with Complications															
	#	Flu without Complications															
##	##	Neuralgia		#									##		#		
	#	Persistent Constipation															
	#	Spinal Meningitis															
	#	Extensive Tooth Decay						Growth inside #									
	#	Abscessed Teeth															
		Loosening Teeth															

Duration of Dental Infection — Duration of chief Affection — Years

Excellent

KEY FOR CHART: + Had Lesion; # Frequently; #? Very Severely; +? Probably; ✳ Operation; ⊕ Fatal Attack

D. INFCTN TYPES: CARIES LOKD CONDSNG SL. HG. # # # PYRRH OPEN RFATNG RA.HG. +

SYST. RELF. # SUSC. TBLT. ## | COMP. INHT. | PART. ACQD. | RECR. ABST. | NONE SC. NO

FACTOR OF SAFETY: V.HG. HIGH FAIR LOW V.LW. #

FIGURE 380. SUSCEPTIBILITY STUDY SHOWING MARKED INHERITED SUSCEPTIBILITY FROM MOTHER'S SIDE FOR NEURITIS, NERVOUS BREAKDOWN, AND STOMACH TROUBLE. CASE NO. 965.

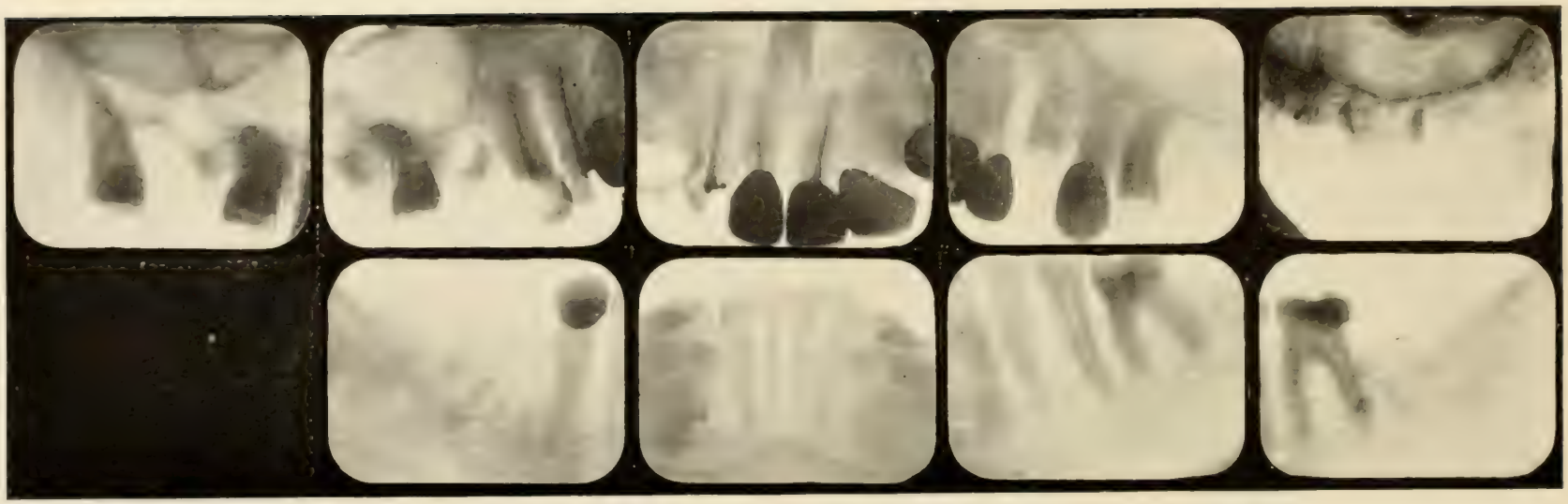

FIGURE 381. ROENTGENOGRAPHIC APPEARANCE OF TEETH OF CASE NO. 965 WITH STOMACH AND NERVOUS DISTURBANCE.



FIGURE 382. ACUTE STOMACH ULCER WITH NEAR PERFORATION, OF A RABBIT INOCULATED WITH CULTURE FROM A TOOTH OF CASE NO. 965 WITH STOMACH INVOLVEMENT.

roentgenograms is shown in Figure 381. In few cases have we found so extreme condensing osteitis as about all these upper teeth, all of which were extracted, and all of which had conditions very much worse than could be anticipated from the roentgenograms. Continued low defense for a few years will practically always, in this type of case, produce marked condensing osteitis. In other chapters, we have discussed the relation of this calcium metabolism factor to disturbed defense. Doubtless, most all dentists, who do root-filling work, would have concluded, regarding the tooth shown in Figure 4, that they could safely fill this root and that there was no serious periapical involvement. They would be overlooking two fundamentals: First, that they are not correctly judging the condition about the apex from the appearance in the roentgenogram; and unless they have checked their work by other means than recording symptoms and comfort on the part of the patient, they would not know either their relative or actual efficiency in removing the infection from this root. The facts are that with the removal of these upper teeth, this woman, who had been an invalid for about six years, was so greatly improved in health, and that very rapidly, that she again took up her complete household duties and has had continued good health for the four years since these teeth were removed. A culture taken from these teeth and inoculated into a rabbit produced an acute stomach ulcer with perforation, shown at the point of the arrow in Figure 382. Two rabbits were inoculated, both of which developed lesions of the digestive tract which was the tissue involved in the patient. This one died in seven days, the principal lesion being this peptic ulcer with perforation. With no other treatment this patient gained fifteen pounds in weight in a few months' time. In about 1100 rabbits inoculated in the last two and one-half years, stomach perforation has not been found in ½ of 1 per cent of the rabbits.

The next case also shows a very marked elective localization for stomach tissue. As in the last case, other symptoms so overshadowed the digestive disturbance that the patient did not think of that as the chief trouble. This patient's chief affection was an involvement of her eyes with marked exophthalmos, not her chief eye trouble, however, which was attacks of pain which would be so severe that on several occasions a physician had to be summoned in the night to give her a hypodermic injection of morphine. The paroxysms of pain were so nearly unbearable that her health would be injured for days or weeks after an at-

tack, which would last for hours, unless morphine was injected. This phase of her case is reported in detail in the chapter on this subject. However, we wish to note here that the animals inoculated, as shown in that chapter, developed both rupture of blood vessels in the eyes and marked exophthalmos, as shown in the photographs. Three of the rabbits inoculated with the strain taken from her mouth developed very unusual and extreme lesions in the digestive tract with perforation, or near perforation; while several others, developed very acute colitis, dying from the inflammatory process of the digestive tract. Figure No. 383 shows the viscera from all of the three rabbits. A shows a complete perforation of the stomach and contiguous diaphragm with a bolus of food penetrating the rupture into the thorax. B, when posted, had such an extensive ulceration of the cardiac end of the stomach that it was almost ready to perforate. C shows an ulcer of the colon also nearly perforated.

It is very significant that, whereas 69 per cent of the rabbits inoculated with the cultures from this patient's teeth, developed lesions in the digestive tract, and in many instances in several tissues of the digestive tract, and, whereas, 62 per cent of these rabbits developed eye lesions, the percentage of rabbits developing lesions of the digestive tract in the group shown in Chart 143, Chapter 22, "Summary of Animal Reactions and Patients' Symptoms," which is a miscellaneous group involving affections of all kinds, including the stomach, was found to be 36, and in the group where the chief lesion of the patient was rheumatism, the percentage of digestive tract lesions is 18.

The marked improvement in this patient's health has emphasized the need of greater care in the study of the relation of old chronic periodontoclasia pockets to health. This patient at one time had had acute periodontoclasia, or pyorrhea alveolaris, which responded well to treatment; and she thought the disease was cured. At the time of her active reaction, visible pus was present about these teeth. This completely disappeared. The condition of the teeth is shown in Figure No. 439; and, in several, pulps were found degenerated and infected. Some of the old periodontoclasia pockets had necrotic bone and furnished a bad type of focal infection, the original active local reaction having entirely ceased, which, if present, would have protected the patient. The lower left first molar had a degenerated and infected pulp. Very slight evidence of it is shown in the roentgenogram.



FIGURE 383. POSTINGS FROM THREE RABBITS INOCULATED WITH A CULTURE FROM THE TEETH OF A PATIENT SUFFERING FROM SPONTANEOUS HEMORRHAGES. A SHOWS A COMPLETE PERFORATION OF A RABBIT'S STOMACH; B, A STOMACH JUST READY TO PERFORATE; C, A NEAR PERFORATION OF COLON.

The patient had such great relief from the removal of the first few infected teeth, expressing itself both in the absence from the attacks of acute pain and the reduction in the bulging of the eyes, that she became desperate in her determination to have all of her teeth extracted. Finally all of the uppers were extracted and such of the lowers as were found to be abnormal, both in the reactions of the pulp and the health of the supporting structures. In approximately two years, she has not had one single attack of the pain in her eyes. She had a few very slight ones during the early period while the teeth were being extracted. Her general health and digestive function are greatly improved. I question if all of the gifts of the world could induce this woman to have these teeth back. The remarkable change in the appearance of her eyes and the effect upon the rabbit's eyes should be read in connection with this chapter by turning to Chapter 66.

One of the most common of the disturbances of the digestive tract is the group affecting the gall-bladder and duct. There may be many contributing factors in the production of cholecystitis and cholelithiasis. A striking illustration of this is shown in Case No. 1048.

Case No. 1048.—This patient had been suffering from pain and nausea for which she had been advised to go to the hospital for operation. A lower molar tooth, with very marked condensing osteitis, as evidenced at the time of extraction, was removed and cultured and the organisms inoculated into rabbits. The effect on the patient of the extraction of this and two other teeth was that the distress of the gall-bladder quite rapidly disappeared. She soon gained twelve pounds in weight and for two and one-half years since the removal of her dental infection has had no return of the digestive and gall-bladder symptoms. The effect of the inoculation of this culture into rabbits is shown in Figure No. 384. It was to produce a very acute inflammatory involvement of the gall-bladder. It was enlarged and distended with a purulent fluid found to contain a strain of streptococcus similar to that inoculated, and the wall of the gall-bladder had a great many little ulcers, also shown in Figure 384. This rabbit also developed acute appendicitis, as shown in Figure 385, and a very unusual and remarkable lesion, an inflammatory invagination of the cecum into the colon, shown also in Figure 385 at B.

We have had many very striking illustrations of appendix and gall-bladder involvement and their relief by the removal of in-



FIGURE 384. MULTIPLE ABSCESSES IN THE WALL OF THE GALL-BLADDER OF A RABBIT, PRODUCED BY INOCULATION WITH THE CULTURE FROM A TOOTH OF A PATIENT SCHEDULED FOR GALL-BLADDER OPERATION. SYMPTOMS ENTIRELY DISAPPEARED AFTER REMOVAL OF DENTAL INFECTION. NO RETURN OF SYMPTOMS IN TWO AND ONE-HALF YEARS. CASE NO. 1048.



FIGURE 385. DIGESTIVE TRACT INVOLVEMENTS OF RABBIT OF PREVIOUS FIGURE: A, NON-VITAL MOLAR; B, GALL-BLADDER INVOLVEMENT; C, ACUTE APPENDICITIS; D, AN INFLAMMATORY INVAGINATION OF THE CECUM INTO THE COLON.

fected teeth. In one of these, Case No. 445, the patient was supposed to be dying from heart lesions. After she had been in extremely low condition for some weeks, she was taken with acute pain in the bile duct, tenderness over the liver, followed by the passage of a number of gall stones, after which her condition very rapidly improved. This condition repeated, though not quite so

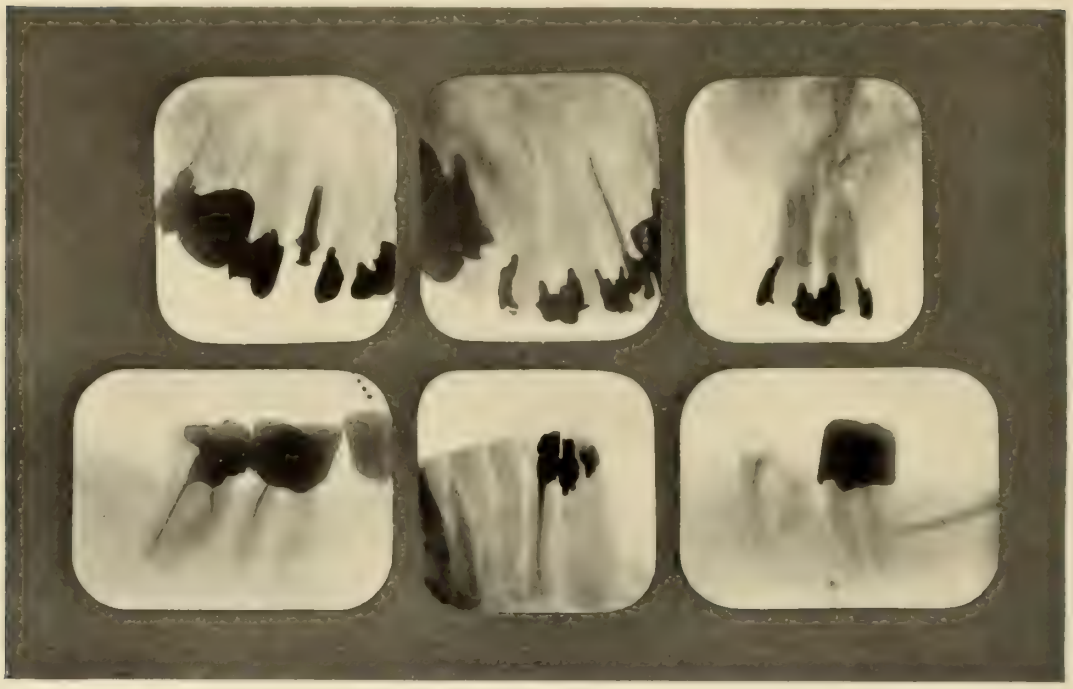

FIGURE 386. SERIOUS DENTAL INFECTIONS WITH LITTLE LOCAL EVIDENCE, WHICH CONTRIBUTED TO A VERY SEVERE CHOLECYSTITIS. CASE NO. 445.

severely, three times in about as many years. We finally removed several infected teeth, one of which is shown in Fig. 386 and which we have previously illustrated in connection with Chapter 3. This central incisor had a putrescent pulp which was not disclosed by the roentgenogram. For two and one-half years she has had no return of either the heart or gall-bladder disturbances, and is again doing her household duties, and apparently in splendid health. Her factor of safety is, however, small.

Case No. 525.—Some years ago, when I also was in the vigor of a mistaken confidence of my ability as an operator, and because I thought I could mechanically cleanse canals and could mechanically make restorations that were both serviceable and comfortable and therefore presumably safe, I undertook to repair a number of infected teeth for a patient who was loath to give them up, and particularly so, since they were so comfortable and efficient for mastication. The courage of a mistaken confidence is not less than when it is correctly placed. During one year while repairing this man's teeth, he had approximately twenty attacks of appendicitis; and on two occasions, arrangements were made to rush him to the hospital for removal of his appendix on nights following dental operations of the day before for treatments of his

teeth. During these months his appendix was so tender that it was painful and difficult for him to ride in an automobile. Fortunately, I discovered this relationship between his reactions and my operations, though they were not suspected by either the physician or the patient. We decided to remove the infected teeth. This entirely removed his appendix trouble and there has been no further suggestion of need for operation. This incident happened about fifteen years ago. Later, when he developed a questionable dental condition, he was suffering from a neuritis. In order to test a possible relationship between the dental condition and his neuritis, we purposely stirred up the infection slightly and did nothing else. For a week he was not able to put on or take off his own coat. The tooth was extracted and his neuritis promptly cleared up and has not returned.

Still another case of digestive tract lesion is particularly instructive. This patient had been suffering for years from gall-stones. On several periods she had gone to the hospital for treatment. We started to treat her teeth and she was not able to come to the office for a day or two because of an acute attack of inflammation of the gall-bladder. We decided to extract the teeth, which we did. This was followed that night by a very acute attack of pain in the gall-duct, requiring medical care, and arrangements were made for surgical interference. Within twenty-four hours, she passed fifty-two gall-stones. We, accordingly, removed all infected teeth. While this woman had not had a month for five years in which she had not had some trouble, (sometimes extremely severe, putting her in bed,) prior to the removal of those teeth, she has not had a single severe attack and very few symptoms in the six years that have intervened since. Figure 387 shows the condition of the teeth in this patient's mouth. The condition, however, as is so often the case, was worse than would be interpreted from the roentgenograms. Note the open canals above crowned teeth, with very slight apical absorption in centrals, lateral, and upper right first bicuspid. The apical reaction is much less than should occur with this quantity of infection if an adequate quarantine is being maintained about the tooth. In this case, as in all this type, the absence of this adequate local reaction means the absence of apical absorption of bone and the passage of this infection beyond this first natural barrier to all the tissues of the body, with the result that the most susceptible tissue breaks, in this case the bile bladder and duct.



FIGURE 387. ROENTGENOGRAPHIC APPEARANCE OF DENTAL INFECTIONS OF A PATIENT SUFFERING FROM CHRONIC CHOLECYSTITIS. FOLLOWING EXTRACTIONS, PATIENT PASSED FIFTY-TWO GALL-STONES.

INTESTINES.

Of the disturbances of the digestive tract, probably none are more frequent or so obscure as to their etiology, than are the disturbances of the large and small intestines. Time after time, we have had as part of our patient's history the development of very acute diarrhea or constipation, preceding or following the treatment of dental infections. These symptoms relate to gingival infections as well as to apical involvements and they take on an entirely new interest and meaning in the light of our animal inoculations, since so often similar disturbances are produced in experimental animals. They are of interest also because the pathological changes produced by each animal inoculation with the organisms grown from the tooth culture, and from the toxic substance taken from teeth, are so similar to changes produced in the viscera by various types of deficiency diets. In the human, dental infections may produce many phases of intestinal disturbance; in some subacute colitis, acute colitis, a spastic condition of the bowel, acute or chronic constipation, which symptoms may be very markedly or completely relieved by the elimination of the

dental infection. These symptoms are frequently very definitely related to the nervous system, as is illustrated by the following case.

Case No. 752.—I was called to the hospital to see this patient by the physician in charge. He was in bed with a very acute neuritis and suffering from a constipation which was exceedingly persistent. According to his history, he had been in a hospital in a neighboring city for several months with a previous attack of acute digestive tract disturbance and constipation that was exceedingly resistant to treatment. The roentgenograms of his teeth are shown in Figure 388. The history of the dental condition



FIGURE 388. DENTAL INFECTIONS RELATED TO INTESTINAL STASIS AND NEURITIS. CASE NO. 752.

is as follows: The lower right first molar had been crowned thirteen years previously, and from its history and the roentgenogram, had been abscessed all these years without fistula. The upper right lateral had a putrescent pulp with a small area of apical rarefaction. There was a history of tenderness thirteen years ago following filling, but none of late years. It has not had a fistula. The upper left first bicuspid with an old root filling shows a periapical involvement. There was a history of tenderness following root filling. The striking feature about his case was that with the removal of the upper right lateral, the upper left first bicuspid, and the lower right first molar, there was a complete clearing up of his neuritis and of his acute constipation. Whereas this patient had suffered continuously for three years previous to the removal of this dental infection, and at times with extreme severity, the effect of the operation was greatly to relieve him. A year or two later he had another attack of colitis,

Private Records of Weston A. Price, M.S., D.D.S., 8926 Euclid Avenue, Cleveland, Ohio

Form No. 15 Series No. 752

RESISTANCE AND SUSCEPTIBILITY CHART

PATIENT R.S.N. Case No. 752 AGE 32

ADDRESS DATE May 7, 919

CHIEF COMPLAINT Pain in back - Stomach.

Temp. 98 Pulse 75

Weight at 18	Present Weight	RHEUMATIC GROUP LESIONS AND COMPLICATIONS	OWN: Brothers	Sisters	Aunts	Husband (Wife)	FATHER'S SIDE: Father	Grandfather	Grandmother	Uncles	Aunts	MOTHER'S SIDE: Mother	Grandfather	Grandmother	Uncles	Aunts
		No.	0	0						0	5					
		Tonsilitis														
	+?	Rheumatism														
		Swollen or Deformed Joints														
	###	Neck-back or Shoulders														
		Lumbago										Excellent				
	##	Neuritis														
		Sensitizations														
		Sciatica														
		Chorea or St. Vitus's Dance														
	#	Nervous Breakdown														
		Mental Cloud														
		Persistent Headache														
		Heart Lesions														
		Dropsy														
		Kidney Lesions, Brights														
		Liver or Gall Lesions														
	*	Appendicitis										(?)				
	###	Stomach pain or Ulcer					⊕	#	#?	⊕						
	+?	Eye, Ear, Skin, Shingles														
		Pneumonia														
		Anemia														
		Goiter														
	##	Lassitude, Chilliness														
		Hardening of Arteries														
		Stroke														
		Age if Living														
		Age at Death					5	0	78	50	40	28	Cause unknown			
		Flu with Complications														
		Flu without Complications														
	#	Persistent Constipation														
	#	Extensive Tooth Decay														
	#	Abscessed Teeth														
		Loosening Teeth														

Years: 1 2 3 4 5 6 7 8 9 10 11 12 13 14 15 16 17 18 19 20 21 22 23 24 25 26 27 28 29 30 31 32 33 34 35 36 37 38 39 40 41 42 43 44 45 46 47 48 49 50 51 52 53 54 55 56 57 58 59 60 61 62 63 64 65 66 67 68 69 70 71 72 73

Duration of Dep. of Infection

Duration of chief Affection

KEY FOR CHART: + HAD LESION; # FREQUENTLY; #? VERY SEVERELY; +? PROBABLY; * OPERATION; ⊕ FATAL ATTACK

CARIES TOXIC CONDNG. SL. HG.		SYST. REFL.	COMP.	PARL.	RECR.	NONE
#	#					
PARRH. GLEN. REFING. RA HG.		SUSC. INFL.	INHIL.	ACOPL.	ATSL.	SC NO
			#			

FACTOR OF SAFETY				
V. HG.	HIGH	FAIR	LOW	V. LW.
				#

FIGURE 389. SUSCEPTIBILITY STUDY OF PREVIOUS CASE, NO. 752. NOTE FIVE CASES OF ACUTE STOMACH INVOLVEMENT ON FATHER'S SIDE, WITH TWO DEATHS.

following an empyema of the antrum, which cleared up with the clearing of his nasal infection, and he is again in good condition. This illustrates how with a susceptible tissue there is a tendency to involvement of that tissue, regardless of the source of focal infection. In this case, the type of dental infection was a series of three locked areas.

A study of his resistance and susceptibility chart is of particular interest. His acute neuritis and digestive tract disturbances, including the acute appendicitis, have all developed since the establishment of the definite history of these dental infections, two of which, as shown in the last column, date back thirteen years and one six years. About one year after the establishment of his dental infections, or twelve years ago, he developed an acute appendicitis; and three years ago, his chronic constipation became very severe and he began a series of hospital sojourns with digestive disturbance and neuritis, the last of which was so acute as to put him to bed. He was not able to raise his hands from the table, so great was the motor involvement. The striking thing about his chart, shown in Figure 389, is that his father died at fifty-six of acute digestive tract disturbance, both his father's father and mother had digestive tract disturbance, and two of his father's sisters also died of acute digestive tract disturbance, one at forty and the other at fifty. Note that he is developing these lesions severely at, and prior to thirty-two years of age. The history of these cases is so often that it develops early in the succeeding generations where very marked in the ancestry of one or both sides. There are, in this family, five cases of, and three deaths from, digestive tract disturbance in the immediate relatives of his father's side. This is a striking illustration of the inheritance of the weak link in the chain and of the involvement of that weak link when a dental infection exists. Note the absence of lesions in other tissues of his and of other members of his family. Another very striking thing about this case is the absence of a tenderness of the teeth and of fistulæ; and the suggestion of an earlier rarefying osteitis of a very moderate degree. Nature was not making an adequate effort in establishing the quarantine about these teeth, and the toxic substance plus the bacterial invasions were entering his system and causing a break in his susceptible tissue.

There are types of intestinal disorders which very strongly suggest that they are sensitization processes. The patient's



A



FIGURE 390. AN ENORMOUS MANDIBULAR CYST WITH MARKED DISPLACEMENT OF THIRD MOLAR, NEARLY TO NECK OF CONDYLOID PROCESS, PRODUCING COLITIS. CASE NO. 1019.

symptom may be an obstinate diarrhea which may have a periodic cycle of recurrence. We have suggested such a case in Chapter 30 on the Nature of Sensitization Reactions. In this case the source of infection was from periodontoclasia pockets. Similar and very distressing disturbances may be produced by the toxic poison from dental cysts. The following is an illustration.

Case No. 1019.—The patient had a very large and very unusual mandibular cyst, shown in Figure 390, A and B. (See great displacement backward and upward of the third molar. Note both views.) She had been having both nervous symptoms and digestive disturbances. A drop of the cyst material was aspirated with a hypodermic for microscopic study and culture. It contained a few organisms and had an abundance of cholesterol crystals. For twenty-four hours before the operation on this cyst, the patient's bowel movements occurred on an average of about thirty minutes, with some griping. At the time of operation, some of the cyst material was inoculated intravenously into a rabbit and it developed an acute diarrhea in about forty minutes. Four rabbits were inoculated. All four developed acute colitis; three developed rheumatism and liver involvement; two gall-bladder, and one stomach involvement in addition. The patient was also suffering from marked rheumatic lameness in her right shoulder. With a thorough irrigation of the cyst chamber and packing for a few days to keep the air from the sensitive structures, particularly the exposed inferior dental nerve, and the removal of the third molar which, as shown, had been pushed backward and upward by the cyst, entirely out of its normal position, the patient's intestinal symptoms entirely disappeared and in two years have not recurred.

The surgical removal of this tooth was a matter of very great difficulty, since the width of the tooth was greater than the thickness of the ramus. It was accomplished, however, under local anæsthetic, with the aid of specially designed and constructed instruments with which I moved the tooth down and forward through the opening in the anterior border of the ramus, while the lateral walls of the ramus were distended to make possible the delivery of the tooth. The method of treating was to allow the mucous membrane of the mouth to extend into the cyst chamber, and the patient was provided with the means for the irrigation, twice daily, of the chamber. If these cysts close over before the pyogenic membrane is displaced with the normal mucous membrane of the mouth, they tend to recur. This premature closing

is prevented by frequently changed light packings in the orifice.

It is, of course, impossible to determine, with certainty, the degree of the specificity in a given case of apparent elective localization. Some very striking conditions have appeared in our experimental animals. In general, elective localizations tend to be much more frequently expressed when cultures are grown quickly and the desired quantity injected intravenously, using as young generations as possible in order that the influence of the new medium may not have destroyed these qualities. We have, accordingly, found that when teeth are implanted beneath the skin, they tend to produce such grave changes in the morphology and chemistry of the blood as to overwhelm the animal before clear cut localizations appear. Notwithstanding this fact, many of these animals develop involvements of special tissues, an illustration of which is the following case:

Case No. 1353.—The patient, forty-nine years of age, was suffering from sleeplessness, general nervousness, and an abdominal distress that was giving him much anxiety since it had developed near the site of the operation for an appendectomy. His dental conditions included several quite badly involved, deep periodontoclasia pockets, with some apical involvement. The second molar, shown in Figure 391, was implanted beneath the skin of a rabbit which died with acute appendicitis. The tooth was planted under the skin of another rabbit which also died with acute appendicitis. The appendices of these two rabbits are shown in Figure 391. But this is not more striking than the fact, that with removal of his dental infections, his abdominal distress and pain disappeared and has not recurred for many months. It is my interpretation in the light of my present knowledge that the infected tooth placed beneath the skin furnished both toxin and bacteria which invaded his body and which localized in tissues similar to those already sensitized in the patient's body.

I have shown in the Chapter on Circulatory System, a rabbit that was given one inoculation in the margin of the ear vein, consisting of about 1 cc. of a twenty-four hour broth culture grown from the root of a tooth of a patient suffering from acute rheumatism and which developed acute rheumatism resulting in deforming arthritis. This rabbit lived for approximately two and one-half years, was crippled, and moved about like an old man with typical deforming arthritis. His toes were turned in and he



FIGURE 391. ACUTE APPENDICITIS PRODUCED IN TWO RABBITS IN SUCCESSION BY PLANTING OF SAME TOOTH BENEATH THE SKIN, TAKEN FROM PATIENT SUFFERING FROM PAIN IN VICINITY OF PREVIOUS APPENDIX OPERATION.

walked on the sides of his feet. When this rabbit died, it was from a streptococcal peritonitis with extensive adhesions. The joint involvements had, apparently, been walled off and except for the deformity were quiescent. I refer to this case as a suggestion, and perhaps an illustration, of how infections, that have become walled off or focal in the system, may develop extensive adhesions by their secondary involvement of peritoneal tissues.



FIGURE 392. INTERNAL AND EXTERNAL APPEARANCE OF ACUTELY INVOLVED APPENDIX OF A RABBIT WITH TOOTH IMPLANTED BENEATH ITS SKIN, FROM CASE NO. 1346 SUFFERING FROM A DIGESTIVE DISTURBANCE.

It is, therefore, not improbable that this may have been the nature of the disturbance that was going on in this patient's body, expressing itself as pain quite typically like the postsurgical adhesion distresses following appendectomies and other abdominal operations. I would also stress that we may have here one of the etiological factors in the various adhesions that develop in the abdominal tissues.

Another case which is also very striking is the following: This patient, Case No. 1346, had a very serious physical break, becoming progressively worse for three years, until he was practically incapacitated for duties. The chief expression of his difficulty was pain about his heart, particularly after eating, so severe that he could not walk a block, and he even avoided the exertion of conversation for some time after eating. He had had many examinations, and the interpretation had been that he was suffering

from myocarditis with a digestive involvement. He had been put on a very rigid diet. We have discussed his case from the cardiac standpoint in the Chapter on the Circulatory System, and recorded there the most remarkable improvement he made following the removal of his dental infections and special treatment, which latter was outlined in Chapter 22 on Elective Localizations. I have shown how there seemed to be a relation between the fact, that he had a most obstinate secondary recurrent hemorrhage following his first extraction, and the development of spontaneous hemorrhages in a large group of rabbits inoculated with the culture grown from his teeth. The point of special interest here is that when one of his teeth was planted beneath the skin of a rabbit, it died with a very acute appendicitis. Internal and external views of this appendix are shown in Figure 392. One of the rabbits inoculated with the culture, the one receiving the youngest culture, therefore retaining most largely the specific qualities of the organism, developed in addition to the extensive spontaneous hemorrhages, of which it died in twelve hours, hemorrhages into the muscular coat of the stomach, one of which already showed signs of necrosis, which was clearly not a postmortem change. This is shown in Figure 393.

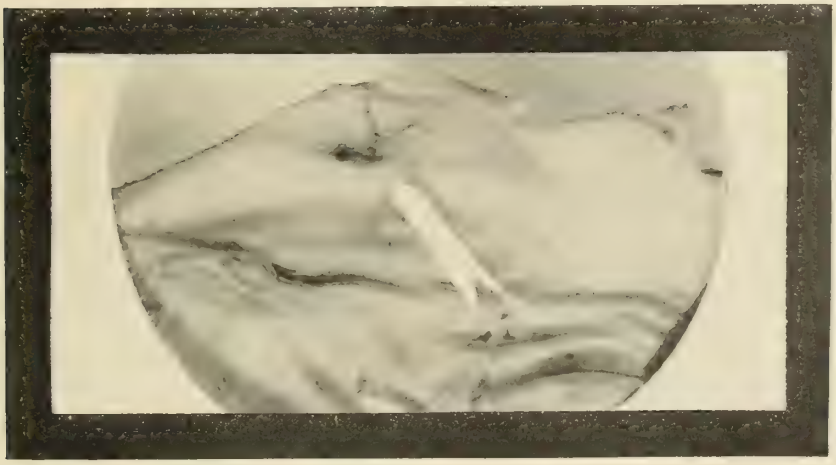

FIGURE 393. STOMACH ULCER PRODUCED IN RABBIT BY TOOTH IMPLANTATION, CASE NO. 1346 WITH STOMACH INVOLVEMENT.

We cannot pass the chapter on the digestive tract disturbances without discussing another type of disturbance of the digestive tract which is perhaps the most dreaded enemy of mankind: namely, cancer of the stomach. In Chapter 31, on Precancerous

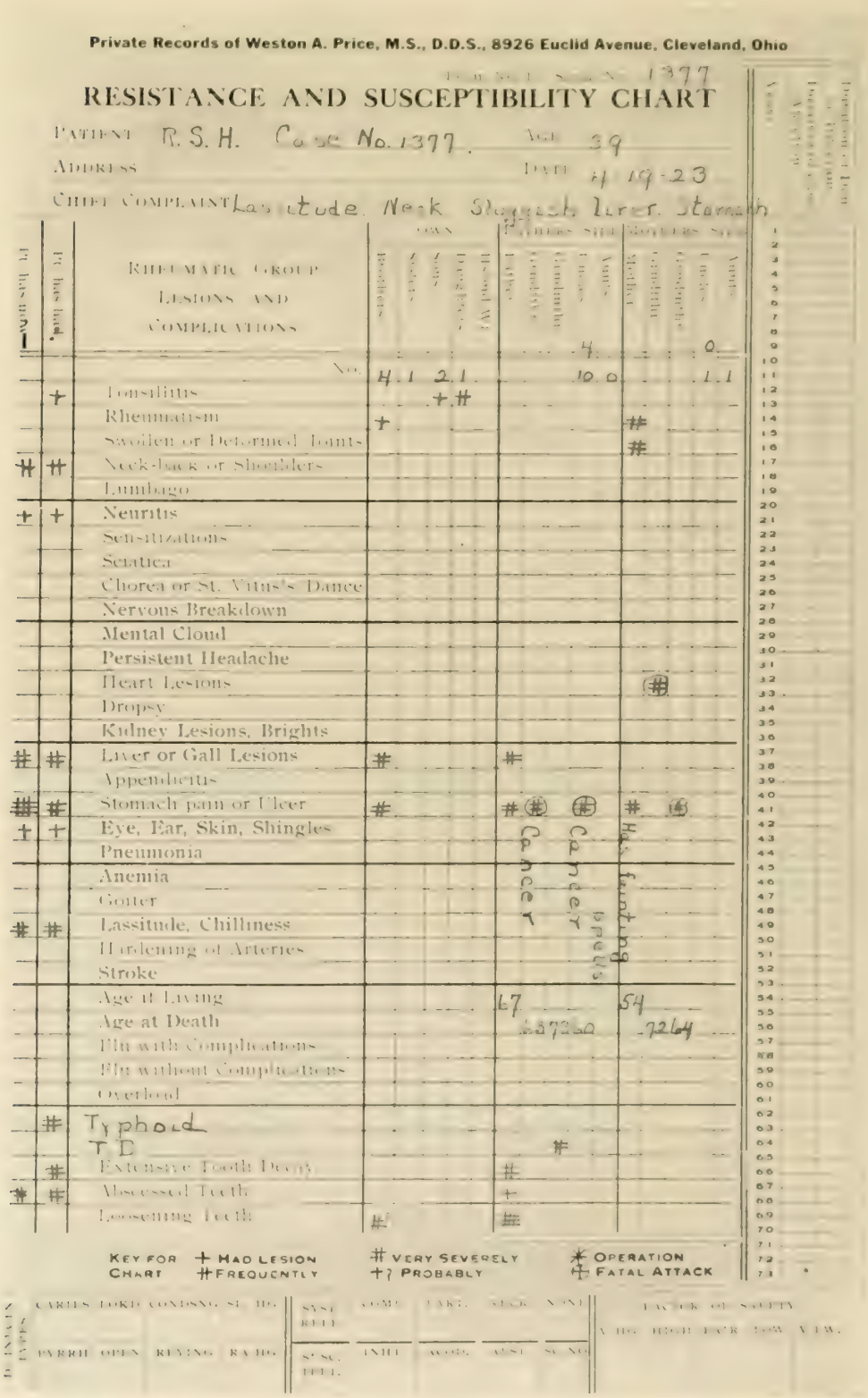

Private Records of Weston A. Price, M.S., D.D.S., 8926 Euclid Avenue, Cleveland, Ohio

RESISTANCE AND SUSCEPTIBILITY CHART

PATIENT R. S. H. Case No. 1377. AGE 39

ADDRESS DATE 4-19-23

CHIEF COMPLAINT Lassitude. Neck Stomach Liver. Stomach

Rheumatic Group Lesions and Complications	Teeth Removed	Teeth Filled	Teeth Devitalized	Teeth Abscessed	Teeth Extracted	Upper Teeth Treated	Upper Teeth Crowned	Upper Teeth Extracted	Upper Teeth Lost	Lower Teeth Treated	Lower Teeth Crowned	Lower Teeth Extracted	Lower Teeth Lost
								4				0	
No.		4.1	2.1					10.0				1.1	
Tonsilitis	+		+.#										
Rheumatism		+								#			
Swollen or Deformed Joints										#			
Neck-back or Shoulders	#	#											
Lumbago													
Neuritis	+	+											
Sensitizations													
Sciatica													
Chorea or St. Vitus's Dance													
Nervous Breakdown													
Mental Cloud													
Persistent Headache													
Heart Lesions										(#)			
Dropsy													
Kidney Lesions, Brights													
Liver or Gall Lesions	#	#	#			#							
Appendicitis													
Stomach pain or Ulcer	#	#	#			#	(#)	(#)		#	(#)		
Eye, Ear, Skin, Shingles	+	+				Cancer		Cancer		Has hunting spells			
Pneumonia													
Anemia													
Goiter													
Lassitude, Chilliness	#	#											
Hardening of Arteries													
Stroke													
Age at Living						67				54			
Age at Death						1837250				1872 64			
Flu with Complications													
Flu without Complications													
Overload													
Typhoid		#											
T D							#						
Extensive Tooth Decay		#				#							
Abscessed Teeth	*	#				+							
Loosening Teeth			#'			##							

KEY FOR CHART: + MAD LESION; # VERY SEVERELY; * OPERATION; # FREQUENTLY; +? PROBABLY; † FATAL ATTACK

FIGURE 394. A REMARKABLE INSTANCE OF INHERITED SUSCEPTIBILITY FOR STOMACH INVOLVEMENT. NOTE SIX OF PATIENT'S IMMEDIATE RELATIVES SUFFERED FROM SAME, WITH THREE DEATHS.

Conditions, I have presented evidence which suggests to me some form of anaphylactic reaction of tissues of various parts of the body, particularly the skin, which seemed to be related to precancerous conditions, and in which the exciting antigen is, in certain cases, a toxic substance of dental origin. I have, in that chapter, referred to the fact, that cancers of the stomach, as suggested by Dr. Charles Mayo, seem definitely to be related to the scars of stomach ulcers, and also to the fact, that in our susceptibility studies of patients and their families I have found that, by selecting out only the cases where the records seem complete enough to justify some conclusions, cancers were four times as prevalent in the group with an absent or acquired susceptibility as in the group with a streptococcal inherited susceptibility, and that this corresponds with the groups in which we find practically all of our cases of sensitizations. In Figure 394, I present a striking resistance and susceptibility chart. This patient, age thirty-nine, presents with acute digestive tract disturbance. He has four brothers, one of whom is similarly affected. His father is similarly affected. His father's father and his father's brother were similarly affected and died of cancer of the stomach. His father's mother has stomach disturbance and his mother's mother died of acute stomach involvement. In other words, we have, in this family, seven cases of acute stomach involvement, three terminating in death and two distinctly as cancer of the stomach. I do not interpret this to mean that cancer of the stomach, as such, is inherited, but that a type of susceptibility to sensitization reaction has been inherited, and, further, that the defensive elements of the stomach itself, have, by inheritance, been defective, tending to determine the site of the localization of the sensitization. I do not present this as based upon sufficient experimental data to be ready for acceptance, but as the simplest explanation of the phenomena I am here presenting.

CHAPTER LXVI.

NERVOUS SYSTEM AND SENSE ORGANS.

DISCUSSION.

It is quite remarkable to me that notwithstanding the fact, that I have been making an intensive study of oral infections and their systemic expressions for over twenty-five years, nearly all of the involvements of the nervous system escaped me during the early part of this period, and this notwithstanding we now find more disturbances of the nervous system than of any other type of tissue. One of my early cases in which I found an unmistakable connection was as follows:

Case No. 110.—The patient, then about fifty years of age, was suffering from an involvement of the muscles of the side of her neck, a type of torticollis, though differing in that the spasm was not constant. She stated that her only recognition of the developing involvement was that in church she could not keep her head from going over sideways and was compelled to brace it with her hand to keep it upright. It was not rotated as usual. She went to a photographer to have her picture taken and he was compelled to support her head to keep it from gradually going over to the side. This involvement was on the left side. After studying her case, I condemned the lower left second bicuspid shown in Figure 395,



FIGURE 395. A DENTAL INFECTION WHICH PRODUCED A TIPPING OF THE HEAD, COMPLETELY RELIEVED BY THE EXTRACTION OF THE BICUSPID. CASE NO. 110.

which, as will be noted, had a very marked condensing osteitis and which, of course, I did not understand and appreciate at that time. With the removal of this tooth, her trouble was entirely corrected.

Compared with the information available at that time, we have learned that there are very many disturbances of the nervous

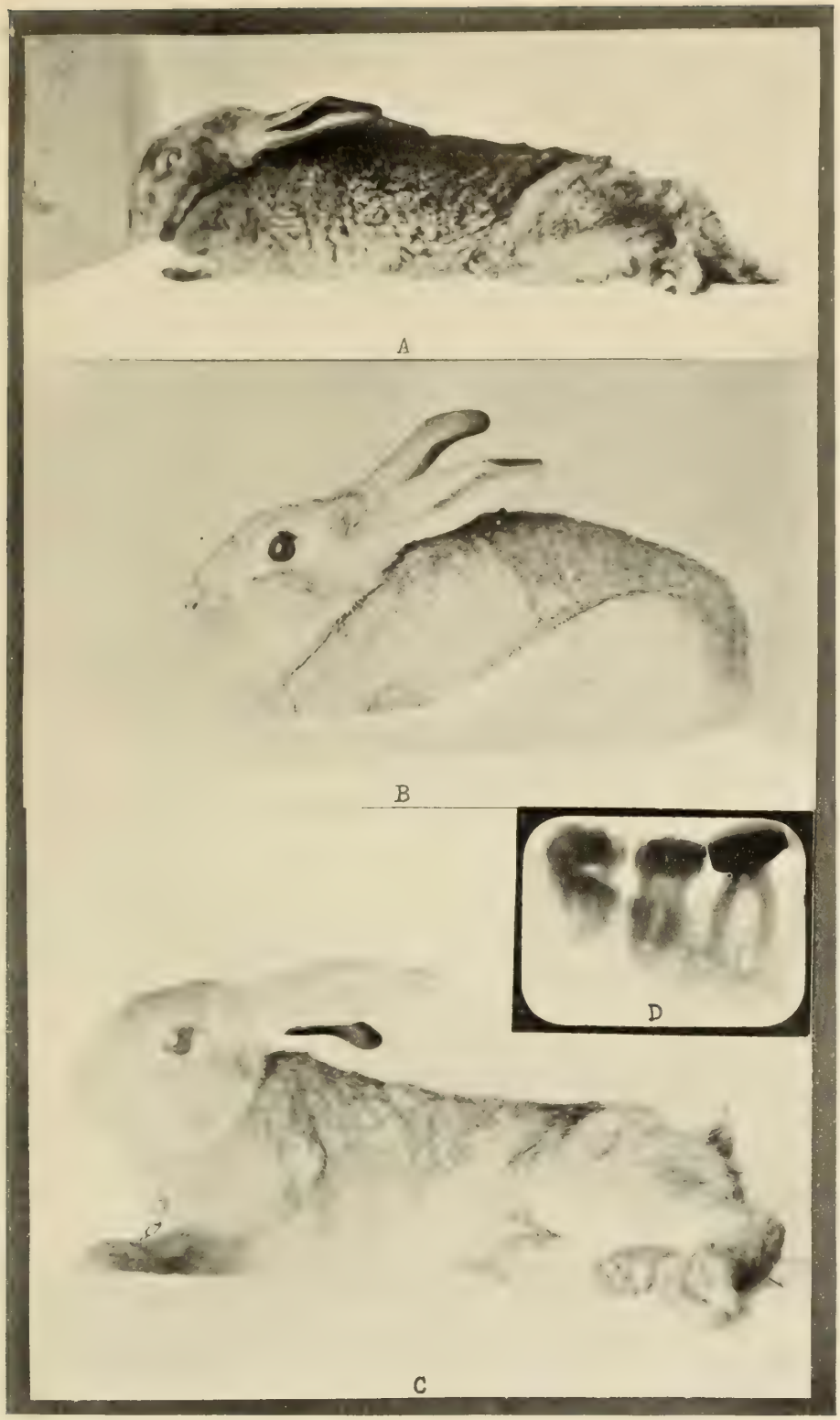

FIGURE 396. FOUR RABBITS WERE INOCULATED WITH THE CULTURE FROM THE TOOTH SHOWN IN D, THREE OF WHICH WERE COMPLETELY PARALYZED FROM THE CENTERS OF THEIR SPINES BACKWARD, AS SHOWN IN A, B, AND C. PATIENT SUFFERED FROM SPASMS. CASE NO. 1001.



FIGURE 337. PARALYZED RABBIT A AND B. C. AN ULCER ON INNER SURFACE OF ITS BLADDER, SHOWN IN NEXT FIGURE.

system, both motor and sensory, and particularly of the neck and shoulders; but compared with the great amount of information that is needed, we yet know but little. As stated in the Chapter on Skeletal and Muscular System (Chapter 64) in discussing neck involvements, our histopathological studies of lesions produced in animals revealed marked lesions in both the muscle and nerve tissues, not always in both and the same case; and in no part of our work has our animal inoculation part of the study thrown so much direct information as in the study of the lesions of the nervous system; nor could evidence of elective localization be much more marked than in some of these cases. This is strikingly illustrated in the following case.

Case No. 1001.—This patient was suffering from disturbances of the central nervous system, which expressed themselves with loss of both motor and sensory control for from a few minutes to half an hour, followed by a marked interference with motor control for several hours. This disturbance was so severe that she was compelled to give up her position. The attacks were becoming more frequent. The lower left first molar, shown in Figure 396-D, was condemned. Note a distinct zone of condensing osteitis apparently surrounding a zone of rarefying osteitis, which condition indicates to me both a considerable amount of infection and a very inadequate reaction in the tissue surrounding the tooth. This patient is not, while in this condition, producing an adequate quarantine about the tooth for her self-protection. This tooth was extracted and with much difficulty, owing to this condensing osteitis. This type of socket tends always to be slow in healing, as we have discussed elsewhere. Cultures taken from this tooth were inoculated into four rabbits, and three of them were completely paralyzed from the center of their bodies backward, including sphincters, abdominal muscles, and sciatics. Both motor and sensory groups were affected. These three rabbits are shown in their living state in Figure 396. They did not lose, seriously, in weight; their appetites were good; and they kept well nourished. They dragged their hinder parts as though they did not belong to them. There was no control of urine or fæces. The rabbit shown in 397-A is shown in dissection after being chloroformed in Figure 398. Very marked lesions were found in the spinal cord and sciatics, both within the spinal column and outside, shown in Figure 398-D. The bladder of this rabbit was found to contain about twenty times the normal amount of urine,



FIGURE 398. SITE OF LESION IN SPINAL NERVES IN D. E. THE PARALYZED BLADDER TWENTY TIMES NORMAL SIZE.



FIGURE 399. PHOTOGRAPHIC APPEARANCE OF VENTRAL SURFACE OF SPINE, WITH ONE DESTROYED CARTILAGE.

being enormously distended. Apparently the same strain of organism that was grown from the tooth and inoculated into the rabbit was abundant in the bladder. The internal surface of the bladder showing a very large ulcerative area is shown in Figure 397-C. The ulcers on the inner surface of the bladder are shown in Figure 397-C. The complete relaxation and helplessness of the hinder parts of the rabbit are shown in the two views of 397, which were the normal positions before posting. The rabbit shown in Figure 400-C is also shown in section in Figure 400-B.



FIGURE 400. ANOTHER PARALYZED RABBIT OF THIS SERIES. A, ROENTGENOGRAPHIC APPEARANCE OF SPINE. NOTE CONDENSING OSTEITIS. B, COMPRESSION OF SPINAL CORD BY PROLIFERATIVE OSTEITIS. C, EXTERNAL APPEARANCE OF RABBIT.

C shows a definitely developed deformity in the spine. Figure 399 shows a dissection of the spinal column from the ventral surface. Note that the second lumbar cartilage is absent, there being a distinct lesion in the body of both second and third vertebræ. A dissection, exposing a lateral view of the spinal cord at this point, is shown in Figure 400-B. Note a marked displacement and curvature in the spinal column with a compression of the spinal cord at the point of the infective process. All nerves, motor and sensory, beyond the point of this compression were paralyzed. A roentgenogram of this lesion is shown in Figure 400-A. Note particularly, as we have called attention to in Chapter 64 on condensing and rarefying osteitis, this lesion is not revealed as a zone of rarefaction, but one of condensation; and with the destruction of the cartilage and the involvement of the body of the adjoining vertebræ, there is a partial dislocation. We have here an evidence of the experimental development of a type of Pott's disease which may be analogous to some of those obscure spinal lesions which develop in children, many of which are definitely known not to be tubercular.

In many respects the pathology of these animals is very similar to that of the rabbit presented in Chapter 64, Figures 347 and 348. We wish to review that case in connection with the nervous system. The intravenous inoculation of this rabbit with the culture grown from the embedded root of a tooth of a patient that had been bedridden for some years, developed a complete paralysis from the center of the spine backward, which, while complete for both motor and sensory nerves, gradually disappeared, leaving the animal with a disturbed gait much like a child who has had anterior poliomyelitis. The roentgenograms of this animal's spine show very clearly the location of the lesion, as does also the dissection shown in photograph in Figure 348. In the Chapters on Pregnancy, and Primary and Secondary Sex Organs, we have discussed this case because of the very marked nervous disturbance that developed in this rabbit which had become apparently normal, physically, so far as its original streptococcal infection was concerned. That overload was sufficient to bring on in a very acute form a very marked central nervous system disturbance, as, for example, with excitement such as the clapping of the hands near the rabbit, it would fall over on its side. It became very emaciated after its confinement, at which time its five young died in from a few hours to two days; and the rabbit went



FIGURE 401. LESIONS IN THE CORTEX OF THE BRAIN, RABBIT WHICH DEVELOPED ACUTE CHOREIC NERVOUS SYMPTOMS, SHOWN IN FIGURE 347.

into a rapid nervous decline, dying in about a month from terminal pneumonia. A of Figure 401 shows high power studies of the spinal cord and nerve tissues of this rabbit. B shows a section of the cortex of the brain. Figure 348 shows a roentgenogram of the spinal cord of this case.

Our many studies on animals have revealed a definite tendency on the part of the organisms, taken from dental infections of patients with central nervous system disturbances, to produce nervous disturbances in rabbits and a tendency to rarefying osteitis.

It is probable that very many more lesions of the brain are caused by streptococcal infections than are recognized. These tend frequently to express themselves with choreic movements which, because of their motor expressions are, of course, recognizable, though their etiology may not be. When, however, brain disturbances are of such a type as to disturb function rather than motor control, the lesion is probably generally thought of as being physiologic rather than pathological; and it now seems probable that disfunction of the brain cannot exist without a structural pathological counterpart and cause. We, accordingly, studied the brain of this rabbit with a great deal of interest and detail. The following is the pathologist's detailed histopathological study.

"Rabbit X. Brain Tissue from One of the Hemispheres. Microscopic Study.

"*Inverted Ocular.*—The section shows an irregularly-shaped piece of tissue, stained with a light purplish color. The tissue is somewhat dense.

"*Low Power.*—The section represents brain tissue, where with great difficulty can be traced the borders of the gray and white matter. The most conspicuous histological finding is the pronounced vascular reaction, blood vessels and capillaries are markedly distended, filled with red cells, intermingled with many leucocytes, some of which are in the center, some around the periphery. Practically all around the larger vessels and capillaries, is to be seen a condition of perivascular round cell infiltration. In some cases this infiltration is very pronounced. This vascular reaction has its location mainly on the periphery, in the pial membrane. The same round cell (perivascular) can be seen also in the deeper tissue of the gray and white matter. In one location of the white matter there is a distinct localized accumulation of round

cells, a localized abscess, and in the neighborhood of it all the blood vessels are markedly dilated, filled with red cells, intermingled with white cells and around them are many round cells. The brain tissue proper shows some fatty changes, fatty degeneration, granular changes. Throughout the whole brain tissue can be seen in small groups of two to four, cells of round cell infiltration.

"*High Power.*—In the localized abscess the cells are mostly round cells; also throughout the brain substance the cells are small round cells. Otherwise, there are the same changes as described above. In some localities there are small blood vessels that show considerable sclerosis.

"*Histopathological Diagnosis.* Acute leptomeningo-encephalitis."

RHEUMATIC NEURITIS.

It is not improbable that the disturbances, functional and structural, which we are producing in animals are often paralleling those in the patients who present to us for study and treatment. It is for this reason that we esteem very highly the information which we have gained by study of the animal pathology, both histological and clinical. This is well illustrated in the following case.

Case No. 484.—The patient, male, forty-one years of age, as he presented to me eight years ago, had the following symptoms: Physically, he was under weight, about five feet nine inches tall and weighed only $123\frac{3}{4}$ pounds, making him 22 per cent under weight. One arm was much smaller than the other. This muscle atrophy was so marked that he could not lift, and had not for about twenty years, five pounds higher than his shoulder, with his right arm, while with his left he could lift fifty pounds. He suffered a great deal from rheumatic neuritis. There was no involvement of the joints, but much involvement of the muscles and nerves. He suffered much from lassitude and had a definite heart murmur. His history showed a very unusually severe overload coming to a young man of definite rheumatic susceptibility. In midwinter a water main burst in the plant of his employer and he worked for two hours in the nearly ice cold water repairing the break which threatened to do great damage to the plant. That night he was taken with an extremely severe attack of what was called inflammatory rheumatism, and from the description undoubtedly involved the spinal and sciatic nerves. Both knees

were drawn up to his chin and remained so for weeks. One arm, his left, was flexed against his shoulder. Finally, with extreme force, his body was straightened and strapped in that position. About a year before this exposure, he had a number of teeth treated and filled, roentgenograms of some of which are shown in Figure 402. This does not represent their condition at the time of the exposure, but their condition as he presented to me eight years ago. We extracted several teeth and condemned several

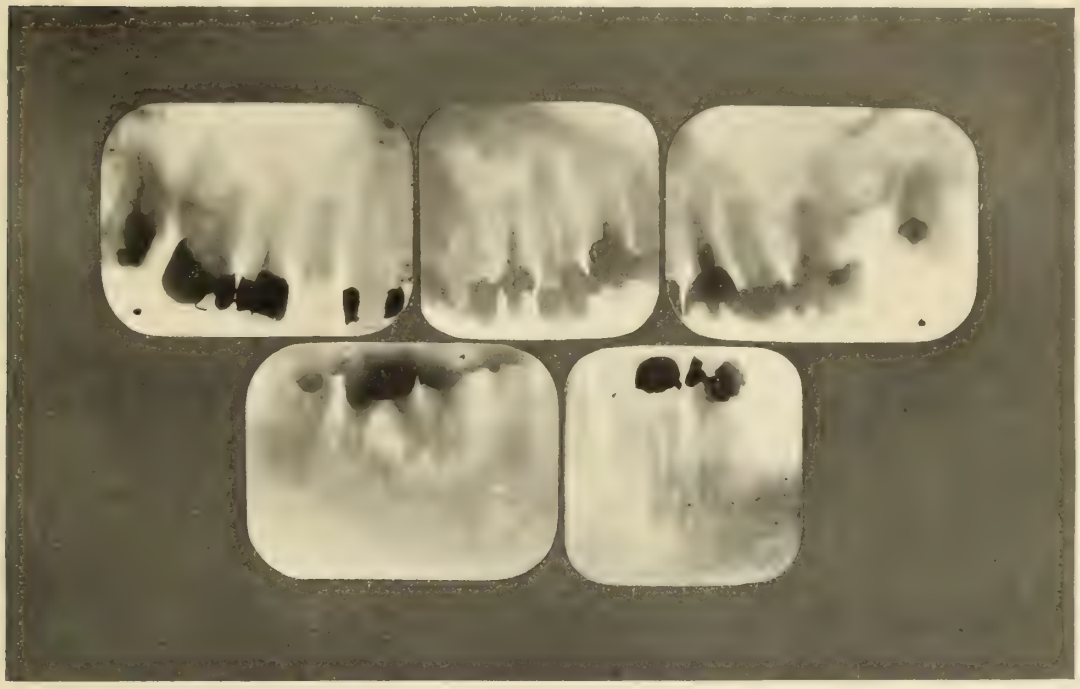

FIGURE 402. ROENTGENOGRAPHIC APPEARANCE OF THE TEETH OF CASE NO. 484; PATIENT SUFFERING WITH RHEUMATIC NEURITIS AND HEART, WITH EXTREME MUSCLE ATROPHY.

others. Another dentist told him that he was foolish to have these teeth extracted, that he could drain them and fill them, which he proceeded to have done. With the removal of the infected teeth he made very marked improvement, so much so that he could raise 15 pounds above his head, with his atrophied arm, and its circumference increased considerably. This improvement lasted for about one year; and his old trouble came back gradually, but with its former distressing symptoms progressively getting worse. He returned to me saying that he was willing now to abide by my judgment and wished me to take his case again, which I did. With the removal of some more of his infected teeth he made rapid and excellent improvement.

A very important incident happened in connection with one of these teeth, the lower right cuspid. We desired to take a culture from the pulp chamber before its extraction, for study of the type of organisms. This was done by opening the tooth, removing some of the contents on a sterile broach and resealing the opening, and I arranged for the extraction of the tooth at a subsequent sitting. The patient returned to the manufacturing plant where he was employed. That afternoon he was taken so severely with a type of neuritis that drew his right knee up against his body, and from which he suffered so severely, that an ambulance had to be called to take him to his home. We extracted the tooth the following day and the trouble began to improve in a few hours and in a day or two had entirely disappeared. This, he said, was a symptom quite identical to what he had suffered in his first attack. With the removal of these dental infections he made so great an improvement that for the first time in twenty years he was able to use his right arm almost as efficiently as his left, and came finally to be able to swing a heavy sledge hammer with it for hours at a time without exhaustion. He was making splendid progress when he was taken with Flu and developed pneumonia, which I presume was probably streptococcal pneumonia and which proved fatal.

Several important observations should be made in his case. The structural changes produced in the animals inoculated with strains from similar cases and from teeth of patients suffering less severe lesions are characteristic. There is a marked tendency to localize in the spinal and motor nerves. This man gave a history of a great deal of suffering from abscessed teeth at the time his dental work was done at nineteen or twenty years of age. There is no doubt that much of the infected tissue, shown in Figure 402, was present, in part, at the time he had his extreme exposure in the cold water at twenty-one years of age. It is not improbable that had his dentist at that time carried out a program of prevention, not building simply for a man in normal exposure and with normal resistance, but one for much less than normal defense, as a study of his history would have revealed, and had prepared him not only for ordinary overloads of exposure but for extreme ones such as he got — in other words, built a factor of safety that would stand rough seas as well as calm — this man might have been spared his months of agonizing suffering, years of incapacity, and premature death; and yet this dentist did just what nine out of ten probably of the dental profession of the country are doing

today through ignorance.

In Figure 403, we show his susceptibility chart from which it will be seen that his chief trouble was rheumatic neuritis, and lassitude with heart involvement; that he had a definite inherited susceptibility to rheumatism and neuritis from his father's side and to heart from his mother's side, his mother having had heart involvement quite severely though she died suddenly, presumably of a stroke. The mother's brother died of heart involvement. A brother and two sisters have all had rheumatism, and a sister has had a serious heart involvement and two of her sons have had very severe heart involvement. He has broken just where we should have expected; and the result, in his case, corresponds to a large majority of cases with a marked hereditary susceptibility plus dental infection and overload. This triad will break any human body. The life, at sea in this boat, is sailing in a vessel that is safe only in calm waters; and this case represents, probably, one in ten of all the patients who come into any dental office. When we remember that one in ten of the funerals of all ages is a life that has been foreshortened because of heart involvement, we are simply recording the fate of a craft that has drifted into rough seas, for which its factor of safety is too low. The cracked china cup may last longer than any cup in the cupboard, but only because it is taken better care of than are the others.

In this conection, I wish to refer to the affect of a similar exposure upon our injected rabbits, to which I have referred in Chapter 21 on Overloads. These showed that rabbits, that were subjected to chilling by having a part of the body submerged in ice water for fifteen minutes a day for a few days following their inoculation, developed acute purulent arthritis where the controls receiving the same culture and same quantity, but were not subjected to this chilling, did not develop lesions.

MENTAL CLOUD.

Cases that will naturally be grouped under central nervous system with psychic involvements will include a great number and a wide variety of affections. This is so common a disturbance that we have found it necessary to make a place on our resistance and susceptibility charts for it, and where, for convenience and courtesy's sake, we have termed it "Mental Cloud." We have, therefore, discussed this group under that title.

As indicated in the closing paragraph of the preceding text, we had a very large variety of disturbances of which an important,

Private Records of Weston A. Price, M.S., D.D.S., 8926 Euclid Avenue, Cleveland, Ohio

Form No. 1x Serial No. 484

RESISTANCE AND SUSCEPTIBILITY CHART

PATIENT R.C.N Case No. 484 AGE 41

ADDRESS DATE 5-2-18

CHIEF COMPLAINT Rheumatic neuritis. Lassitude Heart

Pt. has now	Pt. has had	Rheumatic Group Lesions and Complications	Own: Brothers	Own: Sisters	Own: Sons	Own: Daughters	Own: Husband or Wife	Fathers Side: Father	Fathers Side: Grandfather	Fathers Side: Grandmother	Fathers Side: Uncles	Fathers Side: Aunts	Mothers Side: Mother	Mothers Side: Grandfather	Mothers Side: Grandmother	Mothers Side: Uncles	Mothers Side: Aunts
		No.	2	3	1	1										4	3
		Tonsillitis		*	#	+?											
##	##	Rheumatism	#	#²				#	#		+						
		Swollen or Deformed Joints						#									
	#	Neck-back or Shoulders															
		Lumbago															
##	#	Neuritis		#				#									
		Sensitizations															
		Sciatica		#													
	+	Chorea or St. Vitus's Dance		#	#		Sister's child										
	#	Nervous Breakdown		#	+	+											
		Mental Cloud															
	#	Persistent Headache	#	#			#										
##	##	Heart Lesions		##									#			(#)	
		Dropsy															
	#	Kidney Lesions, Brights						#									
		Liver or Gall Lesions															
		Appendicitis	*														
	#	Stomach pain or Ulcer				#	+										
		Eye, Ear, Skin, Shingles															
		Pneumonia															
		Anemia															
		Goiter		+													
	#³	Lassitude, Chilliness					+³	#									
		Hardening of Arteries															
		Stroke						(+)					(+)	(+)	(+)		
		Age if Living															
		Age at Death						85					72	90	90		
		Flu with Complications															
		Flu without Complications															
	#	Typhoid															
		Extensive Tooth Decay															
		Abscessed Teeth															
		Loosening Teeth															

Years: 1 2 3 4 5 6 7 8 9 10 11 12 13 14 15 16 17 18 19 20 21 22 23 24 25 26 27 28 29 30 31 32 33 34 35 36 37 38 39 40 41 42 43 44 45 46 47 48 49 50 51 52 53 54 55 56 57 58 59 60 61 62 63 64 65 66 67 68 69 70 71 72 73

Duration of Pen. tal Infection
Duration of chief Affection

KEY FOR CHART: + HAD LESION; # FREQUENTLY; # VERY SEVERELY; +? PROBABLY; * OPERATION; (+) FATAL ATTACK

CARIES	LOST	CONDNG.	SL. HG.
#	#	#	#
PYRRH.	GUM	RECESS	RACH.

SYSL. REST	COMP.	PART.	RECR.	NONE
		#		
SC. SC. DEFI.	INFIT	ACCOM.	ABST.	SC. NO
	##			

FACTOR OF SAFETY: V. HG. HIGH FAIR LOW V. LW. #

FIGURE 403. SUSCEPTIBILITY RECORD, CASE NO. 484. NOTE THE STRONGLY INHERITED SUSCEPTIBILITY FOR HEART AND RHEUMATISM, WITH FOUR DEATHS FROM STROKE.

if not the chief expression, is a psychic depression or aberration. A very simple and the most frequent expression of this is a sense of impending doom and discouragement. In a number of instances, patients not only did not care whether they lived, but struggled with a fear that in these states they would take their own lives. In many instances this depression has completely disappeared after the removal of dental infection. Another and very common expression is that of discouragement and a depression amounting to gloom, with a reaction, as crying, with little or no provocation. The next case illustrates such a condition.

Case No. 1178.—The patient, age thirty-five, mother of two small children, the youngest six or eight months old, has been suffering from extreme nervousness, apparently without cause, numbness of the hands, digestive disturbance not accounted for by food, and pain in the back. These had dated back to a recent pregnancy and had been most severe during the period of lactation. The mental condition was sufficiently alarming to cause her husband and herself much apprehension, and it did not respond either to rest or medication. Her resistance and susceptibility chart, shown in Figure 404, and her history indicate that she has been breaking very seriously in the nervous system at different periods of her life. The first two columns, showing the present and past rheumatic group disturbances of the patient, indicate that she has been breaking with unusual severity. Her one brother, twenty-nine years of age, has also had several of the same lesions. Her father, still living, had a very severe nervous breakdown at forty-eight. He also has had rheumatism and acute digestive disturbance. His father died young, by accident, and his brothers and one of his sisters had acute rheumatism and a severe neuritis. This patient's mother died at fifty-two, by accident. However, she had been troubled severely with gallstones and acute indigestion. Her mother's father died of Bright's disease and two of her mother's brothers died of acute digestive tract complication.

The analysis of her case reveals, as types of dental infection, a marked tendency to caries, much apical infection, locked area infection, with condensing osteitis. The sockets were very slow in healing. The systemic relief from the removal of the dental infections was complete; the type of susceptibility, inherited; and the factor of safety, low. This patient had had a tendency to gingival recession. There was no free pus at this time. The teeth

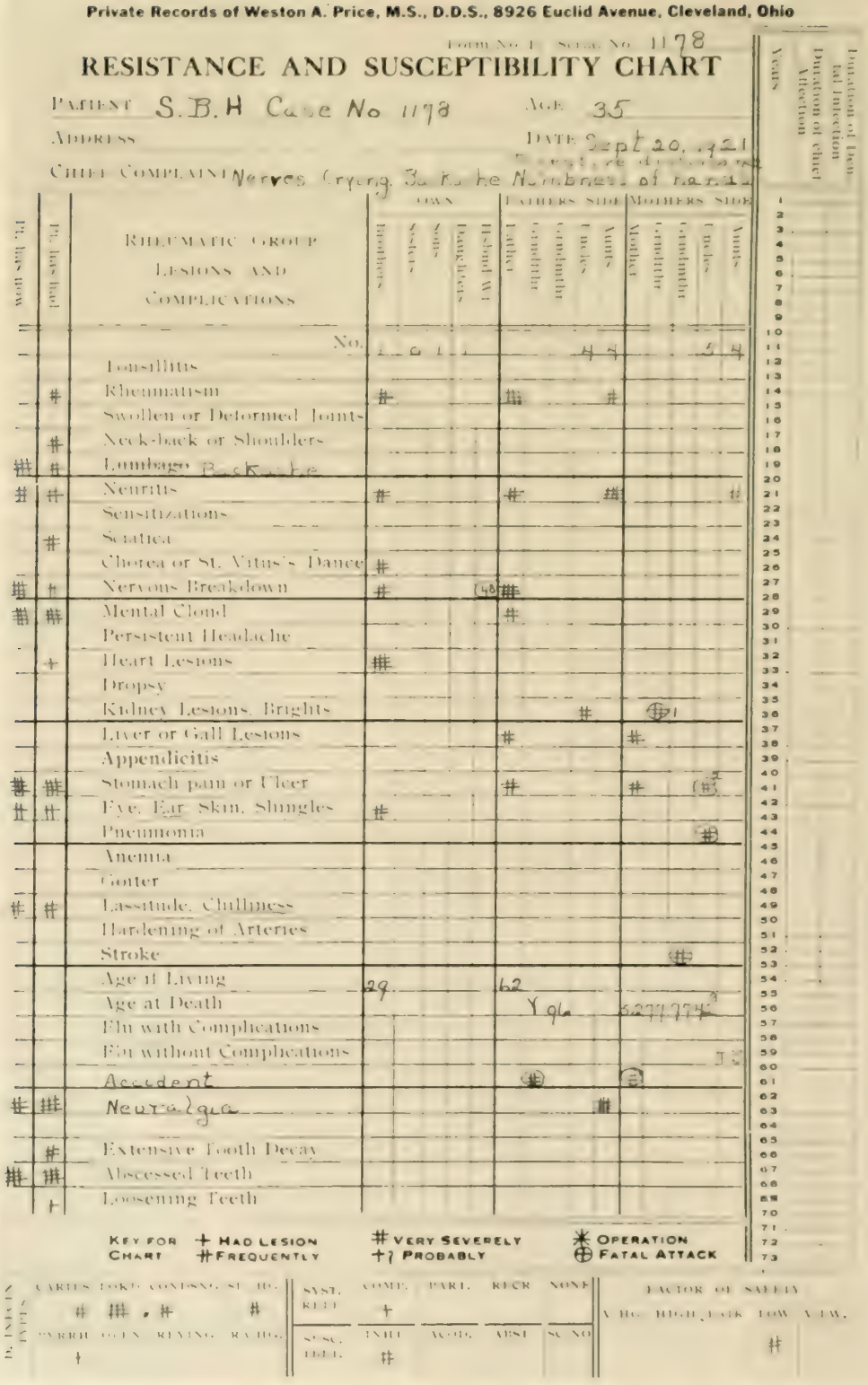

FIGURE 404. SUSCEPTIBILITY RECORD OF CASE 1178. NOTE STRONGLY INHERITED SUSCEPTIBILITY FOR STOMACH INVOLVEMENT AND NEURITIS.

condemned are indicated and all are shown in Figure 405. We would call particular attention to the zone of condensing osteitis surrounding the rarefying in the mesial root of the lower left first molar and surrounding both roots of the lower right first molar, indicating that, previously, there had been a state of relatively high resistance which had changed to one which we consider to be of less resistance, in which the local reaction took the form of a deposition rather than a rarefaction.

The length of the lines in the two columns, Duration of Dental Infection and Duration of Chief Affection, show that the dental history indicates that the lower first molars were known to have abscessed and been treated when she was fourteen years of age. During girlhood her defense was apparently ample to protect her against this infection. Her present series of serious breaks began with her first pregnancy at twenty-eight years of age. The removal of her dental infections was followed by a prompt removal of all the acute nervous disturbances. In this case there was a great deal of dental infection and of a type most likely to be serious, as indicated by the condensing osteitis surrounding the rarefying.

Cultures taken from her teeth and inoculated into animals produced very marked central nervous system disturbances and degenerative arthritis accompanied by other important pathological changes.

Rabbit 716, shown in Figure 406, had a very marked disturbance, including dragging of the hind legs followed by an acute painful swelling in the region of the left hip joint. This paralysis developed in about three weeks after inoculation with 1 cc. of a 24 hour culture from the teeth. In about a week's time the rabbit began to improve rapidly, but retained deformity in its gait with some swelling of the left hip, as shown in the roentgenogram in Figure 407. The progressive stages of this hip disease are shown in the succeeding pictures, A, B, C, etc. The rabbit was chloroformed and posted about four months after the inoculation, at which time it weighed 1493 grams, a total gain of 378 grams, it having weighed at the time of the inoculation 1115 grams, and from which weight it reduced to 965 grams at the time of its paralysis. Figures 408 and 409 are photographs showing the changes in the heads of the femurs. Figure 410 shows a smear of diplococci taken from the joint capsule.

Rabbit 710 was inoculated intravenously with 1½ cc. of a twenty-four hour culture of freshly extracted teeth, at which

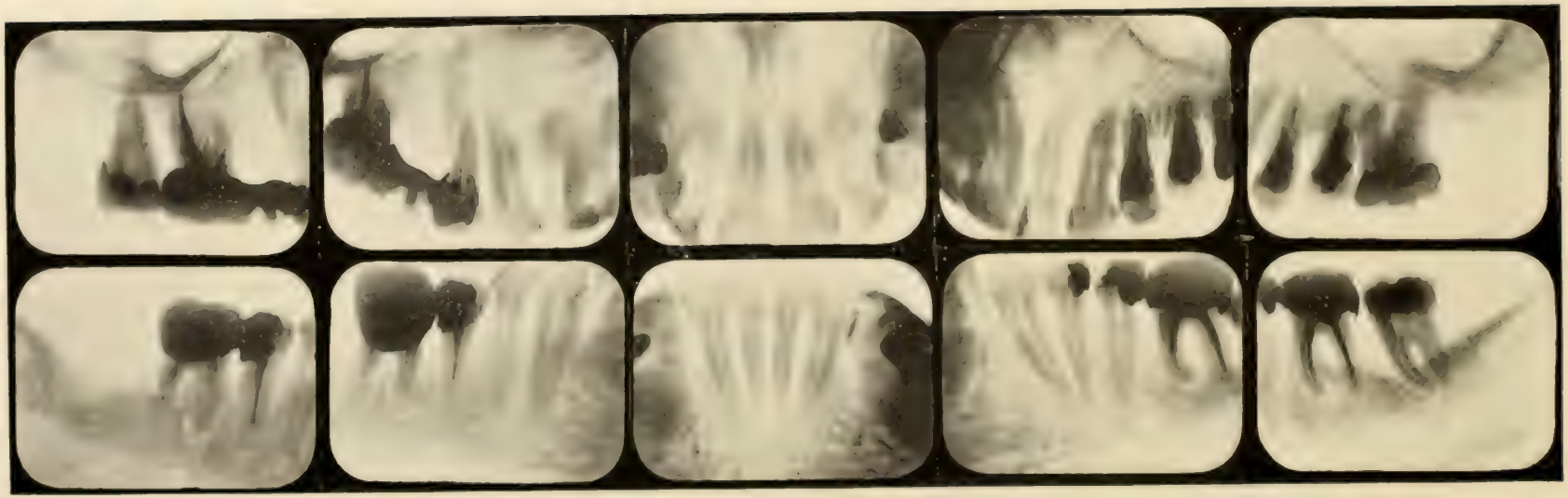

FIGURE 405. ROENTGENOGRAPHIC APPEARANCE OF TEETH OF CASE 1178. NOTE LIMITED PERIAPICAL ABSORPTION ABOUT LOWER FIRST MOLARS. PATIENT SUFFERED FROM EXTREME NERVOUSNESS.



FIGURE 406. THIS RABBIT 716 CARRIED OR DRAGGED ITS HIND LEG FROM A CULTURE FROM THE TOOTH SHOWN ON OPPOSITE PAGE. SEE NEXT FIGURE.

time it weighed 1665 grams. In twelve days, the rabbit was given the second inoculation, thirty-two days after which a condition of partial paralysis developed in the hind legs. The rabbit with the paralysis of the hind legs is shown in Figure 411. Roentgenograms of the vertebral column were made and show the condition in Figure 412. The weight of this rabbit, when chloroformed five weeks after the inoculation, was 14 grams more than when inoculated. The postmortem of this rabbit showed a tumor-like mass on the posterior surface of the vertebral column in the region of the first and second lumbar vertebræ. The intervertebral cartilage was completely destroyed and its position surrounded by a thick fibrous capsule. On opening the capsule, there were exposed the vertebral borders bathed in the mass of broken down tissue and plasma. The neighboring vertebræ and the cartilages were normal. This necrotic suppurative process extended into the intervertebral space and involved the spinal cord. This rabbit also had a myocarditis and an acute nephritis. The paralysis involved the sphincters. There was an acute dilatation of the urinary bladder with retention. Motion pictures were

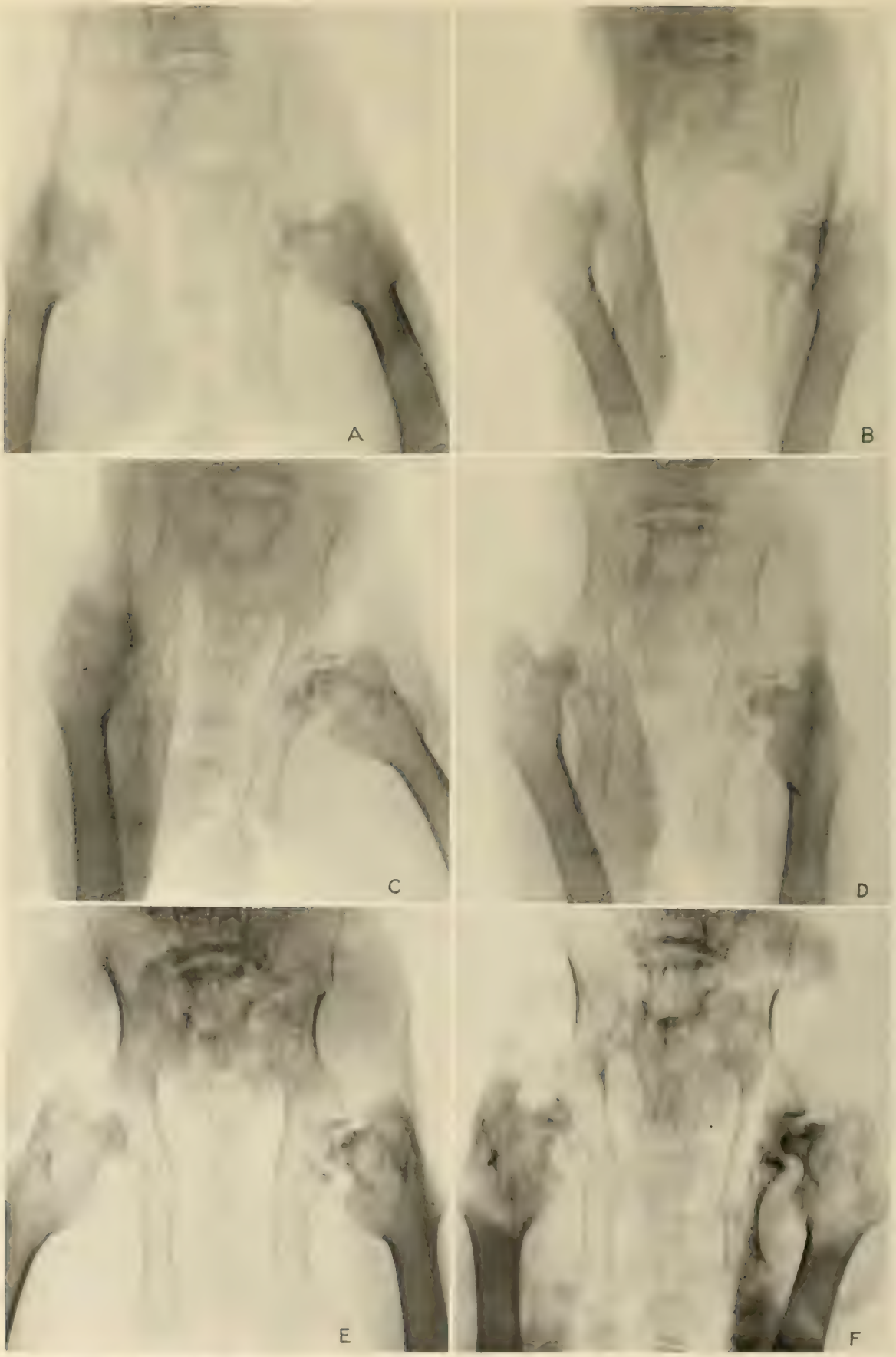

FIGURE 407. A SERIES OF ROENTGENOGRAPHIC VIEWS OF PROGRESSIVE DEVELOPMENT OF HIP DISEASE IN RABBIT 716, SHOWN IN PREVIOUS FIGURE. CULTURE FROM TOOTH IN CASE 1178.

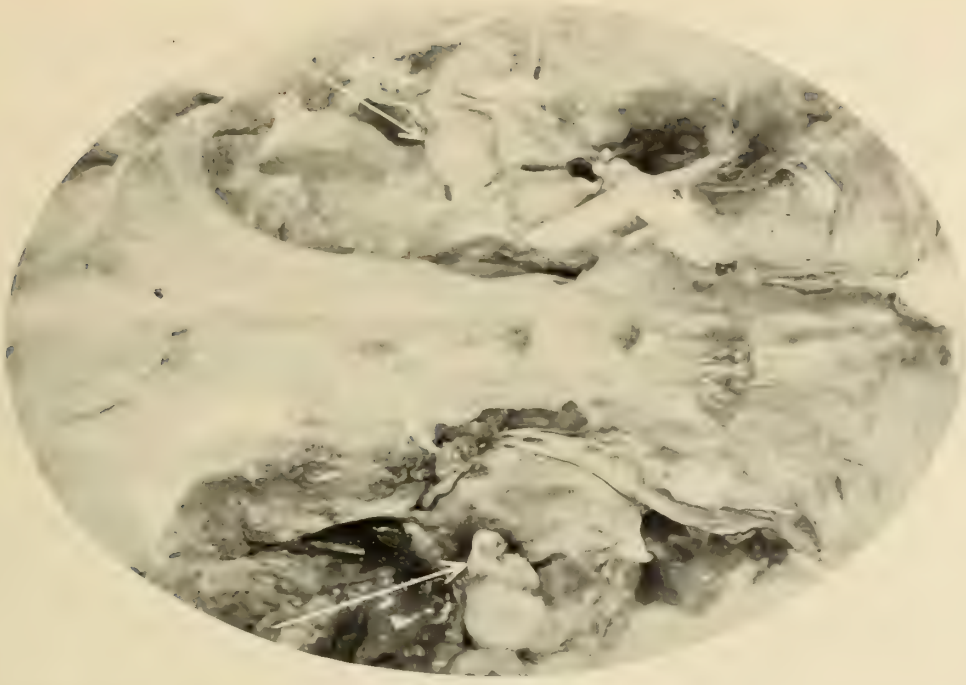

FIGURE 408. PHOTOGRAPHIC APPEARANCE OF HEADS OF FEMURS ON POSTING, RABBIT 716.

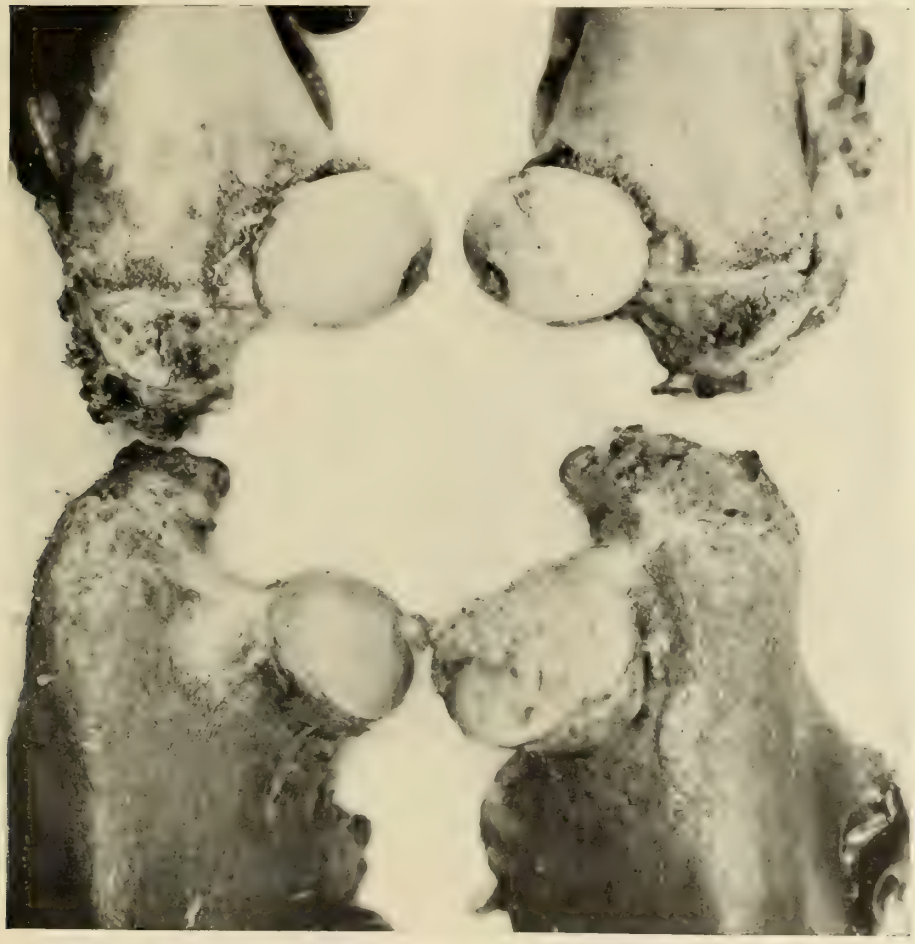

FIGURE 409. ENLARGED VIEWS OF NORMAL AND DISEASED FEMURS OF RABBIT 716 FROM CASE NO. 1178.



FIGURE 410. A SMEAR SHOWING DIPLOCOCCI IN PUS FROM HIP JOINT OF RABBIT 716.



FIGURE 411. RABBIT 710, WHICH DEVELOPED PARALYSIS OF HIND LEGS FROM DENTAL CULTURE FROM CASE 1178.

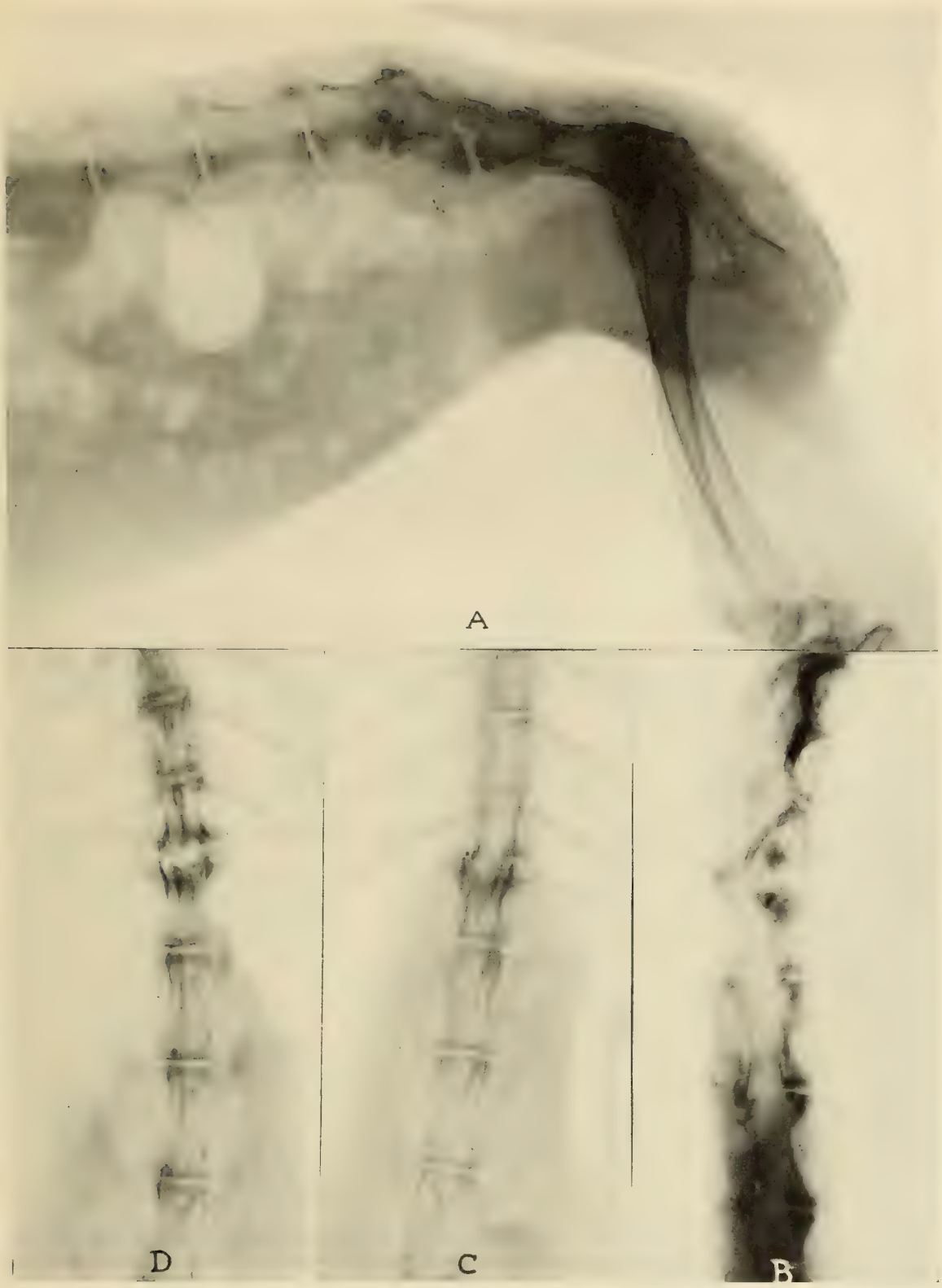

FIGURE 412. ROENTGENOGRAPHIC APPEARANCE OF LESION IN THE SPINE OF PARALYZED RABBIT, 710. CASE 1178. A, LATERAL VIEW WHILE LIVING. NOTE CONDENSING OSTEITIS. D, C, AND B, VENTRAL AND LATERAL VIEWS. NOTE CONDENSING OSTEITIS.



FIGURE 413. SMEAR FROM KIDNEY OF RABBIT WITH NEPHRITIS FROM DENTAL INFECTION, SHOWING PUS CELLS AND STREPTOCOCCI.

made of this rabbit. A smear from such a kidney is shown in Figure 413, showing pus cells and streptococci.

Rabbit 632 weighed, when inoculated, 1100 grams. It was inoculated with a twenty-four hour culture prepared by inoculating media with the filtered portion of the washings of the crushed teeth. This filter took out all but the extremely small organisms. The culture which grew was an exceedingly minute streptococcus in diplococcal form. The next morning following the inoculation, the rabbit showed peculiar choreiform movements and lateral nystagmus of both eyes. The rabbit lost in weight rapidly. In eight days it reduced to 822 grams, at which time the head was rotated and the choreiform movements were very marked, which torticollis developed more markedly until the rabbit's head was turned sharply to the right. It was chloroformed sixteen days after the inoculation. The brain and spinal cord were markedly engorged, with evidence of a brain and spinal meningitis. Figure 414 shows sections from the brain and spinal cord of this rabbit.

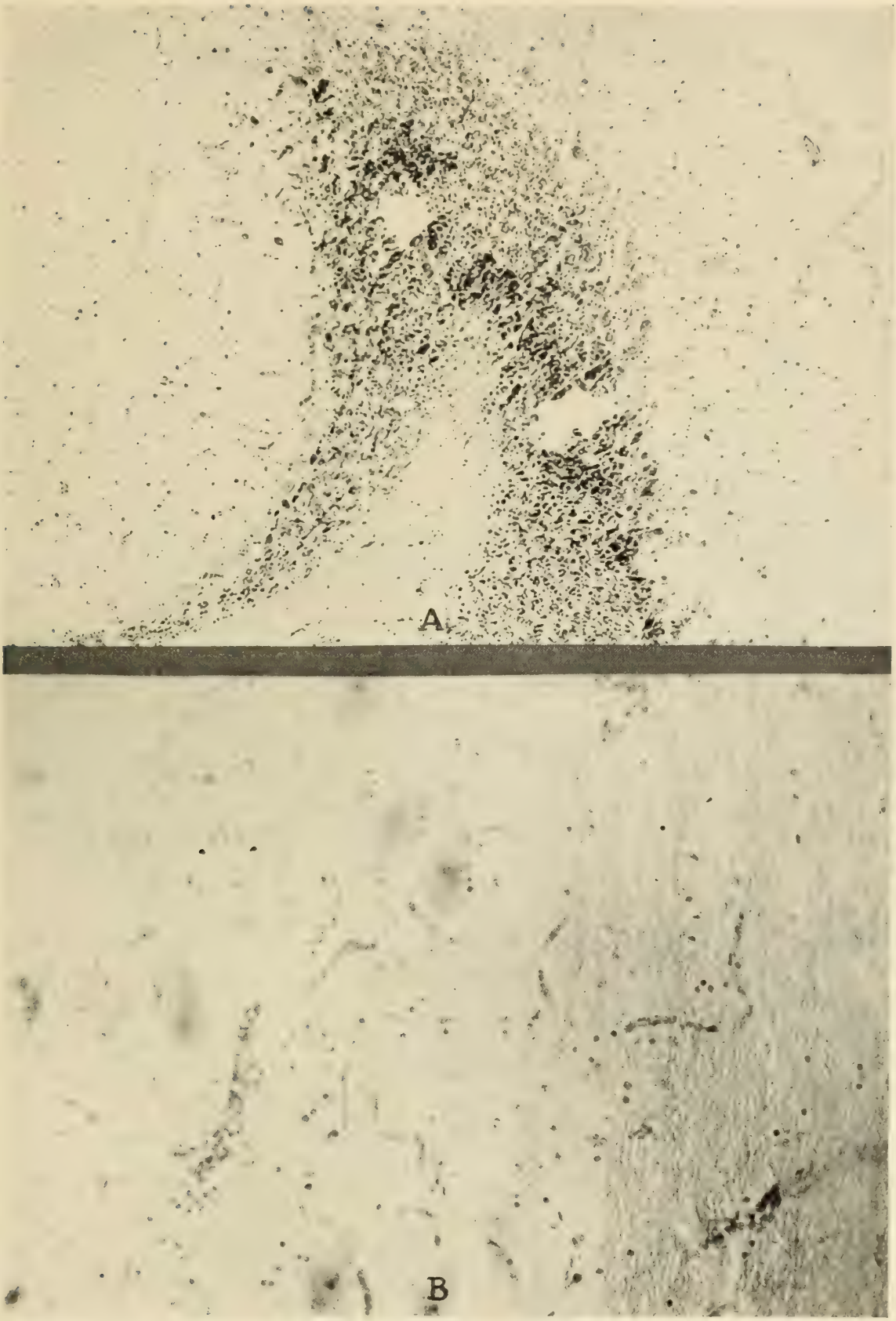

FIGURE 414. CENTRAL NERVOUS SYSTEM CHANGES IN RABBIT 632 WITH CHOREA, NYSTAGMUS, TORTICOLLIS, AND GYRATORY MOVEMENTS: A, A FOCALIZATION IN CEREBELLUM OF BRAIN; B, CONGESTION AND DEGENERATION IN GRAY MATTER OF CORD.

Rabbit 630 was injected with the same quantity of the same media which had not been inoculated from the filtered washings of the crushed teeth, at which time it weighed 1075 grams. It was posted in twenty-one days, at which time it had gained 120 grams, approximately normal growth. No pathology was found and in every way the rabbit was apparently normal. This was a control rabbit to see whether any other substances than the virus from the crushed teeth were involved.

Rabbit 626 was inoculated intravenously with a suspension in normal salt solution made by finely grinding some of the sediment from which the filtrate was taken for inoculating Rabbit 625. This inoculation was used in part to test its effect in sensitizing the rabbit for the culture grown from this sediment; and ten days following the sensitizing dose above, the animal was inoculated intravenously with 1 cc. of the culture grown from the same sediment. Two days later, the rabbit was favoring the left front leg and a swelling appeared in the left shoulder joint. Eight days later it was chloroformed, at which time it had gained 168 grams. The postmortem showed an intracapsular purulent arthritis of the right shoulder joint. Note that this is an exceedingly short period of time for a culture to produce a purulent arthritis, and in the light of the history of similar strains, strongly suggests that the first dose, while infinitely minute in actual amount of organisms conveyed, tended to prepare the animal for the inoculation of the strain grown from this source. This is in contradistinction to the immunizing effects produced in small but graded doses.

Rabbit 624 was inoculated intravenously with 5 cc. of the filtrate from the crushings of these same teeth: namely, the upper right first and second bicuspids. (See Figure 405.) This again was a test of the effect of the filtered washings for producing a sensitization or preparation of the rabbit for an intravenous inoculation, which was made twelve days later with 1½ cc. of a culture from these teeth. Seven days later, the rabbit developed an acute swelling of the left hind leg and knee region, partially carrying the same. It was chloroformed, at which time it showed a total gain of 129 grams.

A very marked and unusual condition is expressed with this strain. All these rabbits, though seriously involved, have shown gains in weight, quite unlike the reactions produced by ordinary strains and particularly all those producing proliferative arthritis. An associated very important and characteristic symptom

of this case is that this patient, notwithstanding her extreme nervous involvement, was not reduced in weight but was slightly over weight. On postmortem, this rabbit was found to have ulcerative aortitis and intra- and extra-capsular articular purulent arthritis of the left knee. Figure 415 shows an aortic arch

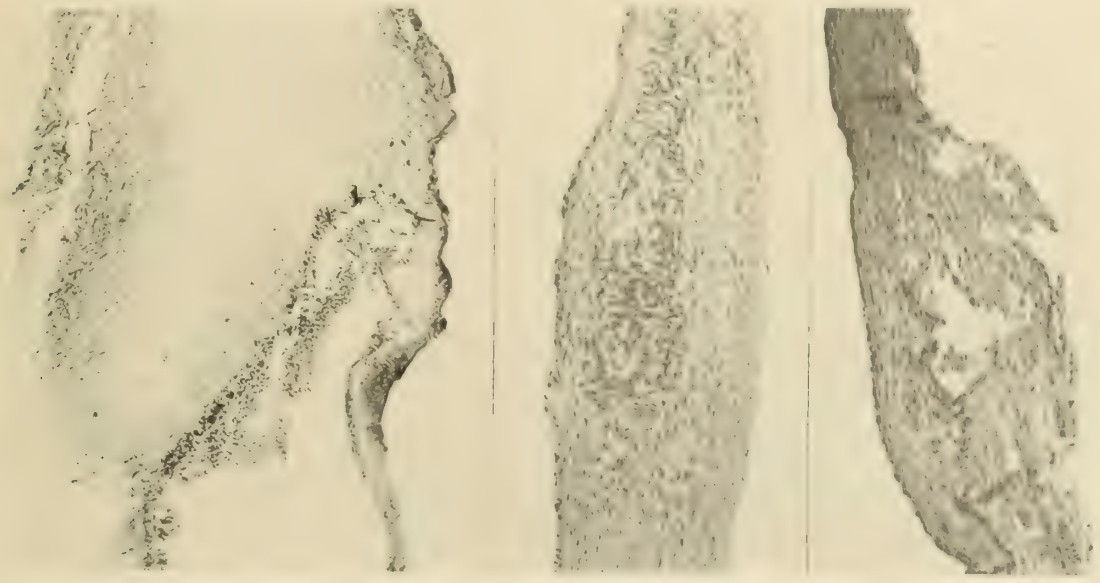

FIGURE 415. LESIONS IN THE AORTIC ARCH OF RABBIT 422.

section and Figure 416 a section of the joint capsule illustrating this condition. Note that Rabbits 624 and 626 give evidence of an anaphylactic arthritis.

Rabbit 604 was injected intravenously with the filtrate from the washed crushings from the lower right first and second molars, at which time it weighed 1110 grams. This rabbit went into a progressive condition of marasmus and cachexia. It died in twelve days from extreme emaciation. Otherwise, there was no gross pathology. It had lost in weight 318 grams or nearly 29 per cent of its weight. Note that this animal lost in weight, receiving only the filtered washings of the tooth; whereas, those that received the culture grown from this sediment gained in weight. This rabbit did not develop acute localization symptoms but, primarily, marked symptoms of a toxemia. It is very evident that we are dealing here with two distinct types of animal reaction produced from teeth from the same patient.

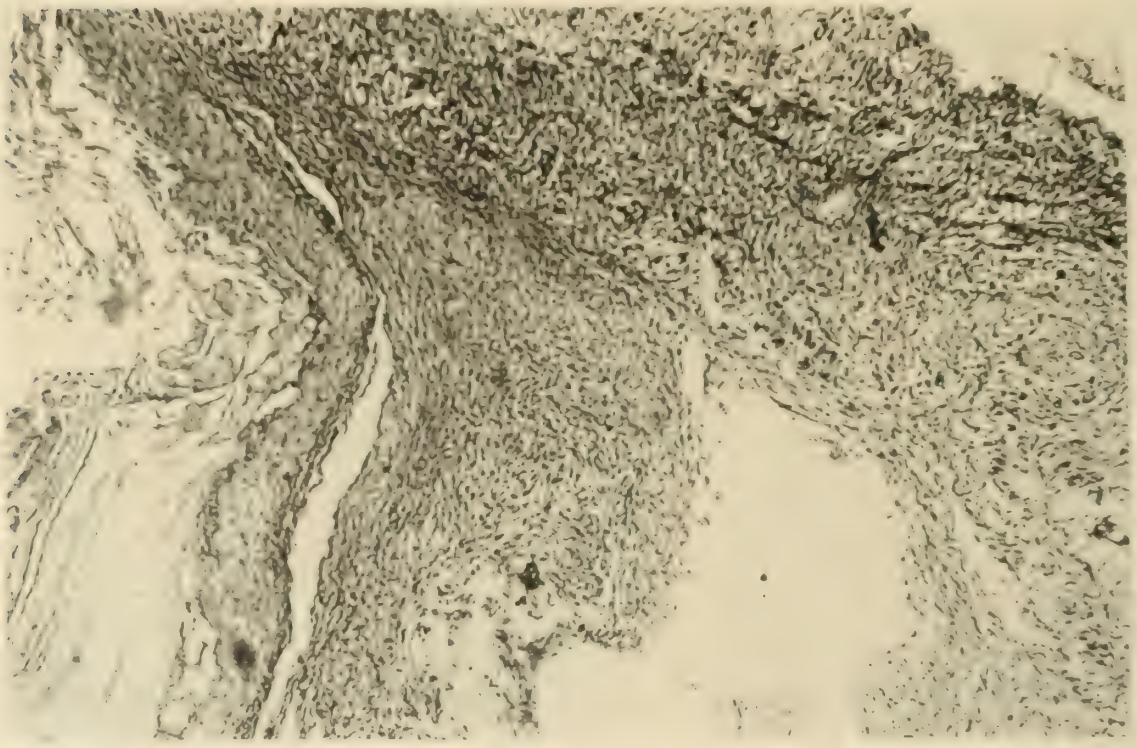

FIGURE 416. TYPICAL DEGENERATIVE ARTHRITIS OF JOINT CAPSULE OF RABBIT 624.

Another and very common expression is a disturbance of the centers controlling sleep. These disturbances may take any of a variety of forms: extreme sleepiness, marked inability to sleep, distressed dreams with sudden awakenings, muscular twitchings and jerkings during sleep. One of these is illustrated in the following case: A young man, Case No. 711, age twenty-two, who would regularly sleep fourteen hours and then had to be awakened. Almost immediately there was a change in his condition and he was slept out in eight hours. He remained normal in this regard when last reported, one year after the extraction.

Another illustration is shown in Case No. 1273, whose disturbances were the following: extreme sleepiness requiring fourteen hours a day, neuritis in his neck and shoulder, and nervous indigestion. These symptoms entirely disappeared within a few days after the obliteration of the dental infection, so much so that he was more rested in eight hours than formerly in fourteen hours. The roentgenographic record of his dental condition is shown in

Figure 417. The history showed that this condition of disturbed sleep, nervousness, and lassitude dated back for two and one-half years, during which time it had been recurring with increased severity, the last attack lasting a month and being very distressing. One year later the patient reports that he has had complete relief from his old trouble of sleepiness.

Another and more serious expression of disturbance of the central nervous system and sleep is illustrated in the following case which had been cons dered one of hopeless insanity. This patient, age forty-seven, was brought with the history that she had not slept for five weeks; that her previous attacks of insanity had been preceded by similar disturbances; and that she had been in insane institutions for approximately eight of the twelve months of each of the last five years. Her attacks developed in the following order: First, sleeplessness developing with increased severity until she would be awake every hour, day and night for several weeks; extreme excitability and irritability; and finally, violence, in which stage she would be put into an insane asylum. The dental condition is shown in Figure 418. Her history showed that the upper right central and lateral were broken by an injury at twelve years of age and had been suppurated ever since, namely thirty-five years. There had been exceedingly little local discomfort from her teeth. With the removal of three or four of the teeth, the patient slept much of the time for three days. The cycle of her developing symptoms indicated that soon she would be violent and she was to have been taken to the state asylum for treatment, when placed in our care. While giving her our attention, we placed her in the private ward with a skilled nurse. In a few days' time she passed through the series of nervous system disturbances which in previous attacks had taken many weeks. After removing her several infections with as much care and freedom from nervous overload as possible, she was placed in an insane asylum because of the danger to those attending her. In about two weeks' time we were notified that she was apparently normal and could go home. All previous attacks for five years had required, approximately, eight months to recover from. She was kept in the institution as an instructor in fancy-work for the female patients. Being a highly trained business woman, she was transferred to the office where she had the responsibility of the director's work for ten hours of the twenty-four in an institution with two thousand insane patients. She has had

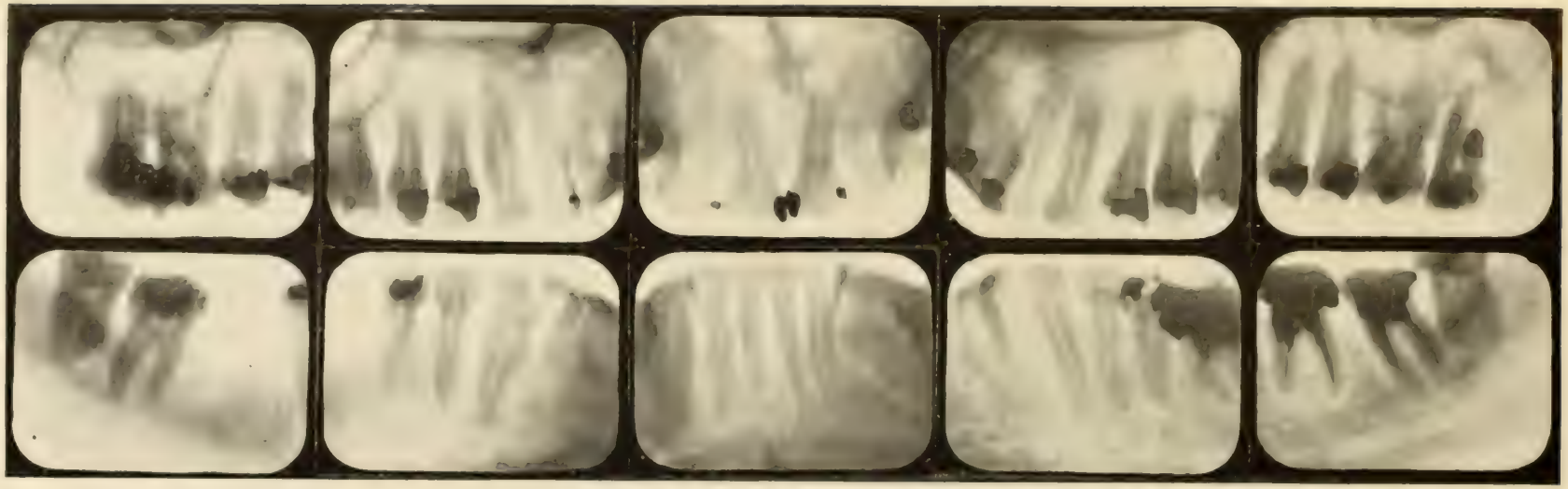

FIGURE 117. ROENTGENOGRAPHIC APPEARANCE OF TEETH OF CASE 1273 WITH EXTREME SLEEPINESS.

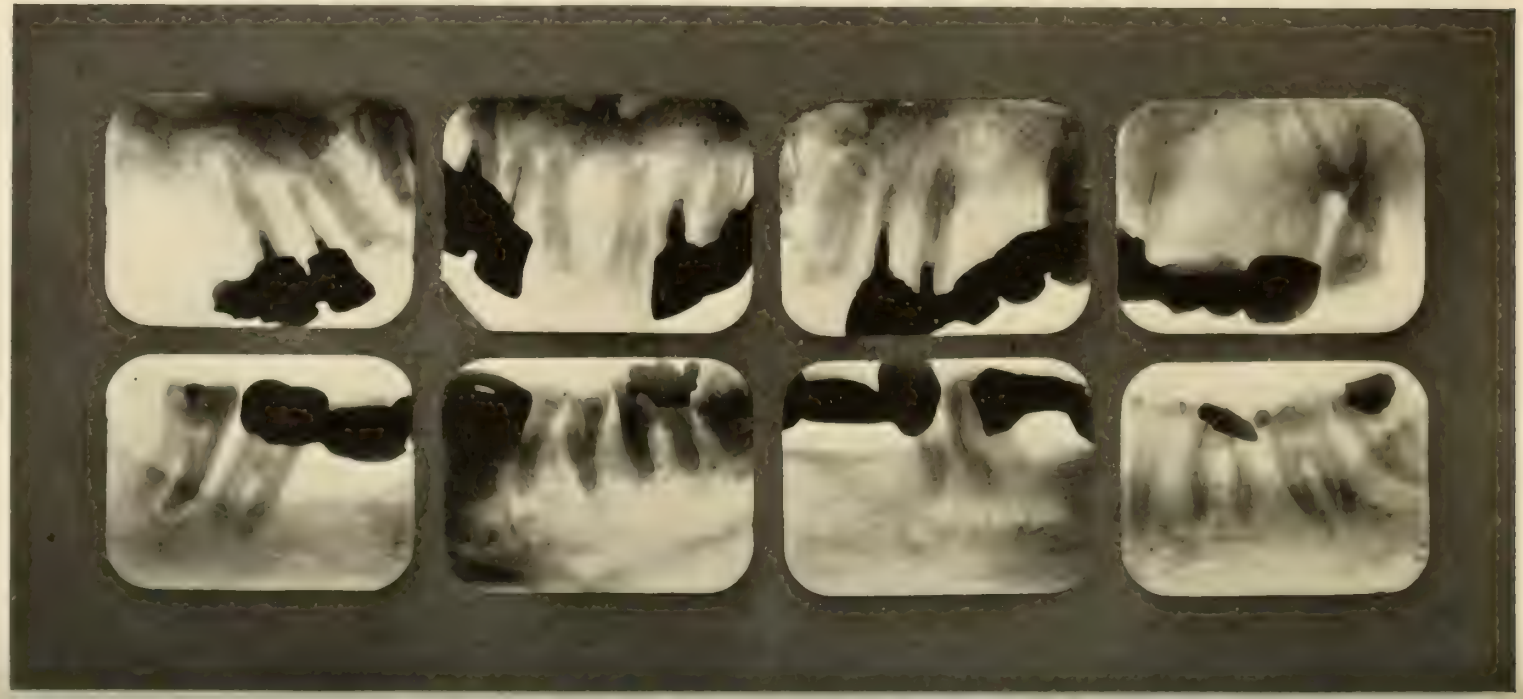

no symptoms of recurrence for approximately four years, has since been married, and is, as nearly as we can judge, a fairly normal woman.

Her susceptibility chart, shown in Figure 419, would be interpreted as follows: The patient's chief trouble has been a type of nervous breakdown with mental cloud as insanity. One of her sisters has had several disturbances of the nervous system, including a mild nervous breakdown. The patient's father had nervous breakdown and headaches. The patient's mother had symptoms in a mild way resembling those of the patient. While she never required to be in the care even of a guardian, she had spells of violent anger and was given to nagging and continual fault-finding with members of the family, but too shrewd to do so in the presence of outsiders. She died at seventy-two having lived alone the last twenty years of her life because of her disposition, which made it impossible for her children to live with her. Rheumatism was present on the mother's side. This daughter, therefore, received by inheritance this marked tendency to nervous break from her mother, accentuated by nervousness and headache from her father. This phase of her central nervous system was a very weak link in the chain; and in accordance with our studies, when such a person has a dental infection, its effect is, primarily, to irritate and affect that weakest link. The thing that happened to her was just what should have been expected. In addition to this, an acquired susceptibility tends to affect the nervous system or an injured tissue, chiefly the former.

As disclosed by the roentgenograms, she had an unusually large volume of dental infection; and by volume, I do not mean the cubic area of absorption at root apices, but the extent and quality of the infected dentin, as expressed in its ability to cause reaction in the patient, locally and systemically. If she carried root end infection perpetually from the time she was twelve years of age until she was forty-eight, it would require an exceptionally high defense to maintain her safety. The absorption on the side of the right lateral is an indication of an ability on the part of the patient to make a vigorous reaction during a long period of time. The condensation around these areas would indicate that the patient had come to a period sometime previously when her local reaction was less efficient. According to her history, these teeth were crowned twelve years previously and her nervous disturbances began about eight years ago and took on their extreme phase five or six years ago. The fact that

Private Records of Weston A. Price, M.S., D.D.S., 8926 Euclid Avenue, Cleveland, Ohio

Form No. 13 Serial No. 557

RESISTANCE AND SUSCEPTIBILITY CHART

PATIENT Case No. 557 S.W.N. AGE 48

ADDRESS DATE 1-10 19

CHIEF COMPLAINT Insanity

Pt. has now	Pt. has had	Rheumatic Group Lesions and Complications	Own: Brothers	Own: Sisters	Own: Sons	Own: Daughters	Own: Husband Wf	Father's Side: Father	Father's Side: Grandfthr	Father's Side: Grndmothr	Father's Side: Uncles	Father's Side: Aunts	Mother's Side: Mother	Mother's Side: Grandfthr	Mother's Side: Grndmothr	Mother's Side: Uncles	Mother's Side: Aunts
		No.	2	3							4	1				4	3
		Tonsillitis															
		Rheumatism		#									#				
		Swollen or Deformed Joints											#			#	#
		Neck-back or Shoulders	#	#													
		Lumbago														#	
		Neuritis		#													
		Sensitizations															
		Sciatica															
		Chorea or St. Vitus's Dance															
#	##	Nervous Breakdown		#				#					##				
#	##	Mental Cloud as Insanity											#				
		Persistent Headache						#			+						
	+	Heart Lesions											+				
		Dropsy															
		Kidney Lesions, Brights											⊕				
		Liver or Gall Lesions															
		Appendicitis															
	+	Stomach pain or Ulcer	#														
	+	Eye, Ear, Skin, Shingles	+					#									
		Pneumonia															
	+	Anemia															
		Goiter															
	#	Lassitude, Chilliness											#				
		Hardening of Arteries															
		Stroke															
		Age if Living															
		Age at Death	½	2				4	3	4	9	8	4	7	0	3	5
		Flu with Complications															
		Flu without Complications															
	#	Neuralgia		#									+				
		Childhood Disease	⊕														
		Typhoid		#													
	#	Extensive Tooth Decay		#													
	#	Abscessed Teeth															
		Loosening Teeth															

Years: 1 2 3 4 5 6 7 8 9 10 11 12 13 14 15 16 17 18 19 20 21 22 23 24 25 26 27 28 29 30 31 32 33 34 35 36 37 38 39 40 41 42 43 44 45 46 47 48 49 50 51 52 53 54 55 56 57 58 59 60 61 62 63 64 65 66 67 68 69 70 71 72 73

Duration of Dental Infection

Duration of chief Affection

KEY FOR CHART: + MAD LESION # FREQUENTLY # VERY SEVERELY ?+ PROBABLY ✳ OPERATION ⊕ FATAL ATTACK

PRESENT	CARIES	FOCI	CONDNG.	SL. HG.
	#	#		
	PYRRH.	OPEN	REVING.	RA HG.

SYST. REFL.	COMP.	PART.	RECR.	NONE
	#			
ST. SC. THLT.	INFL.	ACOD.	ABST.	SC. NO.
	#	##		

FACTOR OF SAFETY

V. HG.	HIGH	FAIR	LOW	V. LW.
				#

FIGURE 419. SUSCEPTIBILITY RECORD OF CASE NO. 557, WITH INSANITY AND MARKED INHERITED SUSCEPTIBILITY TO NERVOUS BREAKDOWN, AND MENTAL CLOUD.

this patient was passing into the series of progressive symptoms precisely as the previous attacks for five succeeding years had come on, indicates that the same forces were at work and that the patient was reacting in a similar manner. Since, however, the long maintained excitement and violent stage were aborted by the removal of the infections, so completely that she was reported by her brother to be more normal in two months than he had seen her for years and was reported to be so greatly improved as to come home in two weeks' time, suggests, if it does not indicate, that an important contributing factor had been removed in the removal of the infected teeth. This, together with the fact that she has had no recurrence, puts great importance upon thedental infection.

As for the future, we would say that the same inherited susceptibility exists and a sufficient overload will doubtless bring about a break. It is my opinion that few, if any, overloads are more potent to bring about such a break than dental infections. Whether these act largely or chiefly by bacterial invasion of the central nervous system, by toxemia's irritating the central nervous system, or a sensitization as true allergic reaction, or all three, is not as yet definitely established. There is strong indication, however, that each of these mechanisms may contribute and each may be the chief acting force in certain cases.

We have undertaken to study the effect of the toxic substance in infected teeth as a sensitizing agent. We have discussed this specifically in Chapter 30. It will be of interest in this connection to review the studies of these phenomena where the sensitizing substance was taken from the teeth of a patient suffering from central nervous system disturbance. The patient, female, married, age about twenty-four, two children, ages about two and four, has developed a very striking central nervous system disturbance expressing itself chiefly in crying without provocation. With the removal of her dental infections, these symptoms have disappeared. The teeth involved are shown in Figure 420. The extent of the areas, as suggested by the roentgenograms, particularly the upper right and left laterals, suggests that the patient has previously had a good power of reaction. The beginning zone of condensing osteitis, forming a boundary about these zones, suggests the onset of a period of less effective defense. This probably dates back to her pregnancy of three years ago. Studies were made to determine the effect upon ani-

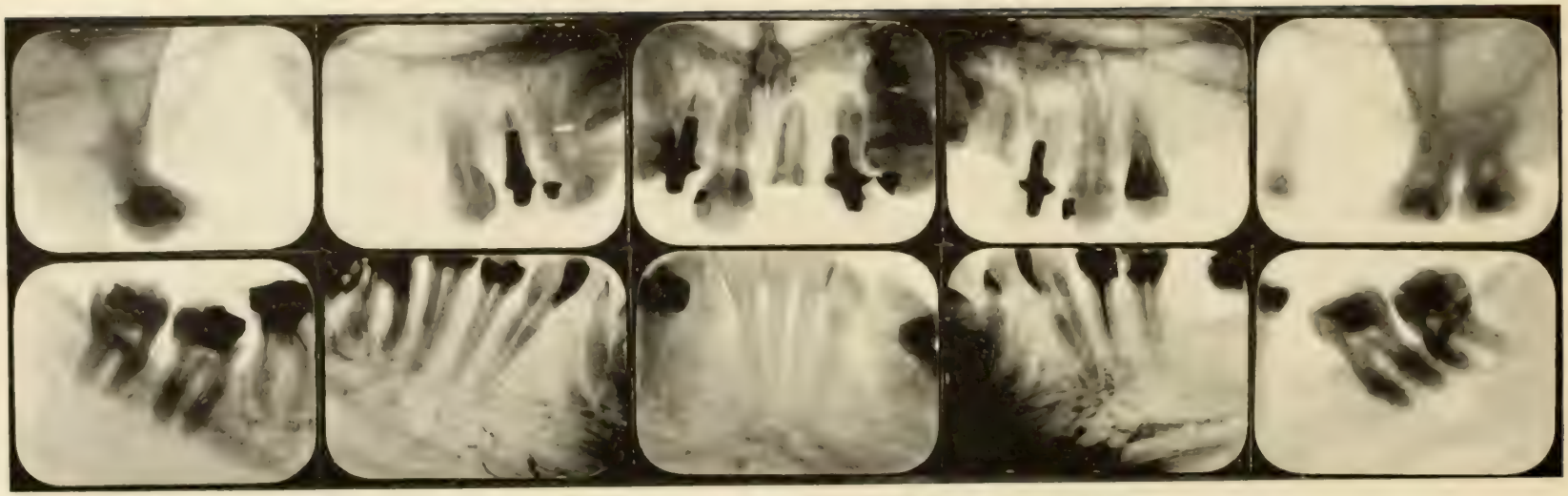

FIGURE 420. DENTAL CONDITIONS OF CASE NO. 402, WITH NERVOUS DISTURBANCE AS CRYING.

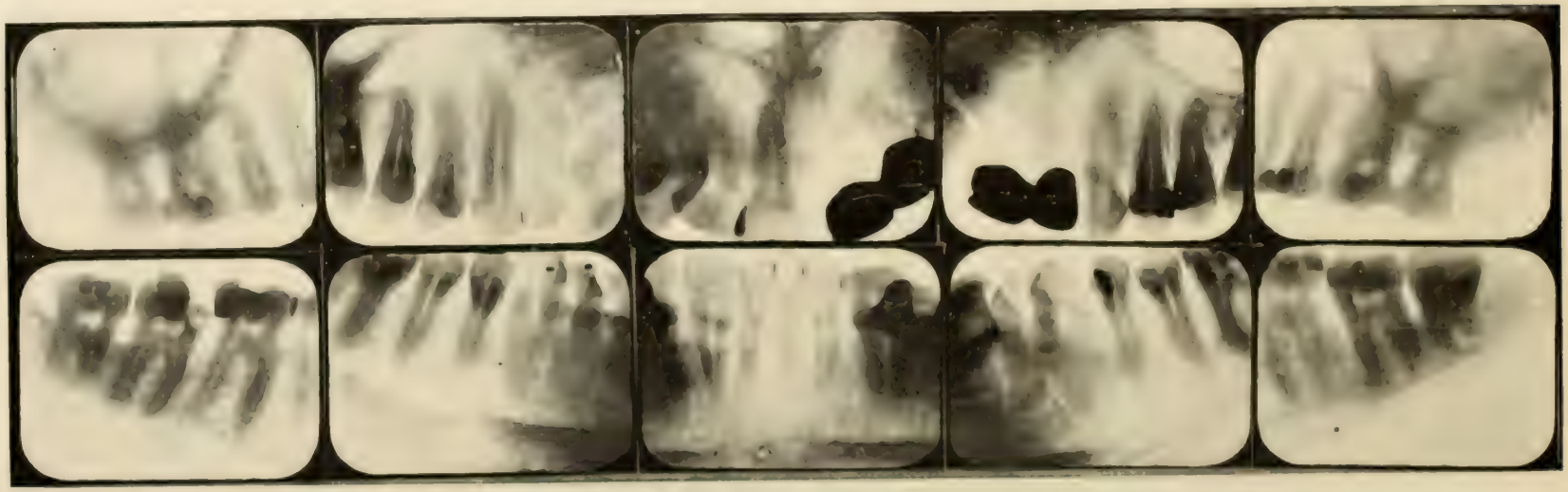

FIGURE 421. ROENTGENOGRAPHIC APPEARANCE OF TEETH OF CASE 1139.

mals, both by direct inoculation and by sensitization with filtered washings from the infected teeth. The effect of the extractions was to improve, greatly, the nervous disturbances.

Lesions of the brain, being in a tissue that does not readily reconstruct destroyed functioning cells, of necessity leave an entirely different type of scar or after effect from a lesion in muscle or even bone tissue. Patients suffering from a toxic or bacterial irritation of central nervous system tissue, brain, or cord, for a period of many months or a couple of years, tend readily to develop permanent lesions. When these affect certain areas of the brain, the only apparent lesion may be as a psychosis. Such individuals are termed queer or insane in accordance with the degree of that disturbance. These lesions may have a large range of expression, and it now seems probable that a very large number of the inmates of our insane asylums are simply illustrations of the effect of a too long maintained focal infection, the toxic irritation of which tended to select brain tissue, with the result of a permanent functional, and though ultramicroscopic, a permanent physical injury. To extract the infected teeth causing this condition after this permanent scar in the brain tissue has been established, should not be expected to cure this extreme disturbance because this tissue does not repair. The appeal of so many of the readers of our dental profession that dental infections that they presume to be slight are doing no harm and should not be disturbed until the patient shows evidence of a physical injury, is in many cases delaying the surgical interference which might prevent a permanent brain lesion, beyond the time when repair is possible. The prevention of the serious and permanent central nervous system disturbances, such as the insanities, can only be accomplished by the removal of the dental infections before the central nervous system tissues are seriously injured. Preventive measures, as a prophylaxis for these individuals, should be accomplished before the trouble begins. Teeth that are potentially capable of furnishing a focal infection are of danger to this type of patient, not so much in proportion to the quantity of that infection, as in the predisposition to the involvement of brain tissue. Hence all patients should have as a part of their study a thorough susceptibility study in order that the weak links of the chain may be found and guarded against before the break comes, rather than waiting for the irreparable break and using it as the danger signal, which is all too late and not sensible medical practice since it is neither preventive nor prophylactic.

We should discuss in this connection reflex irritations as causative factors in producing central nervous system disturbances in addition to the disturbances of dental origin of an infective nature. Such a case is as follows:

Case No. 1082.—A girl of twenty-one has been in a state of serious mental break, consisting chiefly of hallucination and aberration without violent symptoms and maintained as a quite even and constant lesion. The history of the case is as follows: There is a very marked tendency to insanity on her father's side of the family. Several cousins have been affected. About six years ago, while motoring in the East, she and her party found themselves quarantined because of the epidemic of poliomyelitis. The embarrassment and fright brought on a most violent alarm and fear of infection, which is her chief obsession. Every particle of food that she ate had to be boiled and boiled to kill all germs, particularly for fear the germ producing infantile paralysis might be present. If any member of her family had been out riding and brought his or her gloves into the room where she was, she would have a paroxysm of alarm. When brought to my office, she brought her own drinking water which was the only water she would permit to be used about her mouth as well as her own drinking glasses which had been boiled, probably for hours. A sealed jar, glasses, etc., were wrapped in towels that had been baked in the oven until they were brown from the over-heating. Great care had to be taken not to allow the cleaning woman to pass through the part of the building where she was. She would instantly place one of her burnt towels over her mouth. The roentgenograms of her teeth are shown in Figure 422; and, incidentally, the films for these had to be wrapped individually by her in sterile gauze, which she brought for the purpose, before they might be placed in her mouth. The infected molar and the seriously impacted third molar were removed at separate sittings, with so great a change that she invited people to come to see her, who had not been permitted to do so for years; whereas, previously, she would go out of the house only when it was raining, for even her dental appointments had to be postponed until a suitable rainy day was found when there would be no germs in the air, a difficult condition to fulfill in Cleveland. She shortly improved so greatly that these problems largely disappeared. It is quite impossible to say how much of the disturbance in her case was sympathetic, due to the impacted third molar, and how much



FIGURE 422. DENTAL CONDITION OF CASE NO. 1082. MILD INSANITY GREATLY IMPROVED BY REMOVAL OF DENTAL PATHOLOGICAL CONDITION.

to the infective process of the first molar. It is probable, however, that the former was an important contributing factor.

This girl, while very greatly improved, has not returned to normal; nor do we believe that, particularly in the sense of her susceptibility to break of the central nervous system which in her case is an inherited quality, she can ever become normal. In other words, her normal carries a deficiency, which deficiency may become a first factor in the development of a defect.

Case No. 1401.—A still more striking case is the following: A young married woman, age twenty-two, had been in an asylum for two years, with violent spells, which, at one time, required her to be in a strait-jacket. Frequently, her hands had to be tied, and she practically always had to be under guard. When brought to me for study from a neighboring city, she was kept under guard

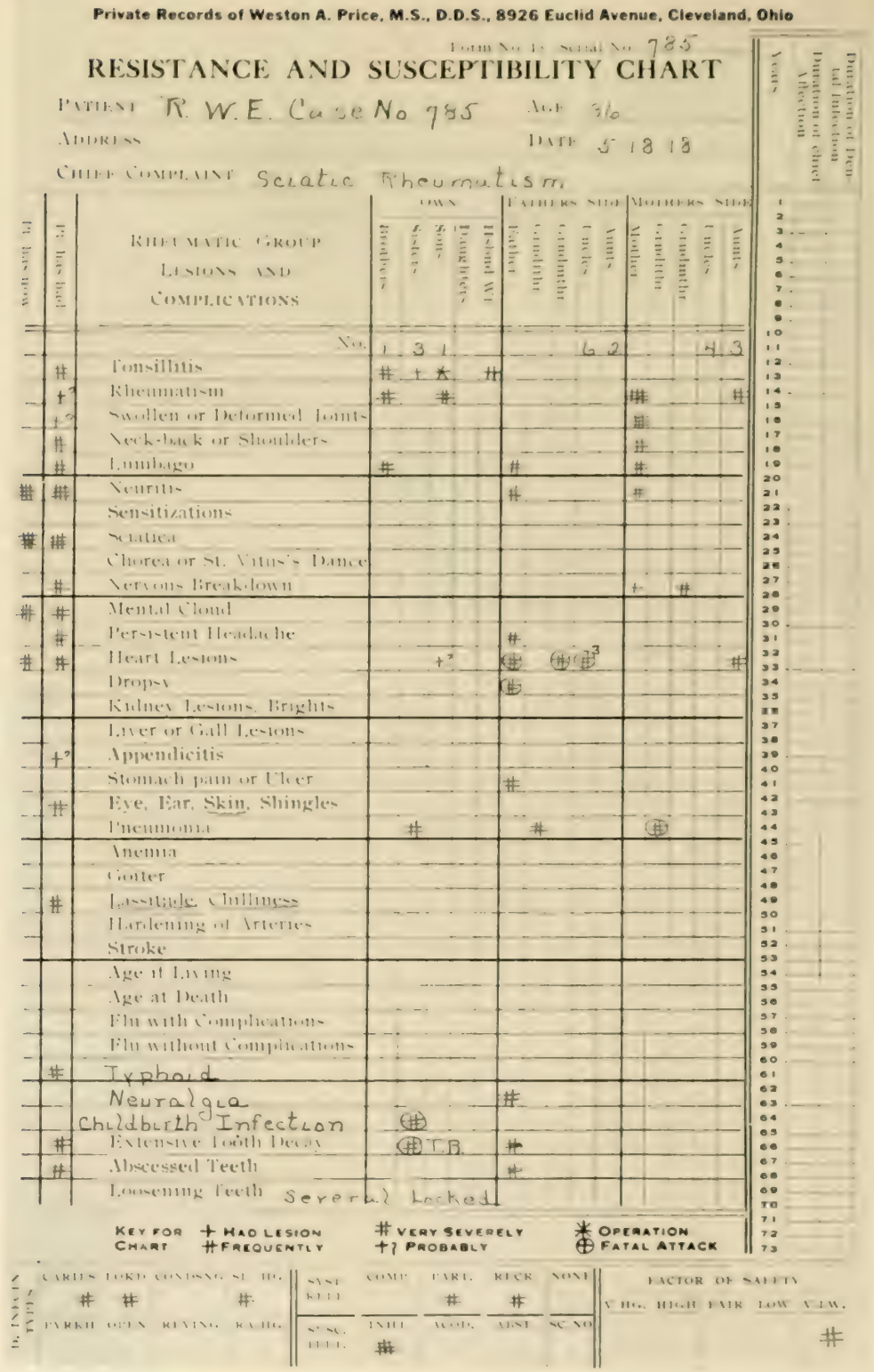

FIGURE 423. SUSCEPTIBILITY RECORD OF CASE 785, WITH SCIATIC RHEUMATISM AND HEART. NOTE MARKED HEREDITARY SUSCEPTIBILITY, WITH FIVE DEATHS FROM HEART INVOLVEMENT ON FATHER'S SIDE AND ONE CASE ON MOTHER'S SIDE.

all of the time. The history indicated that her central nervous system disturbance began about three years before, was progressive in its onset, and there had been no abatement of the severity, or but slight. Her parents said to me how much they wished they could see her die, as they had been advised there could be no hope and her case was getting progressively worse. In about two weeks' time after her return to the asylum, her parents were notified that she could return home, which she did. This occurred in June. The following September she went away to college apparently perfectly normal, took up music, and the following spring stood at the head of her class of sixty, having made a most remarkable record and with no tendency to break. This occurred six years ago and she has had no break since. In order that I might have a late report of her case, I have just written to her mother regarding her, and she writes, "M——is as well in every way as a girl can be." A study of the family history reveals that her father had suffered from a very serious nervous breakdown, her mother a less serious one, and her brother had a mental obsession.

In this connection, it might be inferred that insanity may be due, generally, to dental infection. This is so far from being the case that we deemed it best to illustrate a case in which there is no apparent connection between the dental and the mental lesion.

Case No. 1139.—The patient, a man age thirty-six, had been in an asylum for the insane for several years with recurring attacks of a very serious mania in which he would not recognize even his nearest relatives. These periods would last for days and would be followed by states of apparent normality. The roentgenograms of the dental conditions are shown in Figure 421. It will be noted that his teeth are all apparently normal except the lower left second molar which had recent caries, extensive but not seriously involving the pulp. Thermal and electrical tests of his teeth indicated them to be normal. We advised that the dental conditions were not responsible for, nor contributing seriously at present to, his mental condition. The only questionable tooth did not have a history extending back over the period of mental disturbance. This tooth was extracted as a matter of prophylaxis; but, as we expected, there was no improvement in his condition. If, however, this patient had developed a series of one or more serious dental infections, particularly of a locked area type, this source or any other source of streptococcal infec-

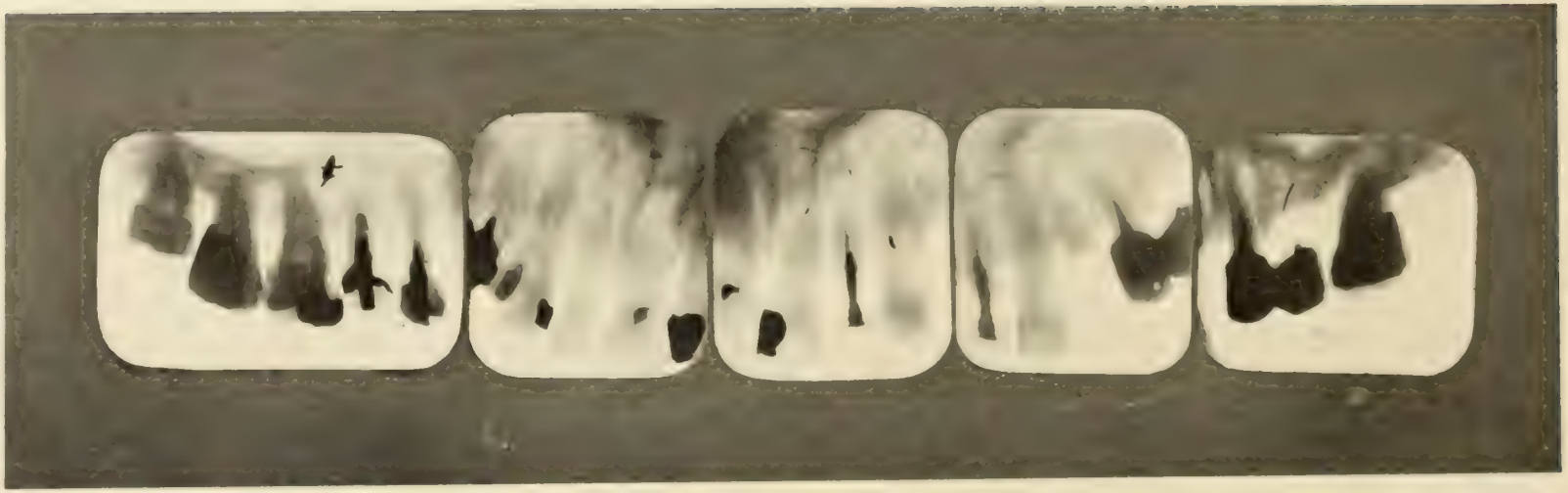

FIGURE 424. DENTAL CONDITIONS OF CASE NO. 1139, SUFFERING WITH ACUTE NEURITIS, COMPLETELY RELIEVED BY REMOVAL OF DENTAL INFECTIONS.

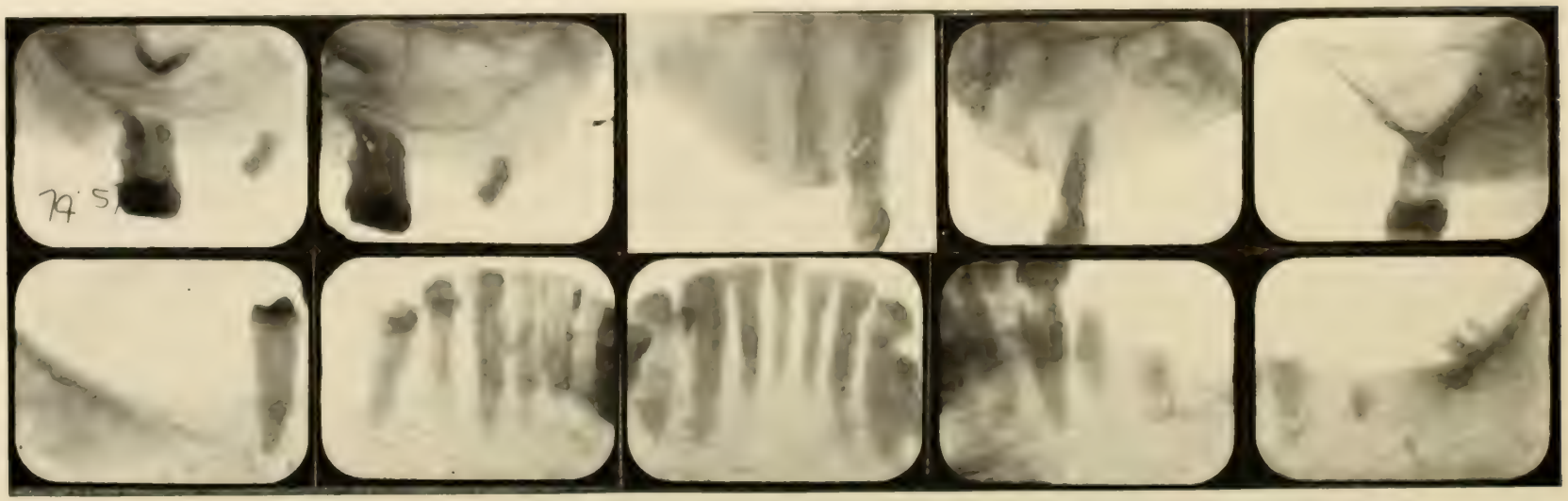

FIGURE 425. DENTAL CONDITION OF CASE NO. 805, BOOKED FOR AN INSANE ASYLUM AS A BEDRIDDEN INVALID WITH PALSY. REMARKABLE RELIEF FROM REMOVAL OF HER DENTAL INFECTIONS.

tion, and probably several other types of infection, would have tended to aggravate the mental lesion.

There is, however, a type of border-line case that is exceedingly difficult to interpret. The patients who are at best living in a zone of marked tendency to nervous affection will have that condition aggravated seriously by dental infection. Such a case is illustrated in the following:

Case No. 785.—The patient, age thirty-six, had been in bed for six months approximately, with acute neuritis and nervous symptoms. He had suffered very severely. The removal of several dental infections, while he was in bed, made an immediate improvement which was practically complete so far as his neuritis was concerned. His irritable nervous system, however, was a constant menace; and while he has had no return of his neuritis for four years, each type of overload, worry, and exhaustion, has tended to bring about a nervous break. His heart condition, which was alarming during the period of his acute neuritis, has so greatly improved that he takes care of a large business effectively.

A study of his susceptibility chart, shown in Figure 423, illustrates the marked inherited susceptibility. He has strongly inherited nerves and rheumatic susceptibility from his mother and heart susceptibility from his father's side of the ancestry. It will also be seen, that his father, his father's mother, and three of his father's brothers died of heart affection. One of his mother's sisters has a heart affection. We must, therefore, come more to think of the host and his or her normal defenses as being the most important fundamental factor; for a normal high defense may, and usually will be, ample to defend people against even large amounts of dental infection during the greater part of their lifetime; but people without that defense are already in grave danger; and insurance companies will doubtless come to place great stress upon the presence or absence of streptococcal susceptibility, and the individuals without the normally high defense will receive less consideration than those with an ample streptococcal resistance in so far as their inherited susceptibilities are concerned.

A striking illustration of an extreme neuritis in an individual with, normally, a high defense is shown in the following case. Case No. 449.—This patient, male, age forty-three, had so severe a neuritis in his back and hips, which had lasted for twelve weeks and had been progressively getting worse, that he could not sit in a chair; he had either to stand or lie down. The removal of the dental infections, shown in Figure 424, completely relieved his

neuritis in about three days; and in five years' time, there has been no recurrence. His susceptibility chart shows his case to be one of strikingly acquired susceptibility, there being no evidence of neuritis in either the immediate family or his ancestry. This is the type of case in which a prognosis should be considered favorable.

NERVOUS BREAKDOWN.

Of the many nerve lesions, probably none are more pitiable than those involving the mind. However, if there is coupled with the mental break an acute neuritis, the case becomes much more distressing. An illustration of such a case is the following:

Case No. 805.—Arrangements had been completed and the day set for taking this patient to an insane asylum because of a palsy that made her a supposedly hopeless bedridden invalid. The palsy of her extremities began about four years ago, with increasing severity, with its onset as a nervous breakdown; and her prostration was accompanied by severe pain of obscure neuralgic nature. She was carried to our ward. The condition of her teeth is shown in Figure 425. There was an early and very marked improvement after the removal of her dental infections, which expressed itself in the mental lesion, the palsy, and the neuritis. Within a few weeks after the removal of the dental infections, she was so greatly changed that she returned to the office alone on the street car, and walked without difficulty, without even a cane. Notwithstanding her age of sixty-seven, instead of being an embarrassing burden to her household, she became very helpful, for she not only was able to take care of herself but assisted in taking care of others.

CHOREA

As previously stated, of the many lesions produced or aggravated by dental conditions, few are more distressing and baffling than are those of the central nervous system, affecting the mind. In our mixed clinic we find that, approximately, seven per cent of the patients presenting for study of the relation of systemic disease to dental infection are recorded to have had mental cloud. We have seen so many times an improvement or complete relief by the removal of dental infections that we have come to think of these functional disturbances as being pretty largely the result of structural change due either to bacterial or toxic invasion. In children these affections may involve both lack of coördination and more or less severe psychic irritation, characterized by the

patient's irritability and impetuosity, and even violence, all of which so often make up the picture of chorea. A typical illustration is as follows:

Case No. 458.—The patient, nine years of age, was brought by his mother with the following history. As the tears streamed down her cheeks, she said, "Why have my husband and I been cursed with such a wicked boy? The teacher sent him home with a note saying that if he returns she will leave the school. He cannot play with children without slapping them in the face or some other unpardonable violence without provocation. He does this also to his father and to me. While keeping him out of school, since we have to, I thought it would be a good time to have his teeth taken care of, etc., etc." We made a few studies of the boy and soon found that he had largely lost his power of coördination. He had a very sharply developed symptom group chorea with an exaggeration of the irritability phase. While undertaking to make roentgenograms of his teeth, he would strike me in the face without any provocation. In addition to making these studies, we made motion pictures of his lack of coördination. It was apparently impossible for him to sit still, and every moment he was twitching and jerking and, as such patients do, would try to turn an involuntary muscular contraction into a voluntary one. He would find his knee jerking up, and, in order to avoid the embarrassment, would turn it into a kick; and similarly with his hands. If he had something in his hand at the time the involuntary reflex occurred, and his hand started swinging, he would let the article fly as though he had intended that to be the movement. We do not wonder that his teacher had reached the limit of her capacity to control, for no ordinary power could control him, not even his own mind. We explained to the mother that her boy was not a bad boy; that he had an infection of the cortex of the brain, probably largely coming from his infected teeth; and that when his infection was removed he probably would return to normal. With very great difficulty, because of his extreme condition, we succeeded in removing the deciduous teeth which were deeply carious, several of which had infected pulps. These were cultured and animals were inoculated, several of which developed very acute involvements of the central nervous system; and we had four at one time of this series with such marked central nervous system disturbance that with little excitement they would fall on their sides. Sections made from the cortex of the brain showed multiple petechial hemorrhages and diplococcal zones of

infection. Immediately after the removal of these teeth the boy's condition improved and very rapidly he returned to normal. In two weeks' time he was back in school, a normal child, and has not had a single recurrence in five years.

I have young patients whose histories are so definitely suggestive of this type of affection, since they have previously had involvements of chorea or acute nervous affection with irritability, that I have warned their parents to be sure to let me know if at any time these symptoms became apparent and to bring the child in. Such a case is as follows:

Case No. 1402.—The father had been a partial invalid from a heart involvement and rheumatism. His father had died at about fifty years of age from heart involvement. This lesion had been dominant in the father's side. The mother had the history of nervousness which had been dominant on one side of her ancestry. The oldest child had died under a simple operation from streptococcal septicemia, the susceptibility to involvement from which organism is definite in both sides of the ancestry and which in great probability accounted for her being such a poor risk. This child had, at different times, had marked nervousness. With the attack in question, the mother called me on the phone and said that her little girl had developed just such symptoms as I had advised her to watch carefully for; that she had been sent from school, would slap her parents in the face and drop things, so characteristic of choreal patients. On account of the marked familial susceptibility to streptococcal infections, I desired that she should not, under any circumstances, have an infected pulpless tooth. This patient was exceedingly hard to operate on and the tendency to caries was very great. In spite of our effort and care, largely due to the lack of cooperation, she had developed an infection of the pulp of a deciduous tooth from a proximal caries. On being given this information over the phone, I arranged to have the child brought to the office immediately; and on finding the difficulty, arranged for a very early operation for the removal of the infected deciduous tooth shown in Figure 426. This was done on Saturday morning, and on Monday the mother telephoned me that her daughter was so much improved that her nervous twitching had stopped, her irritability was practically gone, and she thought she could go back to school. Kindly note the lack of roentgenographic evidence of a putrescent pulp in the first deciduous molar.

When we think of the tragedy of ignorance during all the past



FIGURE 426. INFECTED DECIDUOUS MOLARS, WITHOUT ROENTGENOGRAPHIC EVIDENCE OF SAME, WHICH WERE PRODUCING CHOREA IN A CHILD. CASE NO. 1402.

centuries, and so little improved in our own generation, our hearts go out to the child life which has been misunderstood amidst all its suffering. History records that a few centuries ago it was a practice to drive these children with switches to the tomb of St. Vitus with a hope of the removal, thereby, of their affliction; and this seems to have been the origin of the name St. Vitus's Dance. How many children today are suffering from such infections we can only guess, but from the number I see, I am convinced that the affliction is a very common one; and its pathology strongly argues in favor of the removal of all infected deciduous teeth and, primarily, for a program of prevention through nutrition and prophylaxis that will make the development of the caries, which shall infect those teeth, impossible. This will only be brought about by an intelligent dental profession, guiding wisely, and creating a well informed public, which latter has shown evidence of being just as anxious to learn as has the dental profession.

NERVOUS EXHAUSTION.

Few, if any, of the lesions of the body which may come under consideration as being influenced by focal infection, and particularly dental infection, are so obscure as the so-called functional diseases of the nervous system. We have thought of functional diseases as being something entirely different from those due to structural changes. It is a question, if there be such a thing as a functional disease without structural change; indeed, there probably cannot be.

The patient whom we shall use as an illustration of this type of lesion suffered from a group of symptoms, some or all of which are exceedingly common; and her case had been diagnosed by her physician as one of hysteria. At times she had severe pain in various parts of her body, for which no adequate cause could be found. She frequently had an extreme sense of fatigue and weariness, for which also no cause was found. At times she had symptoms of a heart involvement, and with it all, a sense of mental

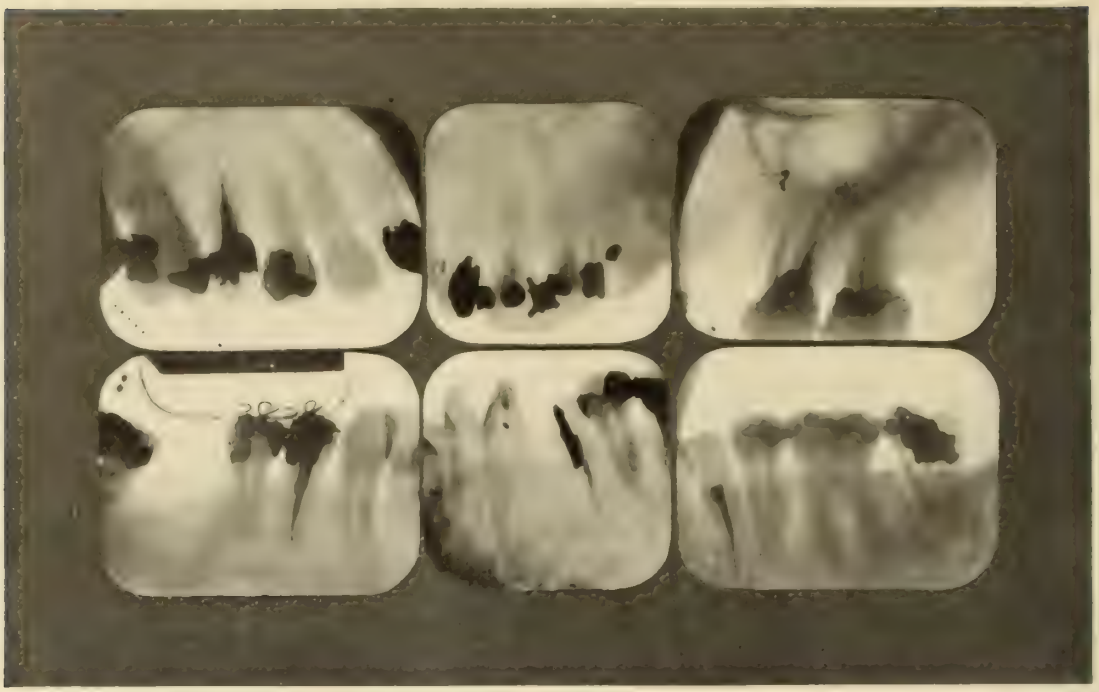

FIGURE 427. ROENTGENOGRAPHIC APPEARANCE OF TEETH OF CASE NO. 335, WITH HYSTERIA AND LASSITUDE. SEE NEXT FIGURE.

cloud and depression against which she had to struggle. For about five years she was compelled to be out of employment, approximately half the time because of inability to work. At times she could hardly compel her mind to do simple problems. One physician, thinking he had found the trouble, had an ovary removed. At another operation, the appendix was removed; and at another, the tonsils; none of which produced any marked change in her condition.

Her dental conditions are shown in Figure 427. A striking and typical illustration of the type of dental pathology that developed in her case is seen in the lateral, the pulp of which is non-vital. There was no history of soreness, exceedingly limited zone of apical absorption of alveolar tissue, and no fistula, and never had been; the very type of local condition which we now interpret as indicating an inadequate reaction on the part of her system adequately to protect her against her own infection—an inefficient local quarantine.

In order to understand this case, it is necessary to go back and analyze the measure and quality of her defense or susceptibility, the nature of her overloads, and the type of inheritance that would establish her defensive mechanism. This is shown in

Figure 428. The patient's age at that time, seven years ago, was thirty-four. Her net weight was about 103 pounds. Her chief disturbances have been rheumatism, a type of nervous breakdown, and heart involvement, with operations for appendix, ovary, and tonsils; and she has been breaking seriously, young in life. A study of her brothers and sisters shows that her only brother died of a heart infection at six years of age; and that he had acute rheumatism and chorea. She has five sisters, two of whom have had acute rheumatism, five nervous involvements, and two acute heart involvements. Her father died of acute heart involvement at sixty-five. He had very marked sensitization as asthma. Two of the father's sisters had had very severe nervous disturbances and died of heart involvement, and all three had heart involvements. Rheumatism and heart were very dominant in the father's side of the ancestry. The mother and her brothers and sisters had been mildly susceptible to rheumatism, and two of her sisters and a brother had had heart involvement. The mother's mother had a heart involvement. A great grandparent on the mother's side had been chair-ridden from deforming arthritis. There had been nine cases of heart involvement among the immediate relatives and ancestry, four of whom had died; and if the second cousins were included, the number would be increased to sixteen. Her father was a sufferer from asthma, which frequently made him very greatly distressed; and as we now understand that disease to be a sensitization process and know personally of the symptoms, believe it was sensitization and an allergic reaction to a certain weed, that grew abundantly in a certain field of his place. We would, therefore, interpret her case as being one of inherited low defense to streptococcal infection; and probably definite susceptibility by inheritance from her father to sensitization reactions. The type of dental pathology also, as outlined, indicates low defense.

As this case has been in my care during the last fifteen years, I have had an opportunity not only to observe the various and changing symptoms, but to study them critically, in connection with our increasing knowledge of the nature of dental infections and their reactions. From the standpoint of the development of the history, it is important to know that we adopted a very conservative program. One or two at a time, only, of the teeth were extracted, which had had root fillings placed within them and which we interpreted as having insufficient pathology to account for her disturbance. After each extraction, there would be marked

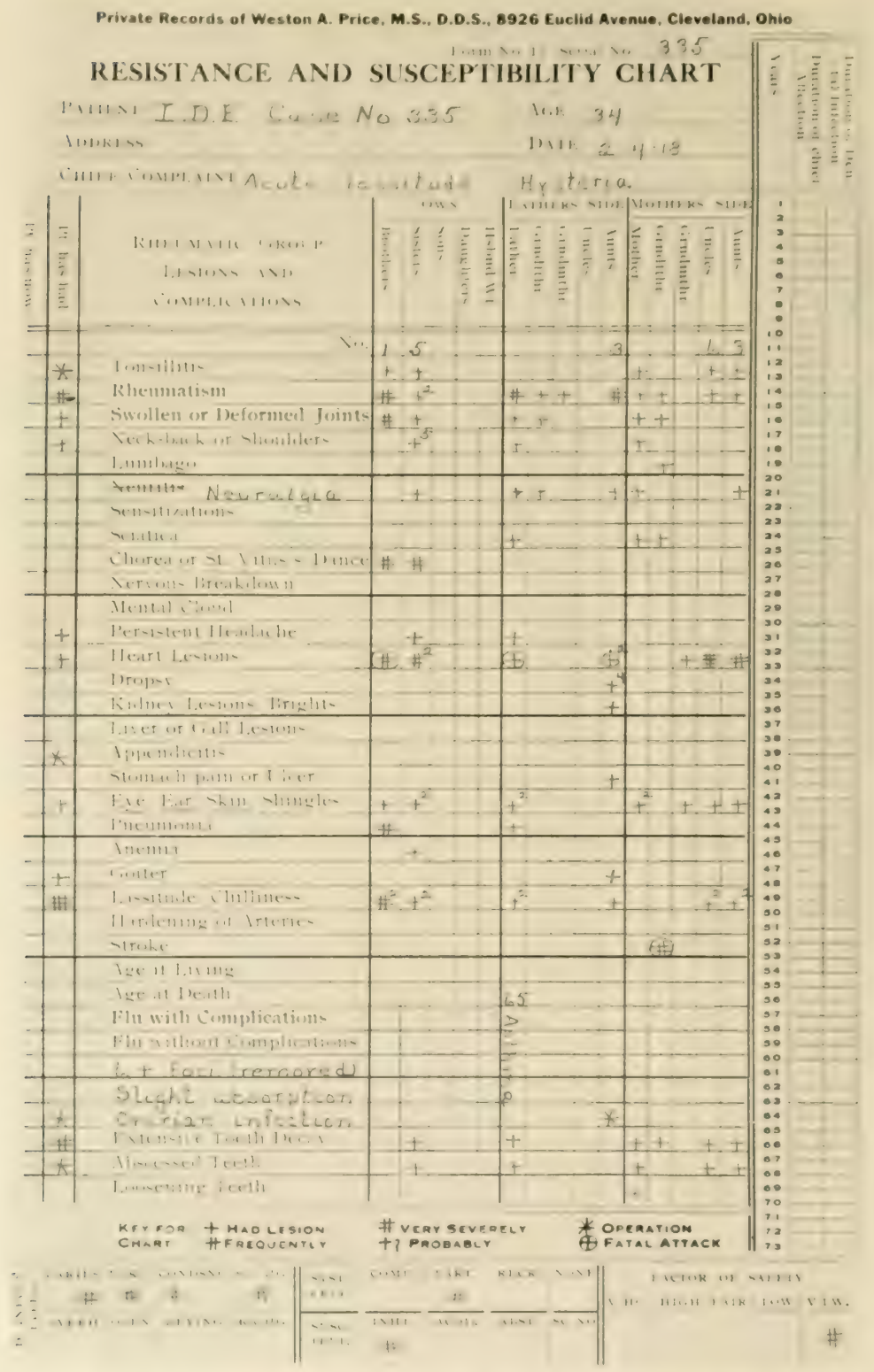

FIGURE 128. SUSCEPTIBILITY RECORD OF CASE NO. 335 SUFFERED ACUTE LASSITUDE, HYSTERIA, HEART, AND RHEUMATISM. NOTE TEN CASES OF HEART INVOLVEMENT IN FAMILY.

improvement which, however, would be temporary. Autogenous vaccines were made from the cultures of these teeth, and these gave definite but temporary relief. From time to time, during a number of years, the clinical picture would improve after the extractions and use of the vaccines. The subnormal temperature, ranging about 96 in the morning to 97 in the afternoon, would come up, under the influence of the vaccine, a degree or a degree and one-half, and, accordingly, be normal in the afternoon. This patient, like all of her class, was always sensitive to cold; and this symptom would always improve. At times, she developed bursitis; on another occasion, herpes; but the chief lesions were obscure but definite pains with or without a sense of weakness in her limbs; and above all, the sense of lassitude. With the removal of her last root-filled tooth, these symptoms improved as they had with the extraction of other teeth, with the exception that the improvement was much more marked; and in five years' time there has not been a single recurrence of any of the symptoms, sufficient to make her lose a day of time from her work. She has gained in weight. Her general physical and nervous condition has come to, and remained upon, an entirely different level from where they had been for fifteen years previously. She was in the position of being criticized by her physicians and most of those with whom she came in contact as having affections which were largely imaginary, or that she was enjoying her discomforts.

We believe she is typical of a class containing a large number of individuals whose condition is partly one of sensitization, which sensitization is an allergic reaction to a protein, being generated within the individual's body as a result of bacterial infection, and which antigen may be present in sufficient quantities to produce such reactions, in even a root-filled tooth without periapical evidence, as revealed by the roentgenogram; that a normal individual will destroy this antigen or neutralize it by an antibody-antigen reaction close to the tooth; whereas, this patient, not producing such a reaction, permits that antigen to invade the system and irritate the tissue that has become sensitized to it. In the chapter on Sensitizations we have discussed the nature of these reactions and methods for diagnosing them. We believe these cases are also continually subjected to bacterial infection of this type from these root-filled teeth, for all of the teeth extracted from this patient were found to be infected.

Another important phase of the expression of this case is of particular interest because of its possible relation to a type of



FIGURE 129. DENTAL CONDITION OF CASE NO. 1367, SUFFERING WITH ATTACKS OF EXTREME LOSS OF MEMORY. THESE WERE OCCURRING WITH INCREASING SEVERITY AND FREQUENCY. VERY MARKED RELIEF UPON REMOVAL OF DENTAL INFECTIONS.

mental disturbance, the etiology of which has been very obscure, and which relates to an affection of speech which is limited to certain words. One of the words in this case was *total*, and it not only required distinct mental effort to write it, but produced a distinct sense of pain. Another expression was the inability to remember certain names and words that were very simple.

This memory disturbance may take on a very extreme or alarming expression, an illustration of which is the following case: Case No. 1367.—This patient presented with a history of attacks of loss of memory with increasing severity, extending over a period of four years. The last attack had lasted five days and he was so nearly void of mentality that he would eat when things were put before him but lacked judgment regarding eating. His attacks would come on with at first a sense of excitement, then extreme nervousness, followed by a period of crying. During the onset of his last attack he drove his automobile thirty-five miles in forty-eight minutes on dirt country roads and could not recall the trip or any incident in connection with it. His history showed that several years ago he had several teeth covered with gold crowns, as shown in the roentgenograms, Figure 429, some time after which he began developing these serious symptoms. His first attack was brought on while moving a troop of soldiers to encampment during the war, at which time, as the commanding officer, he was without sleep almost continuously for four days. The first symptom was a slight and transient disturbance of memory. He has seen impending the probabilities of a madhouse where he would be a helpless idiot, since each attack, coming in regular succession, was progressively worse than the preceding. His present joy can be imagined from the fact, that since the removal of the gold crowns and the infected teeth he has not had one single attack. A study of his susceptibility and that of the family reveals his exceptionally high inherited defense on both the father's and mother's sides.

The patient's own description of the change is significant. When first examined a month after the removal of his infections he was looking very much better, had gained six pounds, stated that he had been entirely free from his feeling of mental cloud and tendency to lapse of memory. He described the former condition as being one in which he had been going up an incline for four years, during which time he never once returned to normal as he has since the removal of the dental infections, as though he had

returned from that elevated plateau of strain, pressure, and mental cloud, back to a lower plane. During that period he was under a sense of pain and cloud, which conditions have entirely disappeared and he has a feeling of buoyancy. He looks quite different in the face and has a mental alertness that is apparently normal. He expresses his former condition as one in which he would have to stop to think to answer simple questions, as, for example, "How much do two and two make?" When crossing the street, he would have to stop and study what crossings were and where they were. When these attacks first started, his brain seemed to act as a slow moving picture. At the time he presented he had been suffering from that attack for eight weeks, which was the longest that any of them had lasted. The longest previous had been four weeks. At the time of his first presentation his facial expression was that of frenzied delirium. His eyes were bloodshot and staring, his face drawn as though he had been through a horrible and harrowing experience. Within a few days after the removal of his dental infections, these symptoms rapidly disappeared. His case had had the most painstaking and skillful care and study by internists during these four years, the physician who sent him from another city being convinced that all other sources of possible cause had been excluded.

In interpreting his case we must keep in mind that capacity for endurance is a relative matter and always relates to overloads. It is probable that his first but mild break was dependent upon both his locked dental infection (for pulps were found non-vital in some of the crowned teeth) and his extreme strain and overload, carrying out his war duties without proper rest and nourishment. Had it been due entirely to the latter he doubtless would not have had recurrences when he came to a normal program of life again. But he quite soon came to a point where even with the most exacting care these conditions developed. His is a case of acquired susceptibility in an individual who normally should have a very unusually high defense both by personal physique and inheritance, and demonstrates that it is not sufficient to build our trestles with a strength sufficient for the ordinary load, but always provide for a factor of safety, for every individual will have some overload and many will have excessive overloads at times in spite of all good planning that they or we may do for them. The responsibility of dentistry is very clearly to refrain from building not only additional sources of overload, but sources of toxin and infection which are the neglected camp fires that

start the conflagrations which devastate the forests. But, as the brush would not take fire without ignition, so these serious breaks in the nervous system frequently cannot come without a source of toxin.

EPIDEMIC LETHARGIC ENCEPHALITIS.

In discussing this very severe group of disturbances of the central nervous system, we are dea.ing with one of the most distressing of human afflictions, for many of the individuals are doomed to a life of broken mentality or dismantled nervous system, or both of these conditions, to eke out an existence that is almost unbelievably painful and pathetic both for themselves and for those with whom they are in contact. I shall not undertake, for lack of space, to review its symptomatology except to review that any structures of the central nervous system may be attacked, and, when attacked, the probabilities of a permanent lesion are very high. If they do not die within four weeks, the prospects are that they will live on perhaps indefinitely. They may have any degree of paralysis from a single group of muscles to practically the entire body. A brief statement is as follows: "A disease of obscure pathology and showing unusual cerebral symptoms, the distinctive features being an increasing languor, apathy, and drowsiness, passing into lethargy. There is progressive muscular weakness and various cranial nerve palsies." (Dorland) In the current press it is spoken of as "Sleeping Sickness" because that mental apathy and drowsiness are often interpreted as sleep. There is no generally accepted etiology though a diplococcus has frequently been isolated from these cases. In the case that I shall review I do not know that we have been dealing with the causative organism though several factors have been very suggestive that we have.

The woman, age thirty-six, was brought to us with spasms of the face, with the grating of her teeth, twitching of the left arm, and drawing up of the legs, and was so horrible to look at that some of the members of my staff found it necessary to leave the room. The involuntary grating of her teeth could be heard through the surrounding rooms from where she was sitting; and, needless to say, she had loosened several of them from the uncontrollable and violent spasms of the muscles of mastication. At times the attacks would come on so violently and suddenly that the snapping of her teeth would endanger a serious wound to anyone having a finger between them. This trouble came on following an attack of Flu three months previously, which is the history of

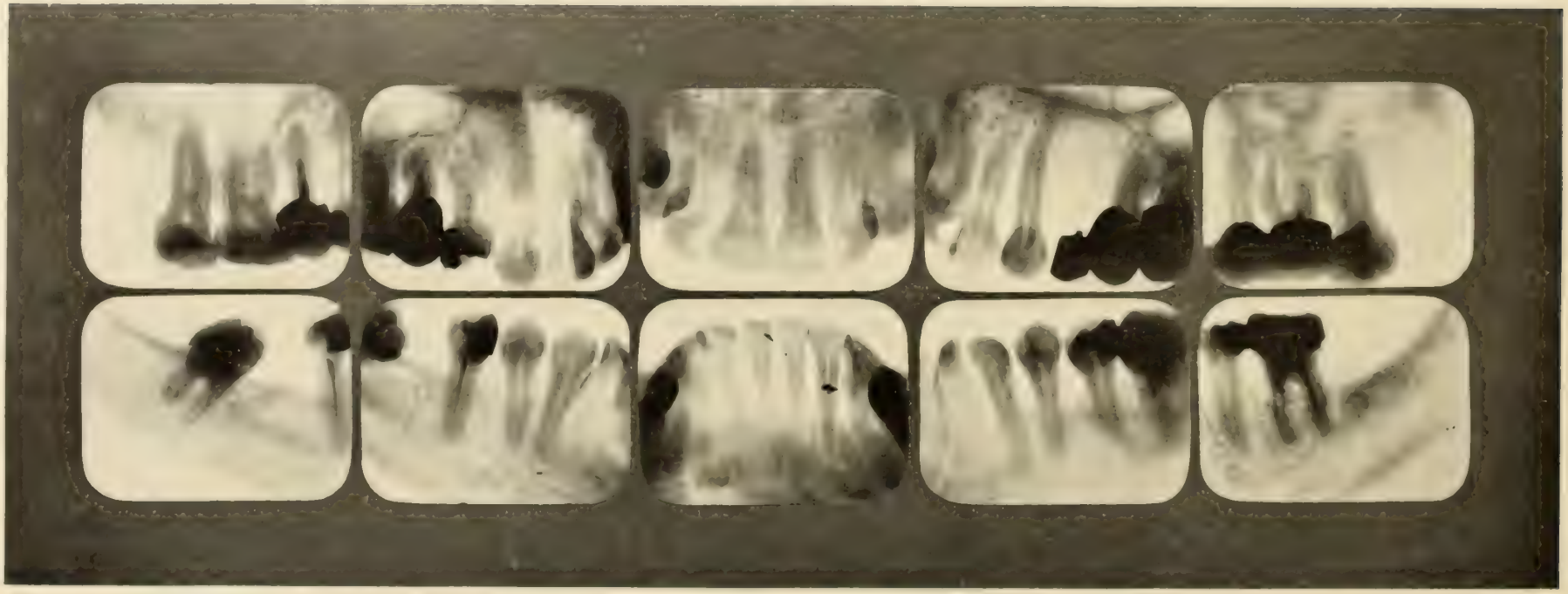

FIGURE 130. DENTAL CONDITIONS OF CASE NO. 1317. PATIENT SUFFERING FROM LETHARGIC ENCEPHALITIS.

many of these cases. The diagnosis was verified by a neural pathologist and the prognosis was, of course, considered very grave, and our efforts were devoted to studying the relation of dental infections, if any, to her condition and to the making of supports that would sustain the violent spasms without the complete destruction of all of her teeth. The neurologist took charge of her medical care.

Her dental conditions, as she presented, are shown in Figure 430. When these infected teeth were studied by our various means, including planting beneath the skins of rabbits, it was found that they contained an organism which at that time we thought to be very exceptionally virulent. We have, however, since found several instances where teeth were quite as rapidly fatal from patients who had no such symptoms. One of the teeth from this case at the time of this writing has been planted beneath the skins of over thirty rabbits, all but two of which died spontaneously within a few days, averaging about four days, the longest being ten days. Two were chloroformed just before death for study. Several other teeth from this patient were studied in the same way and all produced comparable results.

In the course of our studies the planted teeth were placed in the subcutaneous subdermal tissues, chiefly of the back. Another method of study was to place a very small quantity of these germs, under aseptic conditions, subdurally through a very finely drilled hole of the frontal brain. As controls, cultures were used from other sources. In one instance the rabbit produced violent spasmodic grating of the teeth in about two hours, which lasted for about five hours and ended in death, very strikingly similar to those suffered by the patient. We are not justified in concluding that this is specific for elective localization or reproduction of identical symptoms, since infective meningeal involvements sometimes produce these symptoms and we were able to produce similar though not identical reactions with other strains, not, however, so characteristic and violent. In two rabbits, one of which was inoculated with the aspirated material from about the tooth that had just killed a rabbit, and the other with this same material passed through a Berkefeld filter, the former died in a few hours with characteristic spasms, the latter lived for weeks, indicating that there was not free toxic substance within the bacterial growth. Intravenous inoculation of this strain did not produce typical lethargic encephalitis in rabbits. This, however,

FIGURE 131. DENTAL CONDITIONS OF CASE No. 904, WITH ACUTE INFLAMMATION OF THE SCLERA AND RETINA OF THE RIGHT EYE.

FIGURE 132. DENTAL CONDITIONS OF CASE No. 1087, WITH COMPLETE BLINDNESS IN RIGHT EYE, LEFT EYE ONE-FIFTH NORMAL

may not have significance since the history of inoculations with this strain isolated from patients suffering from this disease have been found by other workers not to produce the typical lesions of the nervous system unless inoculated subdurally. Several things are important for consideration, and these we may put in the form of questions.

(1) Since the etiology is so obscure, and since a diplococcus has been found by many of the investigators, is it possible that the growth in the individual's body of the organism or organisms producing the symptom group of influenza may create a condition which induces the streptococci or diplococci growing in dental infections to develop this type of tissue affinity?

(2) Is it possible that a specific strain of diplococcus or streptococcus becomes a contaminating factor in dental infections and, by residing in that nidus, maintains a perpetual infection of that individual's body through the dental channels?

(3) May it be possible that a specific organism gains its entrance into the body through carious teeth?

These are all problems of the most pressing character and demand the best attention of the profession which can only be given by an adequate program of research which is not being recognized today, and which can only be undertaken with hope of the largest possible success in a specially organized institution where that problem along with others of the dental group can receive the merited study.

EYE.

No part of this work has been more striking and satisfactory than the relief in cases of eye involvement, of which there have been many types. A very striking and common type has been affections of the various coats of the eyeball. These can probably be best discussed as individual cases.

Case No. 904.—The patient, male, forty-five years of age, good health, presents with an acute inflammation involving, with other structures, the retina and sclera of the right eye. The dental conditions would not be considered serious if judged by the roentgenograms, shown in Figure 431. Two of these teeth were extracted: namely, the right maxillary first molar and first bicuspid. Cultures were made and the culture inoculated into five rabbits. Four of the five developed acute affection in various structures of the eyeballs. This patient's inflammation was so acute that he was compelled to be in a darkened room for weeks, and the vision, which had been reduced to about one-fifth normal, was

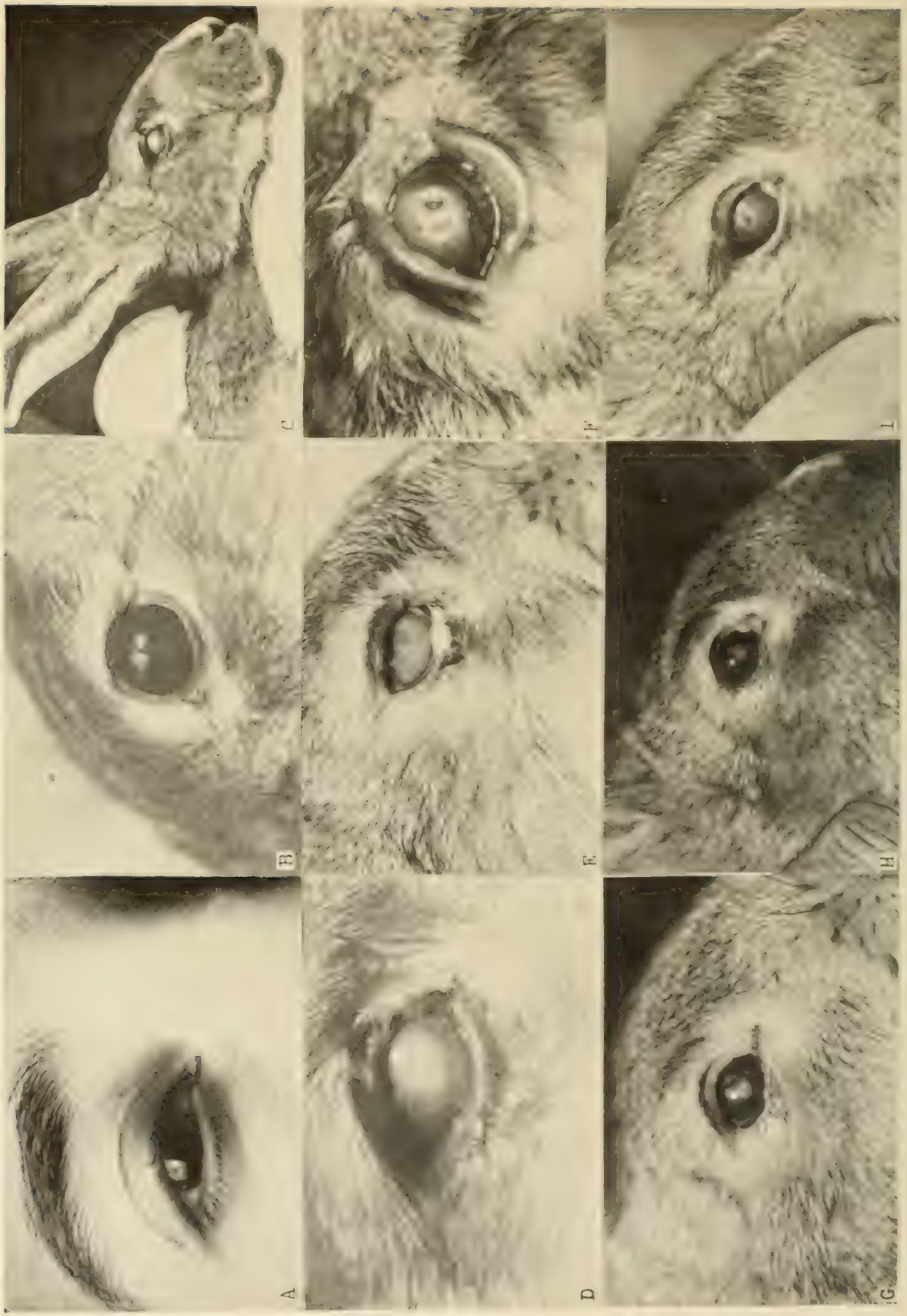

FIGURE 433. PROGRESSIVE INVOLVEMENT IN RABBIT'S EYE, FROM DENTAL CULTURE FROM CASE 904 WITH RETINITIS.

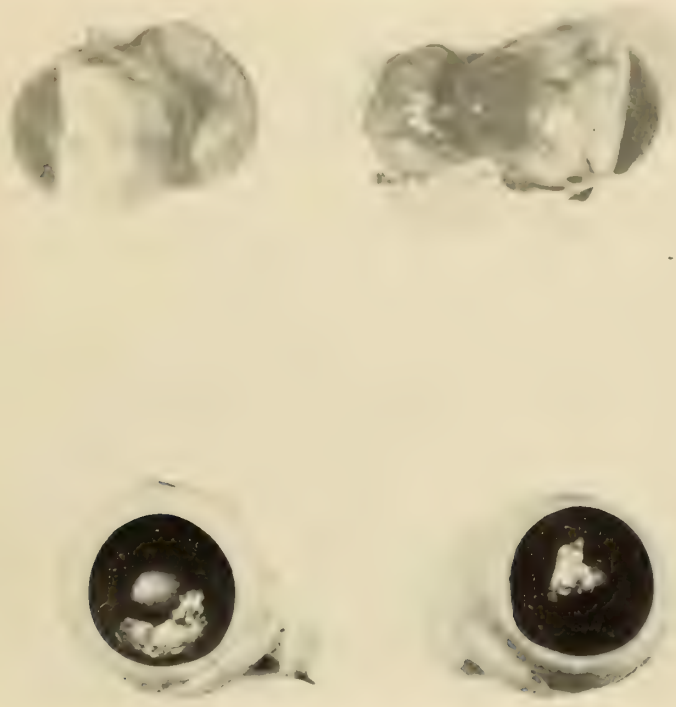

FIGURE 434. OF FIVE RABBITS INOCULATED WITH CULTURE FROM TEETH OF CASE 904, FOUR DEVELOPED ACUTE EYE INVOLVEMENT. TWO SHOWN BELOW HAVE ULCERS, AND TWO ABOVE ACUTE INFECTION OF MUSCULATURE.

considered in great jeopardy. One of the rabbits inoculated with this culture developed lesions which were strikingly severe. This is shown in Figure 433. A shows the typical appearance of an eye in this condition. Reading from left to right, will be seen different stages of the rabbit's right eye. First, a violent general retinitis and choroiditis, shown in C; in D, taken a few days later, the vision had entirely disappeared; in E, a deep ulcer is developing; in F, the extent and depth of the ulcer is revealed, also a very marked conjunctivitis; in G, repair has set in but the vision is gone; H and I show later stages of the healed scar but no return of the vision. B shows the rabbit's left eye which remained normal during the entire period. This rabbit was kept for nine months and posted and the eye retained as a specimen. Other eyes from rabbits of this series are shown in Figure 434, revealing very marked involvement of the sclera and musculature.

The most striking thing about this case is the history. This man's father is living and is partially blind in one eye. His father's mother lost the sight of both eyes and died blind, and her mother also died blind. In eleven hundred rabbits inoculated,

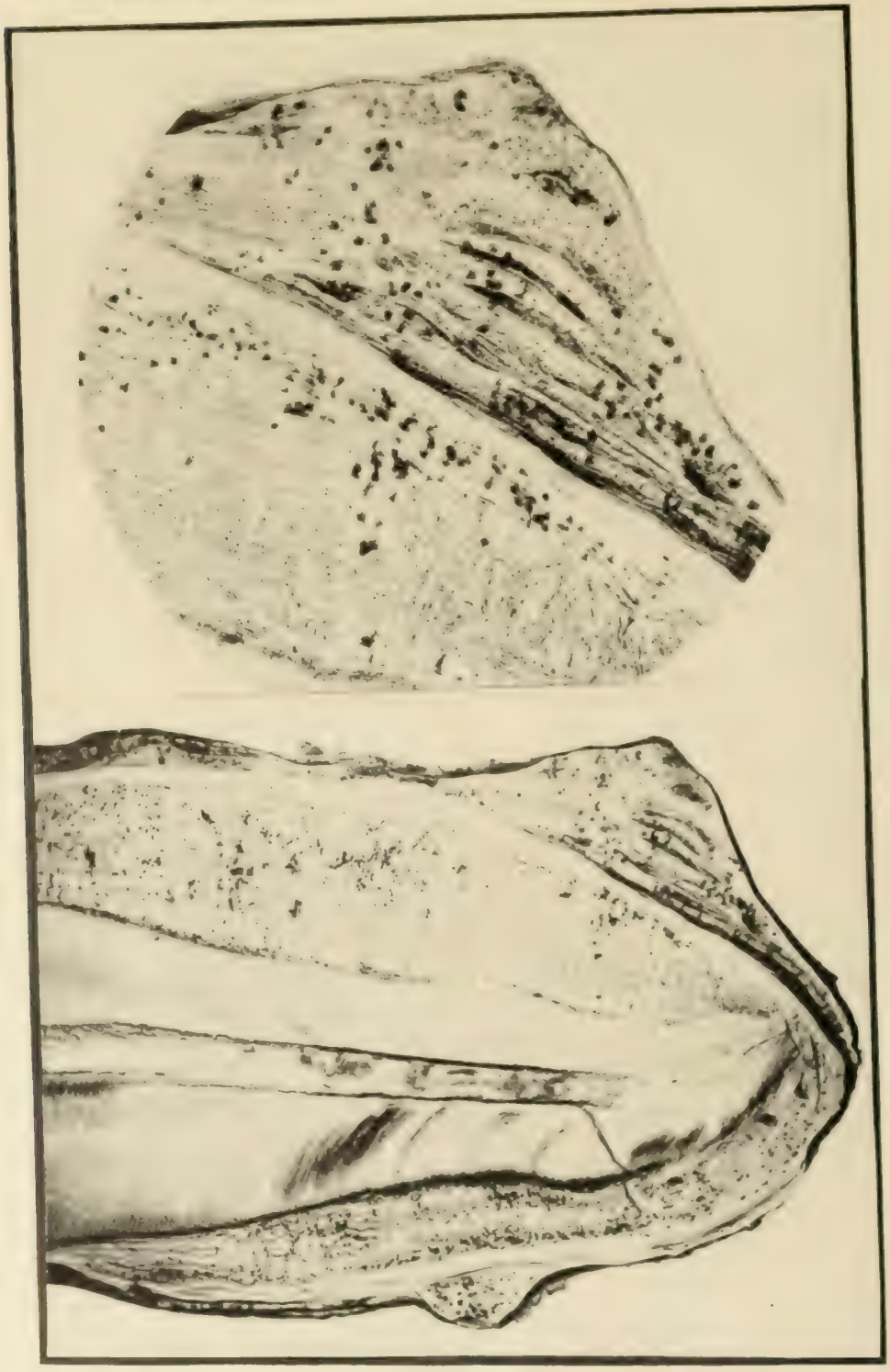

FIGURE 83. VERY EXTREME EXCEMENTOSIS OF A MOLAR ROOT. CASE NO. 1087, WITH A HISTORY OF GLAUCOMA RESULTING IN COMPLETE BLINDNESS OF ONE EYE AND ONE-FIFTH VISION IN THE OTHER. VISION PROGRESSIVELY DIMINISHING. MARKED IMPROVEMENT FOLLOWING REMOVAL OF DENTAL INFECTION.

not three per cent have developed eye involvements; whereas, in five rabbits inoculated for this patient, four, or 80 per cent, developed eye involvement. We are advised by this patient that his vision has returned practically to normal and there has been no recurrence of his trouble.

It now seems probable that many of the cases of gradual or sudden blindness have had their origin in infected teeth. As an illustration we will present the following case. Case No. 1087.—The patient, male, age fifty-six, presents with a history of glaucoma of the right eye, completely blind, and the vision of the left eye reduced to one-fifth, and progressively getting worse. The patient was not able to go on the street alone. His apprehensiveness of the approaching total blindness had made him almost a nervous wreck. His dental conditions are shown in Figure 432. A striking characteristic of the dental condition in his case was the very marked excementosis of some of the roots, particularly of the upper right molar. The ball on the apex of the mesiobuccal root created a condition that made it possible to rotate the root round and round, but it could not be removed until the buccal plate was removed. A section of this tooth is shown in Figure 435. The extensive lamination is very strikingly illustrated. Cultures taken from this and other teeth of this patient, when inoculated into rabbits, produced eye involvements in 100 per cent of cases. The most important part of this case and its history is the following: Whereas, his left eye was progressively losing its vision, it not only has ceased getting worse but it actually improved sufficiently, so that within a few weeks after the removal of his dental infections he was able to go on the street alone, and the condition has been progressively, but moderately, improving for over a year and one-half. This is an illustration of a case of an acquired susceptibility. The patient's defense should normally be high. Both sides of his ancestry were exceedingly clear of rheumatic group lesions.

I have no doubt that many types of blindness do not have their origin in dental infections, one of which is very serious. It is the blindness of ignorant dentists who have so little knowledge of focal infections that they are creating, with a confidence that is based only upon their ignorance, a great many dental conditions which some day may make blind patients. These dentists themselves may never know, and the patients may never know that the delayed development of knowledge in the dental profession is fundamentally the cause. Nevertheless, I believe confidently that

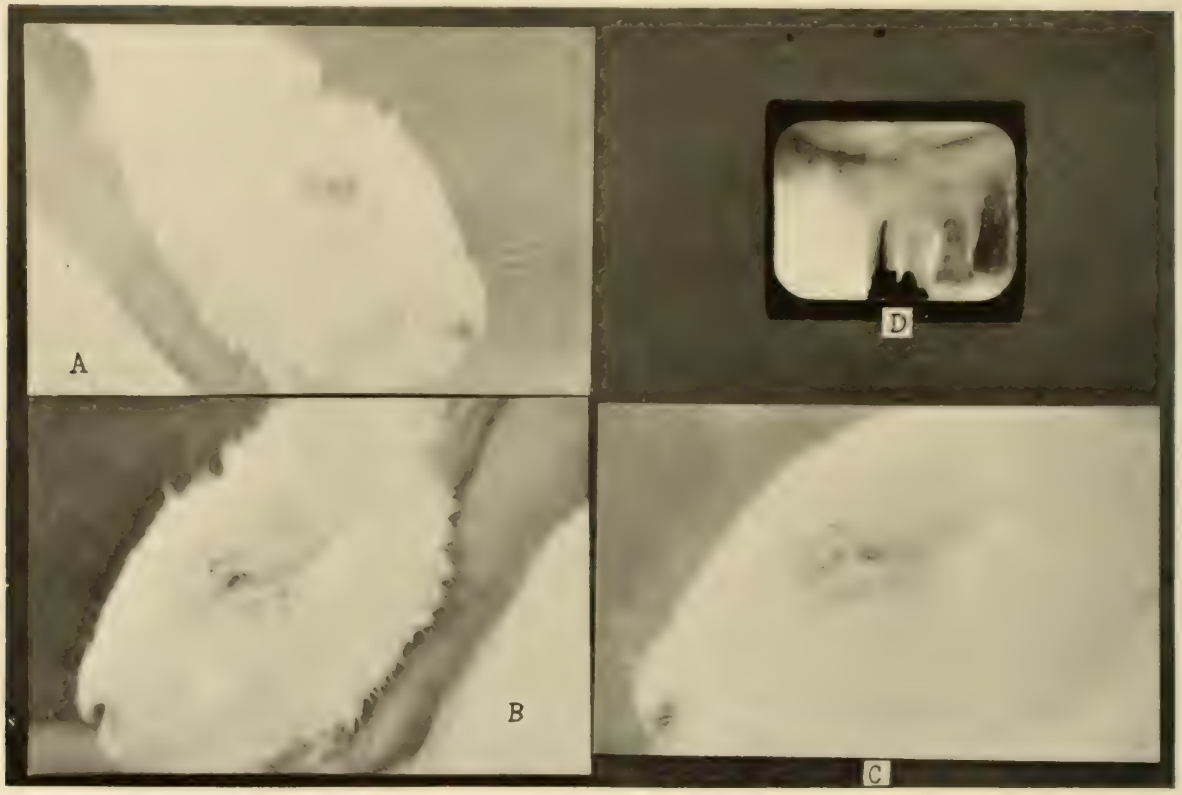

FIGURE 436. ACUTE CONJUNCTIVITIS IN RABBIT, PRODUCED BY CULTURE FROM INFECTED TOOTH IN D, FROM CASE NO. 899 WITH CHRONIC EYE IRRITATION AND HIP INVOLVEMENT.

mistaken judgments in this particular are responsible for a very large number, if not a large per cent, of certain types of optic lesions. The price that humanity pays for progress is appalling. It has always had to come that way.

Another type of eye involvement, and which is quite common, expresses itself chiefly in irritation and conjunctivitis. It usually involves both eyes and is illustrated by Case No. 899, a man, age fifty-three, who had severe arthritis which had been diagnosed as an osteomyelitis of the left hip, with a marked shortening of the right leg. This chronic eye irritation had made it impossible for him to use his eyes for reading for considerable time; and the combination of eye involvement and arthritis was aggravated by a marked sense of mental cloud or discouragement against which he had to fight continually. He had been incapacitated for work for about two years. A culture taken from the root-filled tooth shown in Figure 436-D, when inoculated into a rabbit, produced a very acute conjunctivitis with lacrimal discharge, very similar to

that suffered by the patient. The rabbit's normal eye is shown in A, and two stages of the conjunctivitis in B and C. With the removal of his dental infections and the use of a vaccine, this patient's eye trouble entirely cleared up and his rheumatism improved so much that instead of being practically helpless, he was able to return to professional practice; and a few months later, he invited me to take a walk with him, when he covered about five miles with no apparently bad effects. There has been no return of the eye trouble.

There is no doubt that several factors combine in a case of this kind. The removal of the patient's infection will in itself be important in proportion as its quantity and quality are developing definite reactions in this patient. If these reactions are in the nature of allergic sensitizations, the quantity, as shown in the chapter on sensitizations, may be exceedingly small and still produce very distressing symptoms. The use of the vaccine undoubtedly assisted him in building up a defense. The fact that he has not had a recurrence of his trouble strongly indicates that it was not a temporary benefit.

While we have had a considerable number of cases of eye involvement, I believe it will be most helpful to use as typical illustrations those in which animal inoculations have been made with the cultures grown from dental origin. In Chapter 22 on Elective Localization, we have shown that the percentage of animals developing eye lesions, where cultures were taken from teeth of patients without eye involvements, has been exceedingly low, 2 and 4/5ths per cent; whereas the animals inoculated with cultures of teeth from patients suffering from acute eye involvements, at the time, have in many instances shown 75 to 100 per cent of involvements; in the first case, 80 per cent, and in the second case, 100 per cent, notwithstanding the fact that different methods of inoculation or of bacterial growth were used as variations in the experiment. It is very striking that in patients with involvement of one eye, our rabbits have been involved only in one eye; and where the patient's involvement was in both eyes, the rabbits have in a larger percentage tended to have involvement in both eyes. The next case illustrates such a condition, one eye only being involved.

Case No. 861.—The patient, an unmarried woman forty-six years of age, was referred to me by an oculist with the statement that she was rapidly losing the vision of the left eye; that this was



FIGURE 437. EXTREME EYE INVOLVEMENT OF CASE NO. 861. B, C, AND D, DENTAL CONDITIONS. E AND F, PROGRESSIVE STAGES OF ACUTE INVOLVEMENT IN RABBIT'S EYE, INOCULATED WITH CULTURE FROM THESE TEETH.

the fifth successive attack, each one more severe than the preceding; and that this was not responding to treatment; that if we could do anything, to do it quickly. The roentgenograms of her teeth are shown in Figure 437, and show a zone of rarefaction about the bicuspid carrying one end of a bridge, with no evidence of root filling, suggesting the irritation of an entire putrescent pulp. The other foundation of the same bridge shows but slight rarefaction. Electrical and thermal tests revealed the fact that one of her lower centrals was non-vital, shown with the small metal filling in the roentgenogram. Note that this root apex shows a condensing osteitis rather than a rarefying.

Cultures were made from the contents of these teeth and all were shown to be infected in their pulp chambers. The organisms from one of them were injected into the rabbit shown in Figure 437 with the result shown. A gives the appearance of the patient's eye; F, the appearance of the rabbit's eye in forty-eight hours; and E, the appearance in seventy-two hours. Only one of the rabbit's eyes was involved. Within twenty-four hours after the extractions, the congestion and acute inflammation had markedly reduced in the patient's eye, and was nearly gone in three days. Her vision began to improve promptly and returned practically to normal; and she has had no recurrence of the trouble in three years, although she had previously had five successive attacks with progressive severity in two years.

EXOPHTHALMOS AND RETINAL HEMORRHAGE.

A large variety of dental lesions shows evidence of direct relationship with dental infections. The patient we will present as illustrating this is a married woman, age thirty-nine, Case No. 1008. She was referred by her physician because of a recurring and extremely painful lesion in her eyes, which would sometimes come on suddenly in the night with pain so severe that it would be necessary to summon her physician who would administer a hypodermic of morhpine. There was a very marked exophthalmos, as shown in Figure 438-A.

The roentgenograms of her teeth are shown in Figure 439, and it will be noted that she had evidence of extensive gingival infection, the history of which was an acute involvement that responded to treatment a few years previously, since which the teeth had been very comfortable. Bacterial examination of the gingival pockets showed evidence of a chronic low-grade inflammatory process. Knowing from experience that many of the



FIGURE 438. MARKED BULGING OF THE EYES, CASE NO. 1003, AS SEEN IN A. EYES RETURNED TO NORMAL IN A FEW WEEKS' TIME, AS SHOWN IN B.

teeth with former acute periodontoclasial involvement have degenerating or degenerated pulps, we condemned several and

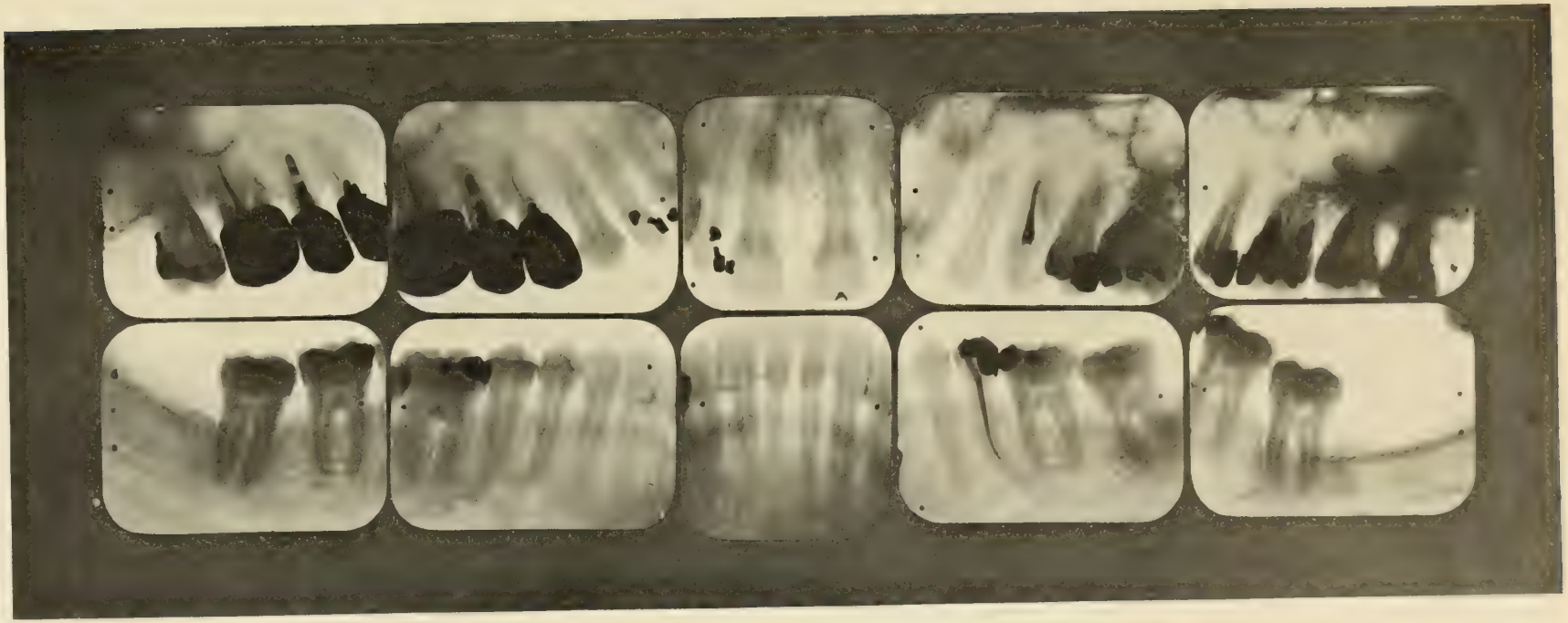

FIGURE 439. ROENTGENOGRAPHIC APPEARANCE OF TEETH OF PREVIOUS CASE, NO. 1008.

made studies of the infection in the pulps and of their structural changes. One of these is shown in Figure 440, which reveals the pulp chamber filled with a multitude of islands of calcification which was part of a slow degenerative process.



FIGURE 440. VERY MARKED PULP DEGENERATION, WITH MULTIPLE PULP STONES OF PYORRHETIC TEETH OF PREVIOUS FIGURE. CASE NO. 1008.

Cultures taken from these teeth and inoculated into rabbits produced some very striking results. Of three rabbits shown in



FIGURE 441. THREE RABBITS WHICH DEVELOPED ACUTE EXOPHTHALMOS FOLLOWING INOCULATIONS WITH DENTAL CULTURES FROM PRECEDING CASE. NO. 1008.

Figure 441, all had pronounced exophthalmos within eight days. Later, four rabbits were inoculated with cultures from other teeth of this patient, of which two showed exophthalmos. Immediately, the patient's acute eye involvements nearly ceased, with attacks so mild and infrequent that they were simply suggestions and soon ceased entirely. In a few weeks' time, her



FIGURE 442. A RUPTURED BLOOD VESSEL IN PATIENT'S EYE, SHOWN IN A, WITH HEMORRHAGE INTO SCLERA. B, A HEMORRHAGE INTO THE EYEBALL OF A RABBIT FROM CULTURE OF TOOTH. C, HEMORRHAGE INTO PERIOSTEUM AND MUSCLES.

eyes reduced in size and protrusion, completely changing her appearance, as shown in Figure 438-B. Her eyes returned nearly to normal in about six weeks. The effects of the cultures from her teeth on other structures of the rabbits were very marked. Figure 442-C shows a dissection of a rabbit illustrating excessive hemorrhages into the tissue. The periosteum and muscles were particularly involved, as shown. Figure 442-B shows a rabbit with a hemorrhage in its eyeball and greatly engorged blood vessels. In the beginning of the report of this case, we have referred to a type of excruciating pain which would come on suddenly, and usually in the night, awakening her from her sleep and requiring

a hypodermic injection of morphine for its control. These would be followed by a hemorrhagic infiltration into the choroid, and were probably related to a ruptured blood vessel. The cultures from one of her teeth, when inoculated into rabbits, frequently produced hemorrhages in several of the tissues of the eyes, one of which is shown in Figure 442-B. This rabbit also had hemorrhages in various structures of the body, including the periosteum of both hind legs and the muscles of the thigh. One of these hemorrhages is shown in the patient's eye in Figure 442-A. In Chapter 65, I discussed this case from a standpoint of the alimentary tract. In a year and one-half there has been almost no recurrence; and we have had a struggle to prevail with this patient not to have all of her teeth removed. It would be as easy to persuade her that it was imagination, that she sees the sun shining, as to persuade her that her teeth were not the cause of her involvement.

In Chapter 60, on the Circulatory System, in discussing bacteremias, I have referred to the fact that patients with a very low defense for streptococcal infection may develop a recurring streptococcal bacteremia, during the attacks of which, the organism is found in the blood stream, by culturing. One of the cases cited illustrated the large variety of symptoms which may develop in such a case. In this connection I wish to refer more specifically to the eyes of this patient. Her vision was gradually diminishing. At the time she presented, she found difficulty in crossing the street unaided. There was a definite cycle to the development of her symptoms. Her eyes would become bloodshot, as she expressed it, in which condition they were very sensitive to light; and following this, she would nearly always have attacks of acute rheumatism. In the eye lesions previously reviewed, we have noted that only one eye was affected. In her case, practically always both eyes would be affected though one might be worse than the other. The photograph of her eyes, shown in Figure 443-C, illustrates her typical expression, with the eyelids very nearly closed to shut out the light, and the part of the eye that was visible, almost blood-red. Cultures grown from the teeth shown in Figure 443-D and inoculated into the rabbit shown in Figure 443 produced very definite involvement of both eyes. A shows the eye before the rabbit was inoculated, and B the following day. This condition cleared up in the rabbit in a few days' time, when it was inoculated again with the same strain, and again developed an eye



FIGURE 443. AN ACUTE INVOLVEMENT OF BOTH EYES OF PATIENT SHOWN IN C. A, NORMAL EYE OF RABBIT. B, SAME EYE THE DAY FOLLOWING INOCULATION WITH CULTURE FROM TEETH SHOWN IN D. CASE NO. 987

involvement. The eye finally returned to normal. Cultures taken from this patient's tooth, from the blood stream, and from the eyes, were biologically the same strain of streptococcus. This strain was recovered from the patient's blood by culture three times. By the use of an autogenous vaccine, which probably did as much good to the patient as the removal of the teeth in this type of involvement, there seemed definite but temporary improvement; for if a vaccine treatment was given just as the eyes were beginning their reaction, the eye involvement was very much less severe than regularly developed and the patient largely or entirely escaped the subsequent attack of rheumatism, which quite regularly followed.

It is my belief, that this type of patient, in which group there is a considerable number, has this strain of germ growing in every possible harbor in the system; and that it tends largely to invade new harbors. For example, if a pulp should die by trauma or have its resistance lowered in this patient's mouth, it would cor-

rectly be stated that the blood stream had infected the tooth rather than that the tooth had infected the blood stream; and also, that these patients are in a state of susceptibility or lowered defense which tends readily, if not regularly, to recurrence of the more acute symptoms. These individuals are probably never free from this infection in their blood stream, and unless an accident intervene, the progressively lowering defense enables this organism finally to cause death, frequently as so-called malignant endocarditis. In Chapter 20, we have discussed some of the characteristics of these individuals from the standpoint of our serological studies; and one of the most hopeful signs of improvement in methods of increasing the defense is from the serological aspect.

In Chapter 34, we have discussed the effect on pregnancy of the introduction of streptococcal infection into the blood stream. Two pregnant rabbits were inoculated with the strain grown from the culture from this patient's tooth (and no difference was found in the characteristics of the organisms grown from the tooth, the blood stream, and the eyes, in this case). In one instance a miscarriage was produced. The immature embryos were born lifeless in about forty-eight hours. The other rabbit became very sick and died in about twenty-seven hours. The fetal forms, about half developed, already had been dead several hours and were undergoing decomposition.

Since the above was written, we have made further studies of this patient two and three years after the preceding study. She has presented because the regular symptoms have continued to recur with quite constant regularity, as quite severe exacerbations from time to time. Her vision has become progressively more defective until it is practically lost in one eye and in the other is only sufficient to enable her to distinguish forms but not to recognize individuals. Each rheumatic attack is followed by an irritation of the eye, expressing itself in pain and inflammation with congestion. We have again made a bacteriological examination of her blood and find the same organism present in both the blood stream and her eye. It is particularly of interest to note that with this mild bacteremia, the blood picture is little changed from a morphological standpoint. The biologic classification of the organisms involved is Streptococcus Non-hemolyticus I.

This is a remarkable illustration of the saprophytic quality and adaptability of this type of organism, for, from this blood study

one would not get the evidence without the bacteriological information that she was suffering from bacteremia.

Just here is another illustration that a new truth is a new sense. In Chapter 41 on the Bactericidal Properties of the Blood, I have reported researches that I have been making on the bactericidal measure of the bloods of these various individuals, in order that I may find a quantitative expression as well as cause for the condition of the low defense, by measuring the bactericidal content of the mechanisms of the blood for this strain of organism, and also to determine the capacity of the blood for its normal reaction in the process of defense. This patient's blood has proven to be so low that it would be within the poorest 5 per cent, for it neither has a normal nor near normal bactericidal quality of the blood plasma, nor the leucocytes capable of stimulation to furnish this quality to the blood when the same is stimulated by first subjecting the blood to the presence of the dead organisms. These organisms have increased their capacity for adaptability while she has far below the normal capacity for defense. This immediately indicates the point of approach for the improvement of her condition and the strengthening of her defense.

The importance of vision to comfortable life is so great that every effort that can be made to prevent blindness is, of course, imperative. We present for the encouragement of those with similar symptoms another type of progressive blindness which is of particular interest because of the very marked improvement.

Case No. 1111.—The patient, female, unmarried, age thirty-six, was afflicted with an affection of the eyes, whose chief symptom was attacks of complete blindness, at first lasting a few moments and later developing into periods of several minutes, and at the time she presented had extended to ten minutes, with so great frequency that she was afraid to go on the street, and was about to be compelled to give up her business. She was dependent upon herself for her maintenance. She reported that a careful examination by a skilled oculist had not given her any encouragement. Her eye trouble had been developing, progressively, for approximately five years. The history showed that the pathological conditions about the teeth dated back to and beyond that time. For a year the patient had not been able to do any reading, as even a little use of her eyes would bring on the attacks. She was in great apprehension of being permanently blind and with no means of support.

The condition of her teeth is shown in the roentgenograms Figure 444. With the elimination of the dental infections, her vision was so greatly improved that her periods of blindness entirely subsided and she could spend an entire evening in reading without disturbance. In over a year there has been no recurrence of the acute symptoms. She has again taken up regular office work and the whole outlook on life has changed.

This case also illustrates another in which there is an exceedingly small amount of apical reaction, notwithstanding a considerable quantity of dental infection. The lower left first bicuspid had a putrescent pulp and the tooth did not have a root filling; yet, notwithstanding this quantity of infection, there was practically no apical absorption. Similarly, the upper left first and second bicuspids with partial root fillings were infected and show, practically, no apical absorption, as also the lower right second molar and the lower left second molar.

EARS.

Probably no lesion of the organs of special sense is more common than are those of the ears, particularly in childhood; and all operators will be familiar with many cases of relief of earache by the treatment of an irritated pulp in a carious tooth. While these lesions are much less frequent in the adult, they occur and are, as in childhood, of two types: a sympathetic reflex throughout the otic ganglion and auditory nerve, and as a direct toxic irritation or bacterial elective localization of the auditory nerve. Such a case is the following:

Case No. 1162.—The patient, male, age sixty-three, presented with very acute pain in both ears, more severe in the left. He was sent to us by an ear, nose, and throat specialist who could not find local cause for the severe suffering. Three teeth, the lower left first and second bicuspids (the latter shown as a broken root) and the first molar, were extracted, all with marked condensing osteitis, the roentgenograms of which are shown in Figure 445, and the lower right second molar. With the removal of these teeth his acute pain stopped abruptly for a few days but returned with an infection of the slowly healing sockets, so characteristic of this type of pathology. With the treatment of the sockets, the ear involvement promptly disappeared and did not recur.

For the treatment of these conditions, we have found a solution of a very small amount of iodine and creosote, equal parts in

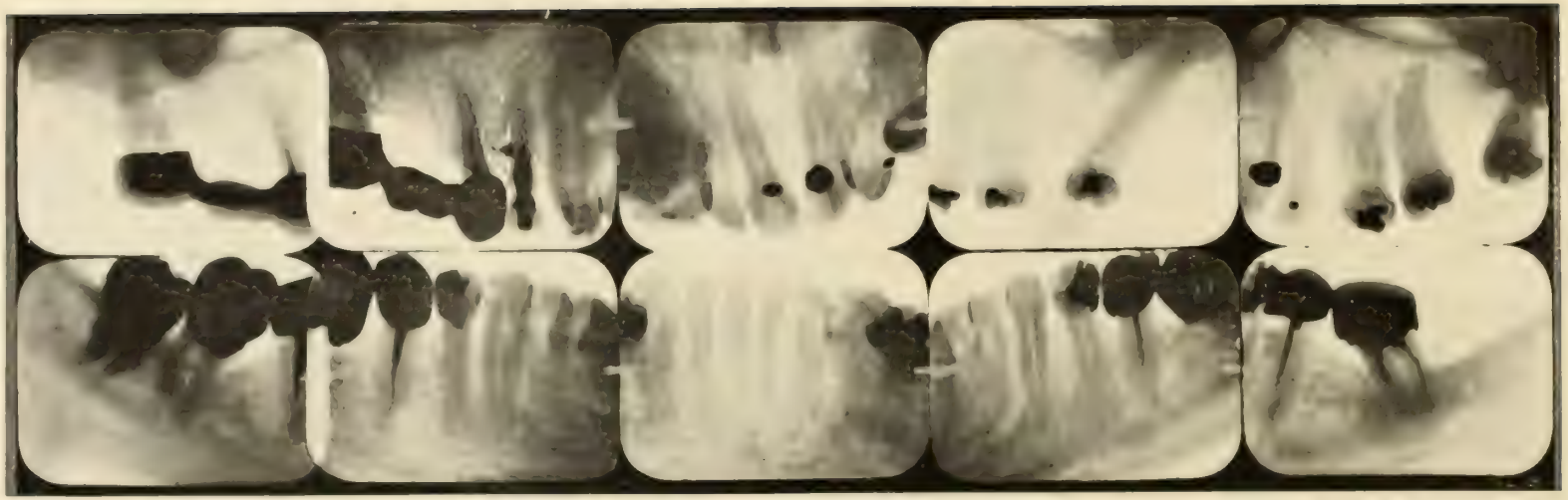

FIGURE 444. DENTAL CONDITION OF CASE NO. 1111, WITH ATTACKS OF TEMPORARY COMPLETE BLINDNESS. NO RETURN OF ATTACKS AT LAST REPORT, TWO YEARS AFTER REMOVAL OF DENTAL INFECTIONS.

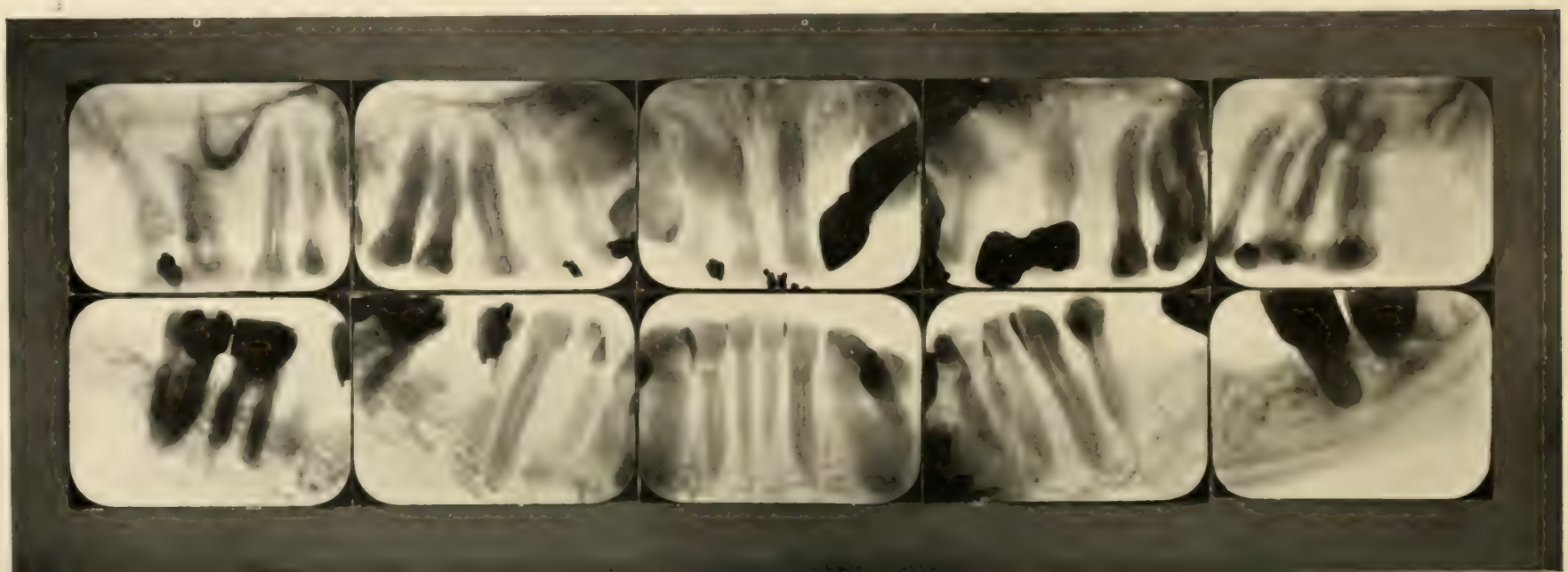

eugenol, to be very effective. This may be prepared by adding the mixture of equal parts of iodine and creosote, one part to eugenol, thirty parts. It is neither necessary nor desirable to have the creosote in greater strength than this. An equally good way to prepare the dressing is to dip a piece of surgical gauze, one-half inch square, into the saturated solution of equal parts of iodine and creosote and then carefully wipe off all that can be removed by absorbent cotton, and moistening this gauze with eugenol. The strong iodine and cresote solution is too escharotic and destroys the granulations. This dressing works like magic in controlling the after-pain of so-called dry sockets, which are primarily due to the poor vascularization of the alveolus, as a result of condensing osteitis, characteristic of tissue with low defense, and found in patients with marked susceptibility to streptococcal infection, the local characteristic of which is the absence of normal reaction, of which the chief expressions are pain and rarefying osteitis, connective tissue proliferation, etc.

OBSCURE NEURALGIA.

The members of the laity seem generally to look upon neuralgias as being pains without a physical cause, or at least not due to a localized degenerative process. The reason for this is probably largely due to the use of the term by the medical and dental professions to include those forms of neuritis for which the cause was not known. It is probably true that all disfunction as well as malfunction has its counterpart and cause in abnormal structural and therefore physical conditions of tissue, for chemical processes are ultimately physical. Probably few single groups of disturbances so frequently have their actual causes overlooked as do the so-called neuralgias of the head and face. This condition is still further complicated by the fact, that the nerve structures involved are very often within dense walls and are very difficult to examine except by indirect methods. An acute pulpitis will usually present very little difficulty in location because of the exalted reactivity of the pulpal tissue to temperature changes. A degenerative process, however, may develop within a pulp without considerable change and certainly without an exaltation of its thermal reactivity. Many of these processes have their origin in other structures than the teeth and it must not be presumed that the teeth furnish the only source for these obscure disturbances. They do, however,

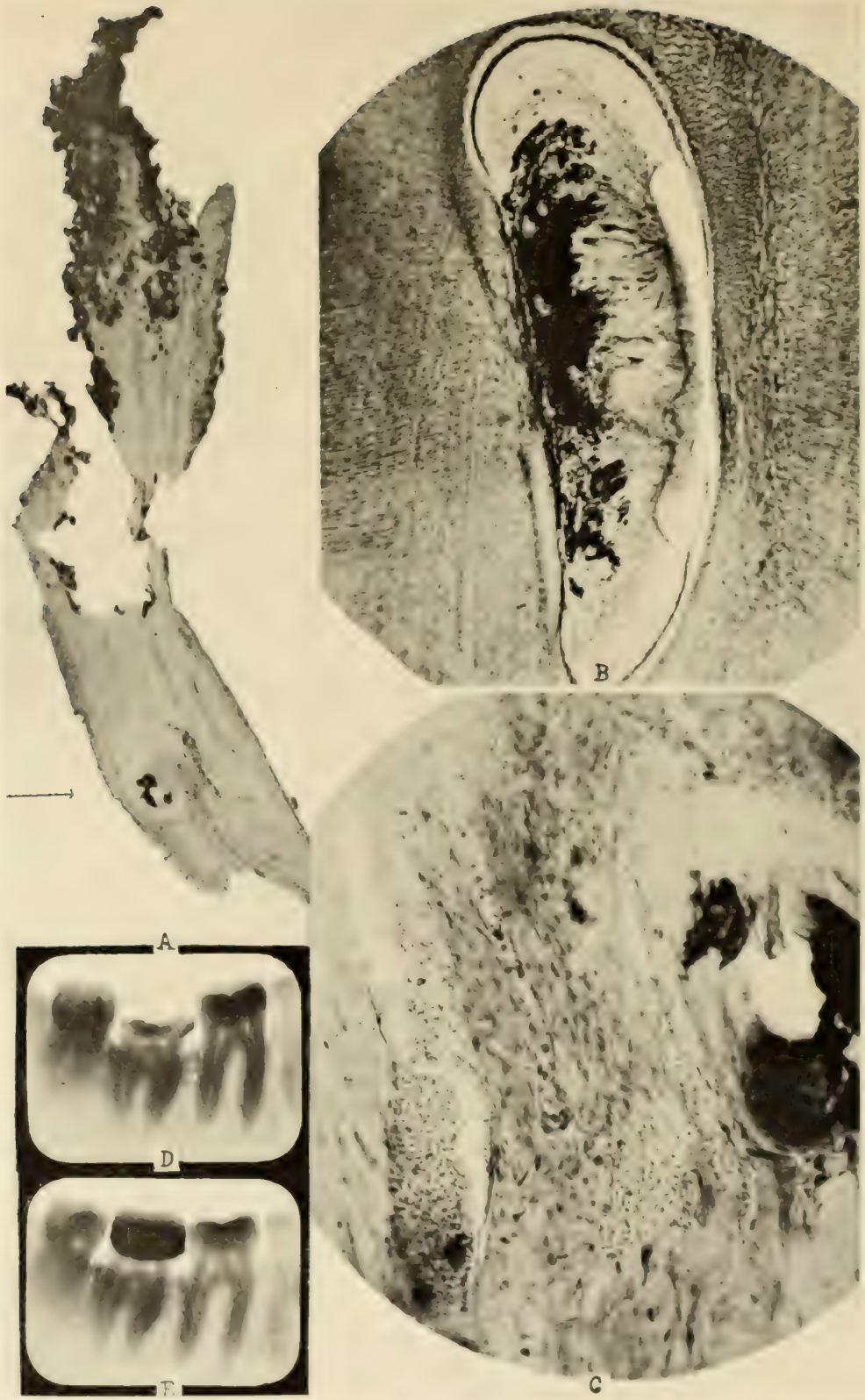

FIGURE 346. OBSCURE NEURALGIA OF DENTAL ORIGIN: E, CROWNED VITAL TOOTH. D, WITHOUT CROWN. A, DEGENERATING PULP WITH CALCIFICATIONS. B, CROSS SECTION OF DEGENERATING PULP WITH CALCIFICATIONS. C, HIGH POWER SHOWING HYPEREMIA AND DILATION OF VESSELS WITH CALCIFICATION.

furnish very many of them and probably more than any other group of tissues. I have undertaken to study the pathology of a number of these processes. A typical one will be seen in Figure 446. The history was about as follows:

The patient suffered from an obscure pain in the side of her head, left side of the face, and neck. This began about a year previous to our seeing her and was most severe in the temple and the ear. At times the neck stiffened on the left side. There were occasions when the disturbance definitely affected her thinking. It was progressively getting worse. It began intermittently and became constant. It was temporarily relieved by the extensive use of Balm analgesic rubbed over the entire side of the face, neck, and head. It had become so severe as nearly to incapacitate the sufferer. All her teeth were roentgenographed, and by that means were negative. All tested normally to temperature change. Naturally, the left mandibular second molar, carrying a gold crown, was suspected, notwithstanding the negative appearance of the roentgenogram. The history of this tooth revealed that there had not been the slightest abnormal symptom during the year that the patient had been suffering. Since it was difficult to test the tooth with the crown in position, a burr was used to drill the dentin at the cervical margin and the dentin responded normally. The crown was removed and contained a large quantity of cement, into which cement bacterial infection practically always extends. There was no recent caries of the dentin. The crown had been set without removing completely the carious dentin. The dentin was tested in several places after the removal of the crown and found to respond quite normally to the irritation of cutting with the burr. The tooth was put under observation, the patient dismissed, with the result that the distressing pain was practically relieved from the time the crown was removed, and did not recur.

In Chapter 17 of Volume One, on Tooth Capacity, I have discussed the role of the toxins and their ability to pass through the dentin and somewhat of their effects. The bacterial growth in cement under a gold crown is very often purely streptococcal, and this organism is practically always present. When the organisms were growing within this gold crown they produced their toxic substances which could not escape through the gold but could through the dentin of the tooth and, of course, to some extent about the margins. These toxic substances tend to pro-

duce in susceptible individuals relatively violent reactions in proportion to the quantity. The result in this case was not only an intermittent involvement of other tissues but it was a direct degenerative process set up in the pulp tissue. This pulp degeneration can be seen in A, B, and C, in Figure 446. B shows a cross section of the mesial root and it will be noted there are extensive zones of calcification. A is a longitudinal section of the pulp of the distal root and also shows very extensive calcifications. C shows a cross section of the pulp under high power and shows a very marked hyperemia, extensive fibrosis, and calcifications. The development of these degenerative processes within the pulp were no doubt contributing to the reflected disturbances. However, there was no evidence of pulpal necrosis as a part of pulpal suppuration. Its normal reactions to mechanical and thermal irritants indicated that it was not a suppurative process. Several things are important in this connection. One is that the original roentgenogram, as seen in E, reveals what would be considered a normal pulp in that there is no periapical involvement and the pulp chamber does not give suggestions of calcification processes, it being much more clear than the pulps of the first and third molars.

The questions will arise: Why did we extract the tooth? Why not remove its pulp and fill the roots? My answer is this: The fact that this patient had at one time developed so severe a reaction in the nerves of her face and head would make them always more susceptible to irritations. Second, the possibility of mechanically filling with perfection the mesial roots of lower molars is always problematical. Third, it would be impossible that the tooth could be put in a thoroughly sterile condition or that it could be maintained in as sterile condition as it would be left when the root filling was placed. Fourth, it would be very probable that in later years, if not months, this tooth would contain within the dentinal tubuli definite streptococcal infection. Fifth, when and if this condition developed, a toxin similar in effect to that which was generated in the cement of the gold crown would be available and would irritate more or less severely the approximating nervous tissues. The fact that this patient had developed this type of disturbance would strongly suggest that she would do so again. While it is true there would be no pulp available to respond to irritation, the pulp is not the only tissue that can so react. For those whose practice it is to place

gold crowns, I would urge the keeping in mind the impossibility of keeping the cement which attaches the crown from becoming infected, the extreme porosity of the dentin, which pores all lead directly to the pulp, and the capacity for the pulp as an end organ to produce profound disturbances through its sensory enervation in the various nerve structures directly and indirectly connected with it.

CHAPTER LXVII.

SKIN.

DISCUSSION.

In discussing the lesions of the skin that are related directly to dental infections, we are probably dealing very largely with anaphylactic reactions to bacterial antigens developed in the dental focal infections and to which that patient has become sensitized. Their variety is so great and the illustrations of success and failure so striking that it is, as yet, very difficult to interpret either the mechanisms involved or the means for determining, in advance, with certainty, whether an obscure dental infection is or is not a causative factor. We have discussed this problem in Chapter 30 on anaphylaxis, and I will not review at this time my interpretation of the principal factors involved. Some of the skin disturbances with dental connections are, apparently, true bacterial invasions with or without a preliminary irritation and sensitization of the tissue by the toxins involved.

The first case I will present is one of herpes, which is probably true bacterial invasion. This patient, a married woman of thirty-one years, had been suffering for about five years from severe nervous affection, expressing itself in indigestion and in skin irritations, typical herpes with a history of herpes zoster, with raised areas as large as a quarter which persisted for many weeks and were very painful. Her affection was so distressing and persisted so long that she confided to me that had it not been for her young family who needed her greatly, she felt she would have given up the struggle, that she felt there was nothing for which to live. Case No. 841.

Her dental conditions are shown in Figure 447. With the removal of the dental infections her improvement was very marked and complete. She has gained in weight from about 125 to 155 pounds, and for three years has not had a recurrence of her herpes until a slight one very recently. It seems very probable that this woman's dental infections either furnished an antigen to which she was very acutely sensitized, or (which seems more probable) that they furnished a toxic substance or

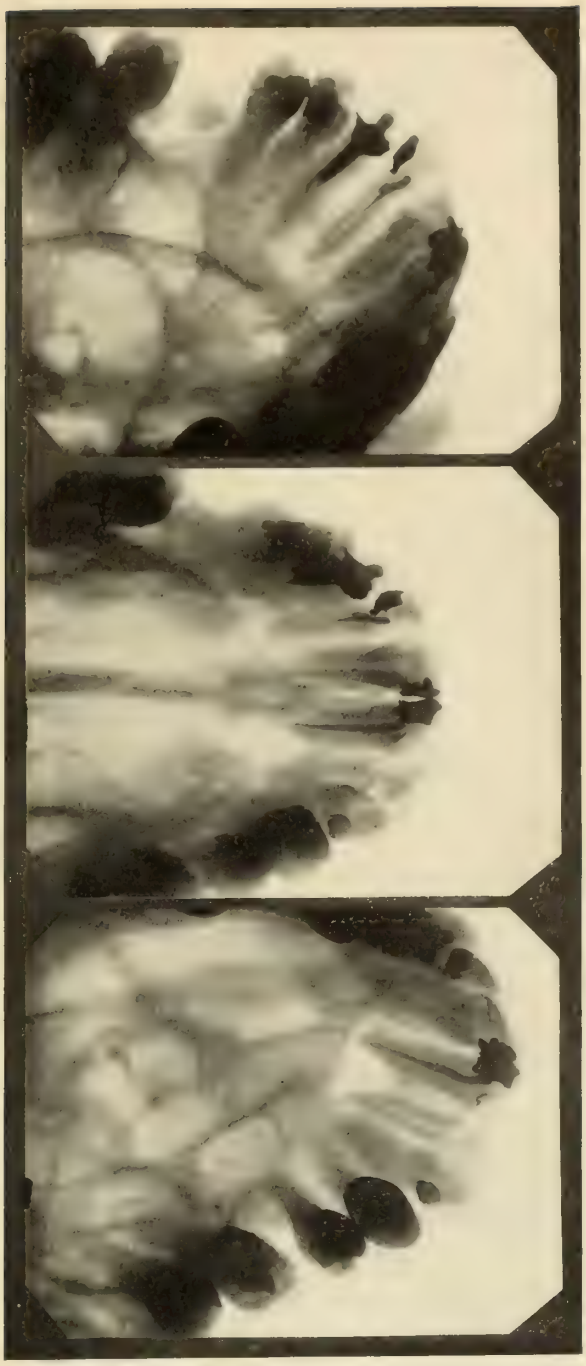

FIGURE 447. RADIOGRAPHIC APPEARANCE OF DENTAL LESIONS RELATED TO AN ACUTE HERPES ZOSTER, WHICH PROMPTLY DISAPPEARED AFTER THEIR REMOVAL. CASE NO. 841.

bacteria which had a specific affinity for certain nerve tissues, particularly peripheral nerve endings.

We more frequently see skin irritations of dental origin in the form of very acute irritation without so much physical expression in the tissues. Sometimes there is an itching like the irritation of nettles without change in the skin. Such a case is the following: Her entire body was itching so painfully that she could not refrain from scratching herself, which, of course, aggravated the



FIGURE 448. UPPER LATERAL WHICH, WHEN REMOVED, COMPLETELY RELIEVED A DISTRESSING ITCHING IRRITATION OF THE SKIN. CASE NO. 1114.

trouble; and, yet, there was very little evidence, physically, of the irritation. She found great difficulty in refraining from breaking the skin with her scratching. Case No. 1114.

An upper lateral tooth, shown in Figure 448, had a history of having recently been acutely inflammed with symptoms of periapical abscess, which symptoms had subsided. The tooth was opened for study; the pulp was found putrescent; the tooth was dressed; and that night she had by far the most severe symptoms of this skin irritation that she had ever had. Its history showed that it had a periodic cycle, which would disappear entirely and return; but the periods of exacerbation were continually getting more severe. This tooth was extracted. This skin irritation disappeared immediately and has not recurred in two years' time. This case should also be considered as probably an illustration of sensitization; and it is very difficult to anticipate how far it will be demonstrated that these sensitizations have contributed to the development of pathological lesions.

It is not uncommon for us to see the dermatosis, expressing

itself as warts about the arthritic joints, entirely disappear with the removal of dental infections; and it is now quite completely demonstrated that these proliferations of the epithelium are often entirely due to infection processes. It is not yet demonstrated to what extent those proliferative skin irritations, which approach malignancy in their type, may be influenced, if not originally induced, by some form of allergy. We would present in this connection for consideration and not as an illustration of a demonstrated fact, the following case.

Case No. 1205.—This woman, age fifty-two, presented with the so-called skin cancer of the nose. These neoplasms tend to have exacerbations with a definite trend toward malignancy. That this lesion may be in part an expression of an allergy is the only point we are presuming to illustrate. I have made an extended discussion of the researches on this phase in Chapter 31. She had very extensive dental infections, as shown in Figure 179, Chapter 31. With the removal of these, this skin lesion, which had been in an aggravated condition for several months, completely disappeared, as shown in the pictures which were taken three weeks apart (Figure 178, Chapter 31). This lesion had tended to have exacerbations but never before had completely disappeared, and tended to have its aggravated stage recur in a few weeks' time. In this instance it was absent, approximately, five months before its return in mild form. I transferred her to a cancer specialist to whom I had referred her at first presentation; and because the lesion promptly disappeared after the removal of her dental infections, she returned the letter of introduction. He gave the lesion a treatment with radium, which is very effective for this type of lesion, and in several months there has been no recurrence.

Since the evidence presented in the experimental chapters strongly suggests that many of the skin diseases are allergic reactions to protein sensitizations of bacterial origin and other forms within the body, many cases would naturally be reported under skin lesions which under a strict classification have been presented in the chapter reviewing researches on sensitization reactions. We would refer to Chapter 30 for the further review of the clinical symptoms and their interpretation in relation to sensitization.

Skin lesions about the face and neck may readily be the result of a systemic expression of a focal infection or may be the external localization of a dental infection probably with direct fistulous

connection with the dental focus. An illustration of the former will be that of the girl of twenty-three illustrated in Chapter 59, who, in addition to her acute rheumatism and heart involvement suffered from pustules over her face, in many respects like acne. With the removal of her dental infection, not only her rheumatism and heart involvement immediately subsided, but this skin lesion also.

There are many lesions, however, of the skin, which seem very directly to be connected with dental infections and which are of the nature of a sensitization. In Chapter 30 on Sensitizations, I presented a number of these. I would, accordingly, stress in this connection the type of condition that may be associated or at least may be under suspicion as of dental origin. Figure 172, Chapter 30, shows a type of scaly dermatitis which is associated with so marked a stiffness of the hand and fingers that the individual, a professional pianist, was prevented from maintaining his regular duty. There was a marked tendency to deep cracking. With the removal of the dental infection, shown in Figure 173, this disturbance of six months entirely disappeared, and in seven months more has not returned.

Another type is a dry scaly dermatosis not tending to crack deeply, but at times quite strikingly sensitive. It was illustrated in Figure 175, Chapter 30. It was present on different parts of the individual's body, but chiefly on both arms. With removal of the dental infections, as shown, the process entirely disappeared. Figure 175 shows this individual's sharp dermal sensitization reaction and also the condition of the arm a few days after the removal of the dental infections, at which time there was no visible indication of where the disturbance had been though it had persisted for months previously.

CHAPTER LXVIII.

ENDOCRINE SYSTEM.

INTRODUCTION.

A discussion of the lesions of the endocrin system will, of necessity, involve a reference to much that has already been presented in other chapters, since a great deal that has been presented in the chapter on Primary and Secondary Sex Organs involves the gonads. To save repetition, we will, accordingly, refer to that chapter, No. 62, for a further discussion of this.

GOITER.

DISCUSSION.

Attention has frequently been called in literature to the fact that dental infections very readily tend to disturb the functioning of the thyroid gland. McCarrison in his splendid work in India found that he could produce the typical goiter of that district, in which he was working, by having the men drink the residue from the filtered water of the water supply of the communities where this disturbance was so predominant. He also demonstrated that the disturbance was more prevalent the farther down stream the villages were located, indicating that the increase in the sewage was an important contributing factor.

Early in our studies, I observed that girls, who were suffering severely from enlarged and over-active thyroids, had these aggravated by the development of dental infections and relieved by the elimination of the dental infections. A typical illustration is as follows:

Case No. 628.—The patient, at the age of twenty, had a thyroid which had enlarged her neck to 36 centimeters. She had a typical group of symptoms: nervousness, rapid heart, excitability, and fear. The condition of her mouth is shown in Figure 449. With the removal of these dental infections the circumference of her neck reduced to 33.5 centimeters; her nervous symptoms entirely disappeared and her heart returned to normal.

This case is of interest because two years later a tooth which I considered to be border-line and had under study because it had had an apicoectomy made upon it, developed slight tenderness



FIGURE 449. DENTAL CONDITION RELATED TO A CASE OF HYPERTHYROIDISM IN A YOUNG WOMAN, AGED TWENTY. CONDITIONS RETURNED RAPIDLY TO NORMAL FOLLOWING THEIR REMOVAL. CASE 628.

though roentgenographically the evidence was not considerable. It was kept under study for a few weeks. Her former symptoms of thyroid irritation developed with a very marked tachycardia. The tooth was removed and her symptoms promptly and completely disappeared.

While a very large number of young girls have thyroid disturbance, usually with enlargement, throughout all those geographical locations that do not have either a soil or water supply from the soil bearing shells of salt water fossils or a supply of iodin directly from sea water, those cases are not so distressing as the acute disturbances of middle life and beyond, which so often seriously involve the heart. Such a case is the following:

Case No. 471.—A woman, age forty-two, with three children, was suffering distressingly from nervous symptoms, exophthalmos, and very severe heart disturbance. She was not able to take care of any of the interests of her home and seemed on the verge of a very critical collapse. For the preceding year she had had a skin eruption and for a few weeks had a very distressing cough, due to the pressure of her goiter. She had marked tachycardia and a murmur had developed some months previous to the time she presented. Her condition was considered too critical for operation.

The type of dental pathology is shown in Figure 450. The upper right central had a history of having abscessed five years previously, at which time it was treated daily for several weeks, tenderness lasting for some time following its root filling. An upper right molar which had abscessed, had had a root amputated about a year previously. At the time of presentation no teeth were giving symptoms of trouble.



FIGURE 450. ROENTGENOGRAPHIC APPEARANCE OF DENTAL CONDITIONS OF VERY SEVERE CASE OF EXOPHTHALMIC GOITER WITH HEART INVOLVEMENT. PATIENT VERY RAPIDLY RECOVERED AFTER REMOVAL OF THE DENTAL INFECTIONS. CASE 471.

After the elimination of the dental infections her improvement was very marked and rapid. Her goiter reduced in size; the exophthalmos disappeared; and her heart so splendidly improved that in a few months' time she was doing her own housework, entertaining extensively, and for over three years has been carrying both her household and social duties with apparent ease. As an illustration of her improved heart condition, she does not mind a long walk uphill, even when taken rapidly, notwithstanding she is a very large, stout woman.

A study of her susceptibility chart shows, as shown in Figure 451, the following: Her disturbances have been chiefly heart, goiter, and nervous breakdown. Her severest symptoms have developed recently, though she has a history of neuritis and nervousness earlier. She had four brothers and four sisters. Two of her sisters and one brother have had rheumatism. All of her four sisters have had nervous breakdown and her mother suffered nervous breakdown three times. One sister is also recorded as having a goiter. Both her father and mother have had rheumatism. However, the chief disturbances have been in the nervous system and heart. Her father, three of his four brothers, one of

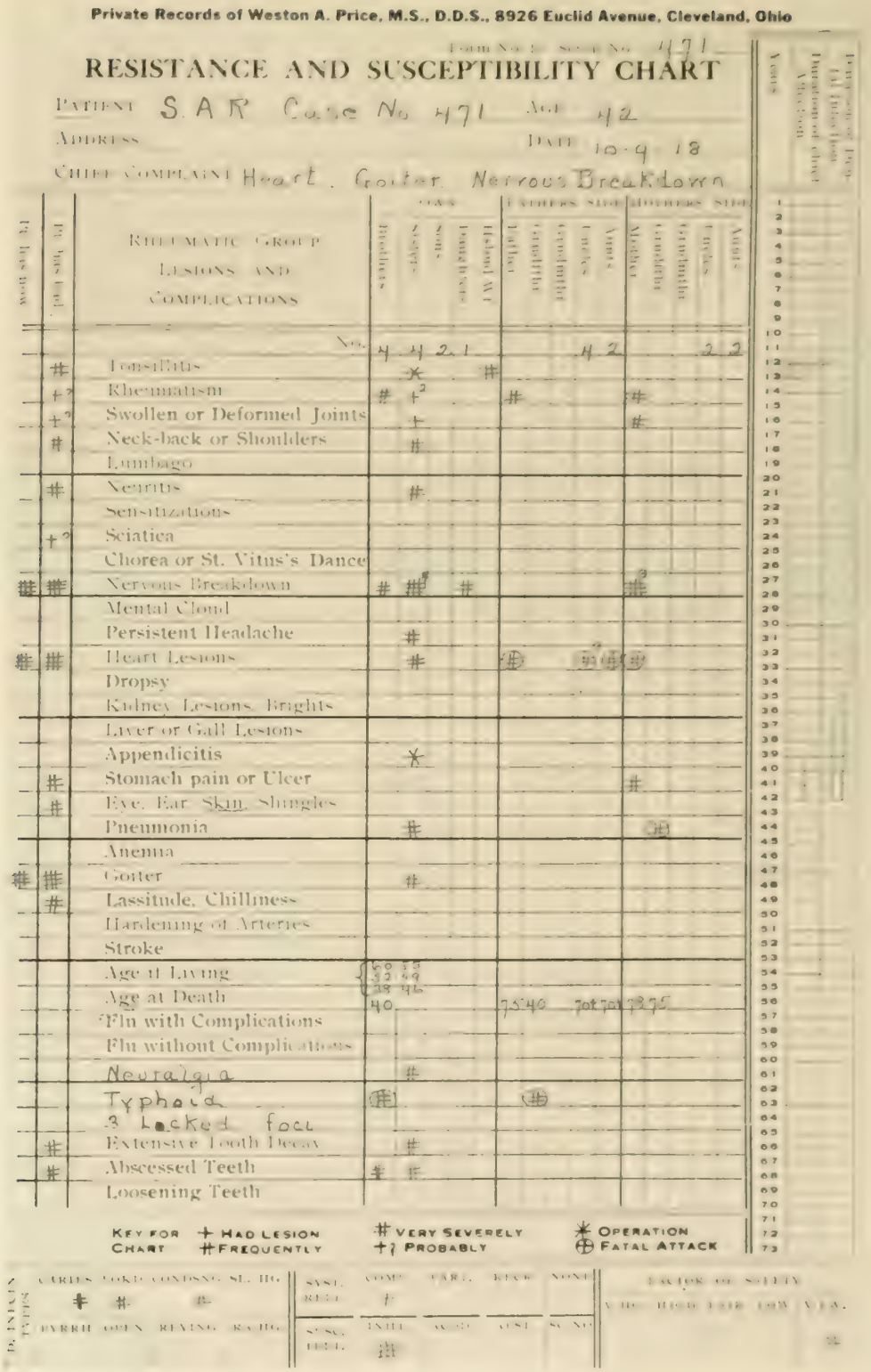

FIGURE 451. SUSCEPTIBILITY RECORD OF CASE NO. 471, WITH HEART AND GOITER INVOLVEMENT AND NERVOUS BREAKDOWN. NOTE MARKED HEREDITARY SUSCEPTIBILITY FOR NERVOUS SYSTEM AND HEART, WITH SIX DEATHS FROM THE LATTER.

his two sisters, and her mother, all suffered from heart trouble during life, and their deaths were recorded as being due to heart trouble. The fact that these people did not die young, but in after years, would indicate that their heart trouble was one of irritation rather than a severe organic lesion. It is very difficult to get definite information, as to whether the disturbance, that will have been recorded as rheumatism in a member of the family, is an involvement of the nervous system as neuritis, or of a myositis, synovitis, etc., of the skeletal and muscular system.

In studying this woman's factor of safety, we should expect it to be low in both the nervous system and heart, which, doubtless, was a contributing factor to the extreme expressions in those tissues of either the direct irritation of the toxic and bacterial products of the dental focal infections, or the indirect effect of their reaction upon the thyroid gland and the general endocrine system. Whatever the mechanism may have been, the extreme reactions are strongly suggestive of a very marked sensitization and the fact that she recovered so completely and quickly without operation illustrates the necessity for careful study to determine whether the disturbance of the tissue to be operated upon is not a symptom of the focal infection rather than an independent lesion.

I have no doubt that many, who will look at the roentgenograms of this woman's teeth, will shrug their shoulders and say or think there is little or no roentgenographic evidence that these teeth are infected. To these I wish to say that that fact of absence of evidence of reaction is one of the saddest I know of in connection with all humanity's interests and afflictions, for if this woman had an adequate capacity for reaction she would be establishing about these seriously infected teeth (for they were proven to be infected by culture and animal inoculation) a quarantine against the dental infection which would prevent either it or its toxins from reaching the balance of her system. Incidentally, such an adequate reaction would produce destruction of bone which would be replaced by highly vascularized granulomatous tissue and which, of necessity, would readily be recorded in the roentgenogram. It is the absence of this reacting capacity that is this woman's undoing. As I have shown in other chapters, the most important factor is the capacity for reaction of the patient, and an understanding of its expressions.

In our animal inoculations it is not unusual to find very marked involvement of the endocrine system. Such a case is the following:



FIGURE 452. AN ENORMOUSLY HYPERTROPHIED THYMUS WHICH DEVELOPED IN A RABBIT INOCULATED WITH A DENTAL CULTURE.

Rabbit 156, shown in Figure 452, was inoculated with the culture from a patient with streptococcal blood stream infection with multiple symptoms, including rheumatism, eyes, heart, nervous system, and skin. This figure illustrates a greatly enlarged thymus as the result of this inoculation. We do not interpret this to indicate or even suggest that this patient had a thymus involvement. We do not know; but present the case only as illustrating this extreme effect upon this rabbit, a lesion which has seldom occurred to so great an extent. To what extent this patient's symptoms of endocrine derangement were the result of thymus irritation we cannot even guess.

PANCREAS.

In the chapter on Chemical Changes in the Blood, I have discussed some of our studies on the relation of dental infections to pancreas function and carbohydrate metabolism, and have shown that dental infections tend distinctly to increase the sugar retention in the blood in experimental animals in certain instances.

Since carbohydrate metabolism is so closely related to, and dependent upon, the functioning of the islets of Langerhans of the pancreas, it seems very probable that any process, which may disturb the normal functioning of that tissue, will in turn disturb both carbohydrate metabolism and acid-base balance. The processes that are involved in these disfunctions, while not clearly understood, have been greatly elucidated, as shown in Chapter 20, by the researches of Banting[5], Best, Collip, Hepburn, and Macleod.

It is, of course, impossible for us to present evidence to establish definitely that the dental infections *per se* have been responsible for the disturbance in carbohydrate metabolism by producing a lesion in the pancreas of the patient. We can, however, be justified in making some observations which will relate the patient's clinical condition to carbohydrate metabolism. This has expressed itself with a marked diminution of a hyperglycemia, coincident with a reduction of the glycosuria, which has occurred in a number of instances. In Figures 192 and 193 there will be seen two specimens of pancreas tissue; 192 is taken from a normal rabbit and 193 from a rabbit inoculated with a strain taken from a dental infection. It will be noted that there has been a distinct change produced in the islets of Langerhans in these two tissues. Of course, it is not possible to take a section of a pancreas from a rabbit and then inoculate it and later take some of the same tissue. We are presuming that the rabbit selected as normal had a normal pancreas, which was evidenced by the fact, that in a large number of sugar determinations of normal rabbits we have never found any divergent from the normal though we have frequently found this factor distinctly disturbed by the inoculation, as cited in Chapter 20. It is my belief that further research on this important problem will disclose further evidence of this relationship.

[5] See bibliography.

CHAPTER LXIX.

OTHER TISSUES.

DISCUSSION.

Under the head of other tissues we will discuss a variety of tissues not included in the foregoing subdivisions, first of which will be the salivary glands. The involvements of the parotids, as parotitis or mumps, is familiar to all as an acute infection of relatively short duration and, except for the complications, is not frequently sericus. Acute parotitis has frequently been produced by dental infections and the organism found in mumps has been classified as a strain of streptococcus. This, however, is not the type of lesion that is of greatest concern; not because it is not severe, but because it is not frequently serious, and its duration is relatively short.

XEROSTOMIA.

This disease has been considered relatively rare and its etiology has been unknown. It is fortunate it is rare because its fatality is so very high. There are only a few dozen cases of the disease in the medical and dental literature, and, so far as we know, practically all have proved fatal.

Its cause has been supposed to be in the central nervous system. The symptoms are a lack or absence of the normal secretions and dryness of the mouth, increasing in severity until the tissues crack, suppuration sets in, and the patient dies a most agonizing death. The first case we will study is as follows:

Case No. 955.—A woman, age fifty-seven. Her history showed that she had rheumatism which began acutely fifteen years previously. At the time of presentation her joints were swollen and her hands could not be closed. She had had acute indigestion which produced fainting, on two occasions. A heart lesion had developed thirty years ago with la grippe. Her dry mouth began eight years previous to my examination. At this time it was parched so that it was like feeling a piece of dry tissue paper. The tongue and the inner surface of the cheeks cracked readily. There was complete absence of both mucous and salivary secretions. Owing to the fact that we could find no reference to the

development of the pathology or its etiology, I removed a part of the right sublingual gland for histological study and also some mucous membrane from the cheek for similar study.

A characteristic of these cases is the persistent and rapid caries, the crowns just melting from the roots, requiring almost weekly care; and in this patient's case it had only been because of the exceeding faithfulness of her dentist that any teeth were left. It is necessary for these patients to take water into their mouths very frequently in order to moisten the tissues. As the disease develops, the dryness extends to the throat and eyes, the latter as xerophthalmia.

By manipulation of the parotid glands and compression of the cheeks, it was possible to cause to exude from the Steno's duct a small quantity of a gelatin-like mass which was so dry that it would not moisten a cover-glass or mirror. Culturing of this mass always produced streptococci, growing chiefly in diploid form. Owing to the dryness of her mouth, it was very difficult to get roentgenograms, since the dry tissue tended readily to be lacerated and healed slowly from laceration.

On sectioning the tissue taken from the sublingual gland, very definite structural changes were found, as shown in Figure 453. A shows a normal lobe and lobule, and B one as found in her tissue. Note the degenerative necrosis of the lobe, with its infiltration of leucocytes, degeneration of the excreting cells, necrosis and fibrosis with a tendency to proliferation so pronounced as to be even suggestive of malignancy. A high power view of this tissue is shown in Figure 454, and of lobules of other cases in 455.

The roentgenographic studies of her teeth are shown in Figure 456. It will be observed that the lower left first molar gives evidence of a curved, if not a deformed root, which condition had presented great difficulties to the operator who undertook to fill it. This tooth was extracted, at which time it was found that the mesial root was bifurcated, as shown in Figure 456. This is a very unusual condition and is not disclosed in the roentgenogram. One branch of this bifurcated root did not have a root filling. The tooth, due to the mechanical difficulties, had not permitted the root filling to be placed to the end.

The history of this and similar cases had been that the use of sialogogues was not beneficial. The placing of the whip on these exhausted tissues was always followed by the making of the conditions more aggravated than before. This had been tried many

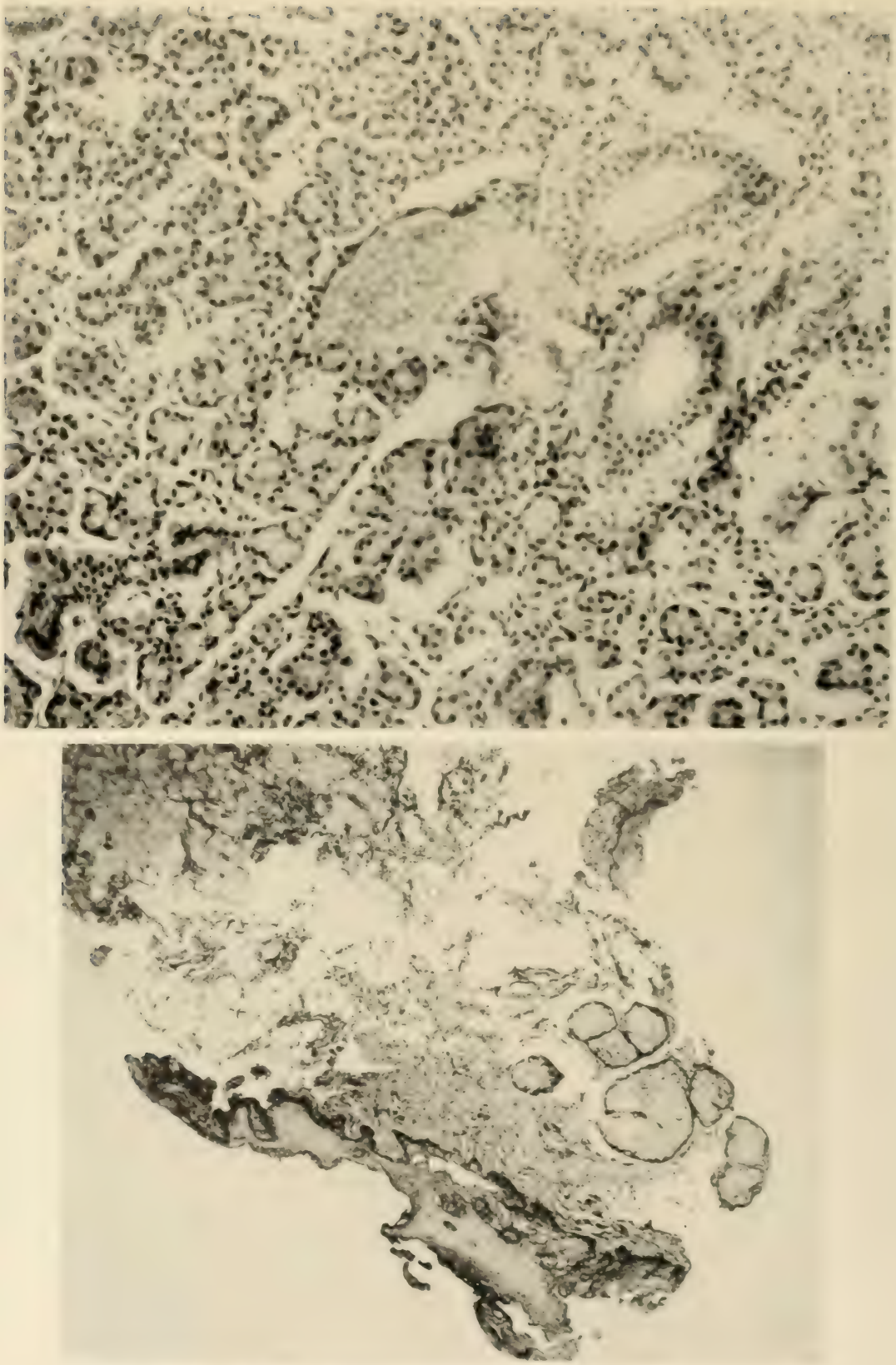

FIGURE 453. UPPER, NORMAL SUBLINGUAL GLAND SHOWING LOBE AND DUCT AND NUMEROUS NORMALLY FUNCTIONING LOBULES OR ACINI; LOWER, PATHOLOGICAL SUBLINGUAL GLAND OF CASE NO. 955, SHOWING DEGENERATED LOBE. THE LOBULES, OR ACINI, ARE NEARLY ALL DESTROYED, A FEW INTACT BUT BREAKING DOWN.

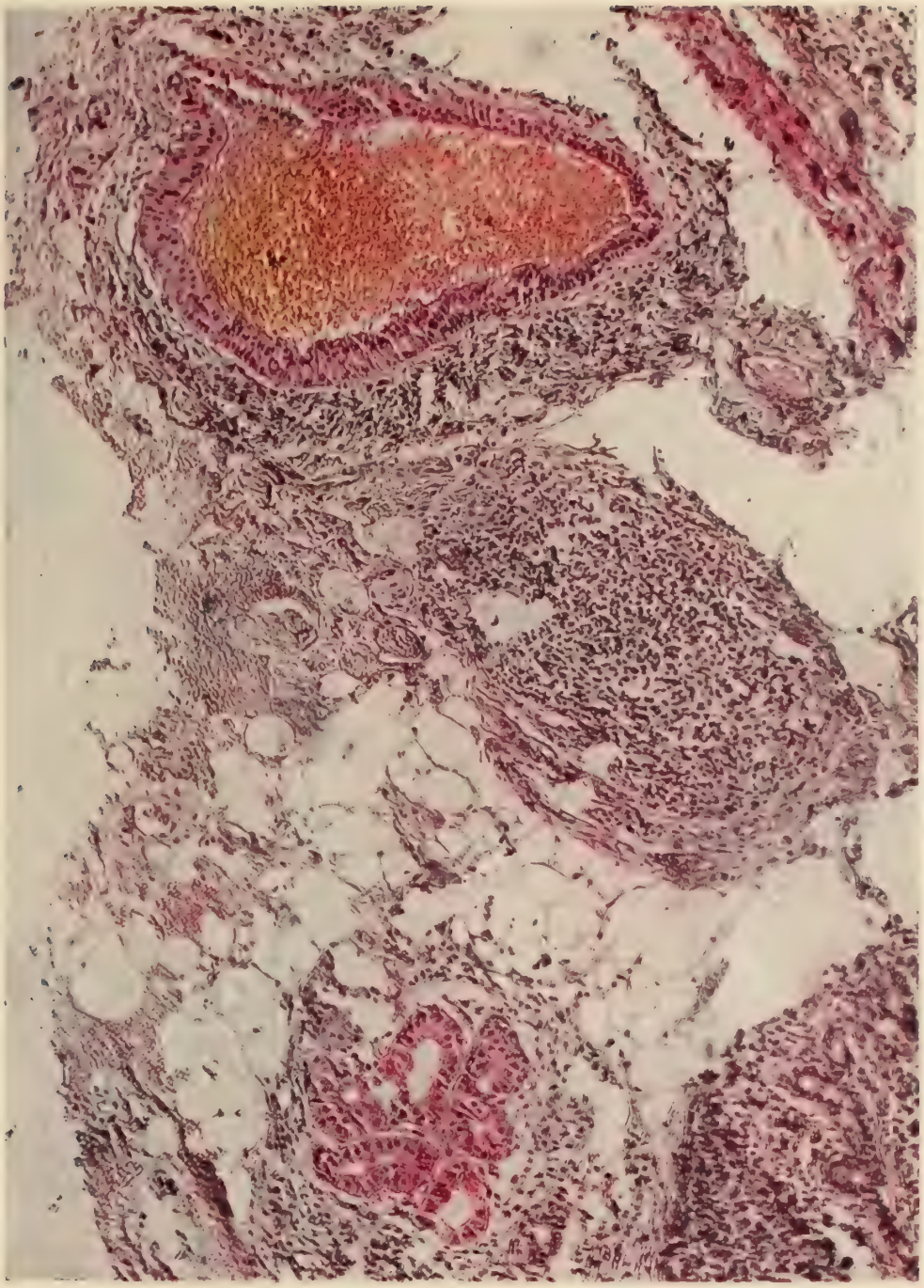

FIGURE 454. XEROSTOMA (DRY MOUTH) SECTION OF SUBLINGUAL GLAND OF PATIENT, CASE NO. 955, SHOWING A CHRONIC PROLIFERATIVE INTERSTITIAL INFLAMMATION, WITH NECROTIC DESTRUCTION OF ACINI. THE INFECTION IS WITH DIPLO- AND STREPTOCOCCI.

[OTHER TISSUES XEROSTOMA.]

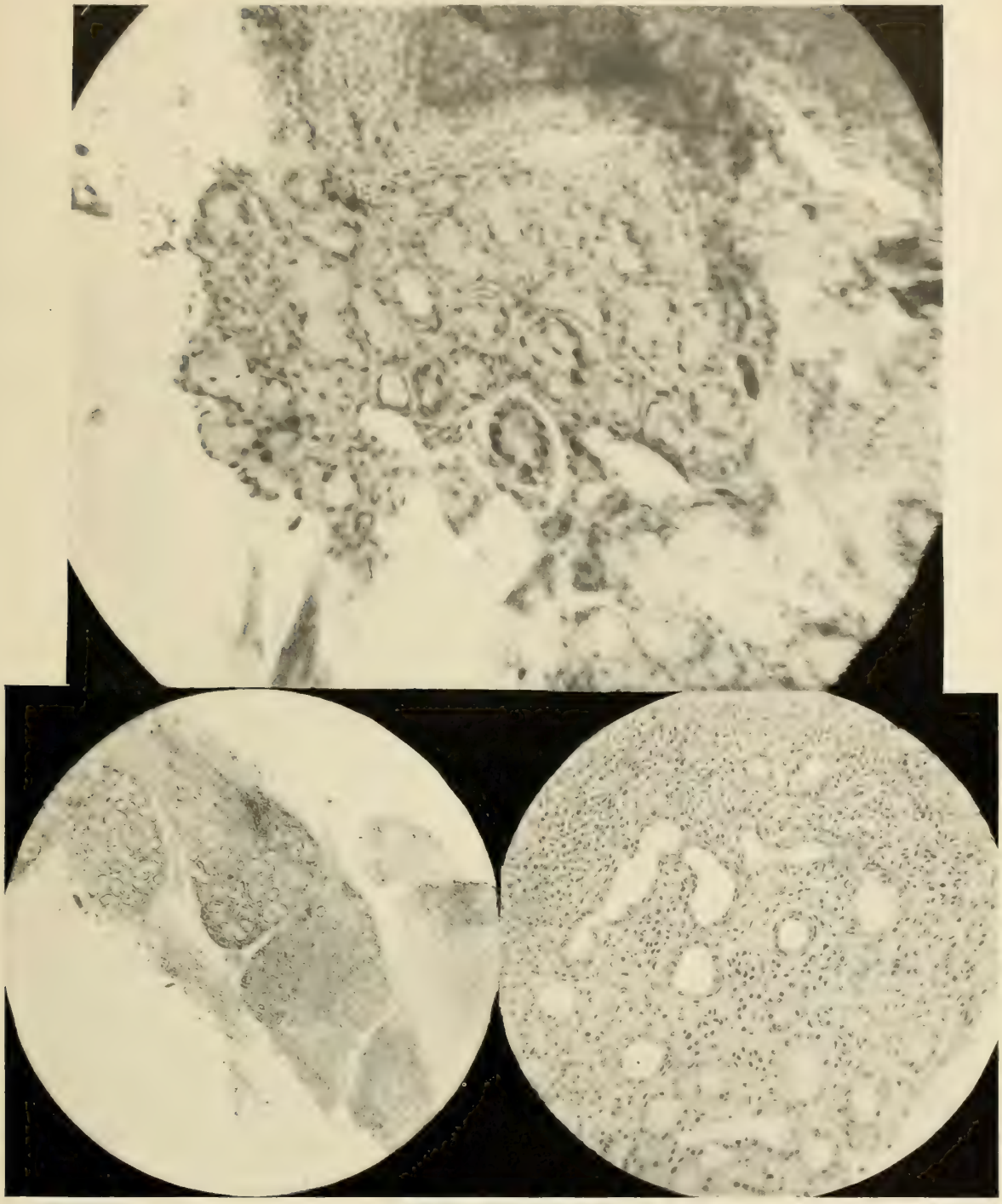

FIGURE 455. TYPICAL DEGENERATIVE NECROSIS OF SUBLINGUAL GLANDS OF DIFFERENT CASES OF XEROSTOMIA.

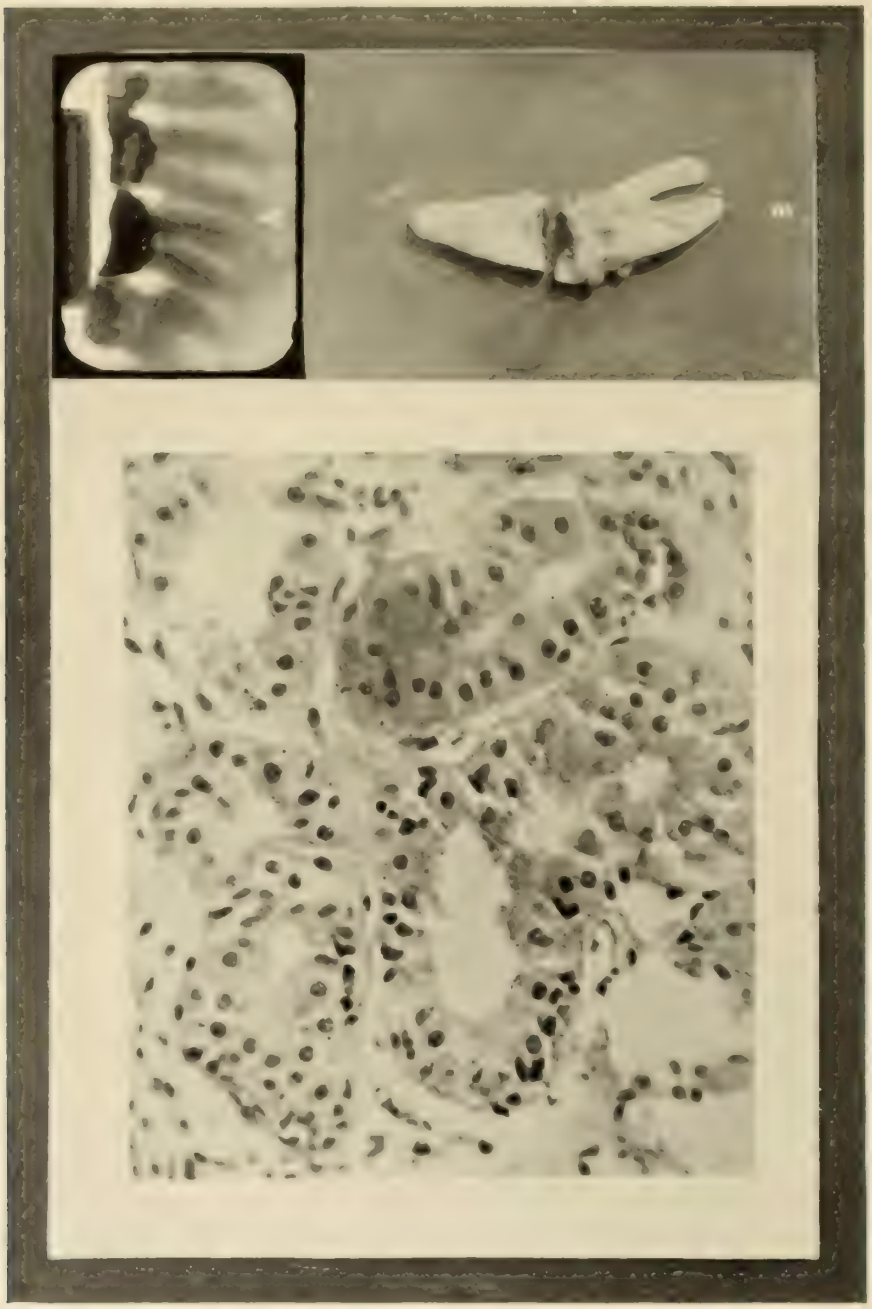

FIGURE 456. XEROSTOMIA. CASE NO. 955. A, ROENTGENOGRAPHIC APPEARANCE OF LEFT MANDIBULAR SECOND MOLAR; B, PHOTOGRAPHIC APPEARANCE OF BIFURCATED MESIAL ROOT; C, HYPERTROPHIED LOBULES OF PATIENT'S SUBLINGUAL GLAND.

times and always failed, and always seemed to leave the condition worse than previously. Since cultures taken from the glands always produced the same organism in pure culture, and since the same organism was found in the root of the extracted tooth, it was

deemed wise to use an autogenous vaccine made from this organism as grown from the tooth with the hope of boosting the patient's defense.

Studies of the blood showed hemoglobin 80 per cent on four occasions, and the erythrocytes varied from 3,400,000 to 4,400,000, and the leucocytes varied from 12,000 to 21,000. The mononuclears, when we started our vaccine treatment, were 18 per cent, and the Arneth Index was very low. After the use of the vaccine, the hemoglobin advanced to 90 per cent (and later to 95 per cent), and the erythrocytes to 5,200,000, and the leucocytes remained at about 12,000 to 13,000. The mononuclears reduced 1 to 5 per cent; the Arneth Index improved.

The effect on the secretion of moisture was definite. The material exuded from the ducts frequently without much effort. The general condition of the mouth was more moist. For the first time in a few years she was able to lick a postage stamp and seal a letter; and also for the first time in a few years, she had enough moisture in her mouth to swallow when awakening. When talking or otherwise keeping her mouth open, it rapidly dried out so that it was nearly as dry as the surface of her face. It was necessary for her to avoid continued conversation, public speaking, etc.

While this patient had been treated in several of the best institutions of the country, she stated that, practically, no improvement had been made; in one, after studying her case for a couple of weeks, she stated that they advised her that since there was nothing known about the disease, all they could do was to give her the Greek name of it. The evidence at hand strongly suggested that the patient was suffering from a streptococcal infection of both the salivary and mucous glands, with the resultant necrosis and toxic poisoning which was progressively advancing.

In order to determine whether the organisms secured from these diseased glands had elective localization qualities for those tissues, several animals were inoculated with these cultures with the result that in many instances extensive involvements of the sublingual, lingual, and submaxillary glands were produced. Figure 457 shows in A a sublingual, submaxillary, and parotid gland of a normal rabbit in the upper row, and in B the corresponding glands as removed from one of the experimental animals, inwhich it will be seen that they are practically doubled in size. In Figure 458-B there is shown a dissection of the sublingual glands



FIGURE 457. SUBLINGUAL, SUBMAXILLARY, AND PAROTID GLANDS: IN A, FROM A NORMAL RABBIT; IN B, FROM A RABBIT INOCULATED WITH A CULTURE FROM A TOOTH SHOWN IN 456.

in another rabbit, enlarged and exposed *in situ*, and in A an acute suppurative arthritis produced in the same animal, which is a common complication with this disease.

Another patient suffering from xerostomia in a more aggravated form, if possible, has shown on section of a piece of her sublingual gland (See Figure 459) the same general pathological changes, as seen in Figure 454. In A will be seen one of the functioning tubules, enlarged and degenerating, and in B the extensive degeneration and necrosis of the secreting acinus. In one of the rabbits inoculated with culture from the gland exudate, which at times was purulent, most profuse involvement was produced in the sublingual gland with hemorrhage and infected areas about to break down with necrosis, as shown in Figure 460.

The prognosis of these cases is always bad. However, we have more hope from the result of another case that has been under our observation which was of shorter duration (approximately one year since its onset) and which under treatment with removal of dental infection and the use of cod liver oil returned practically to normal. This I administered on the presumption that since xerophthalmia, a similar dry affection of the eye developing into suppuration, is influenced, if not produced, by the absence from the food of a special fat soluble vitamin which is found abundantly in cod liver oil, that substance might be of benefit in these

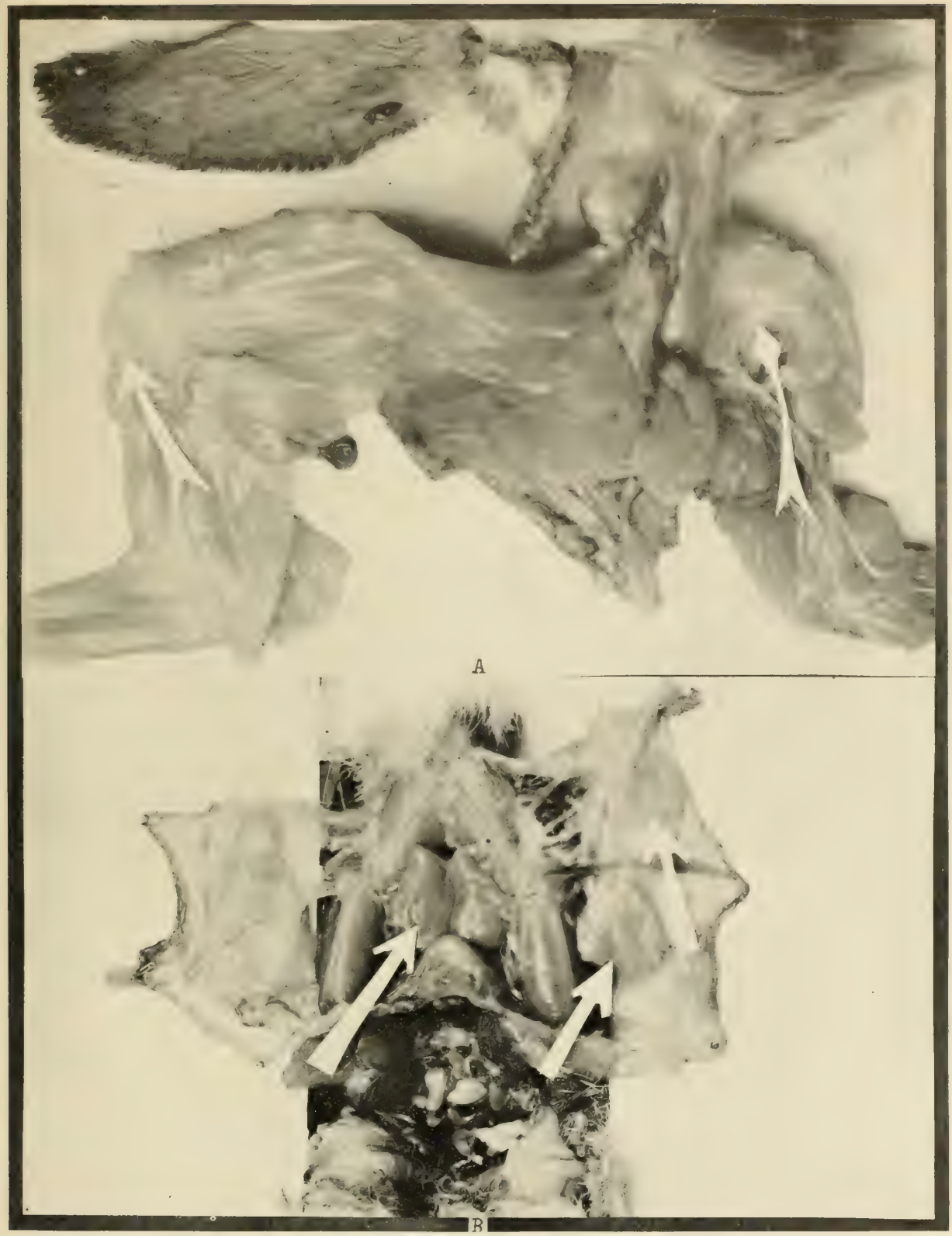

FIGURE 458. B, A PAIR OF GREATLY HYPERTROPHIED SUBLINGUAL GLANDS PRODUCED IN A RABBIT FROM CULTURES FROM CASE NO. 955 WITH XEROSTOMIA AND RHEUMATISM. A, AN ACUTE SUPPURATIVE ARTHRITIS IN SAME RABBIT.

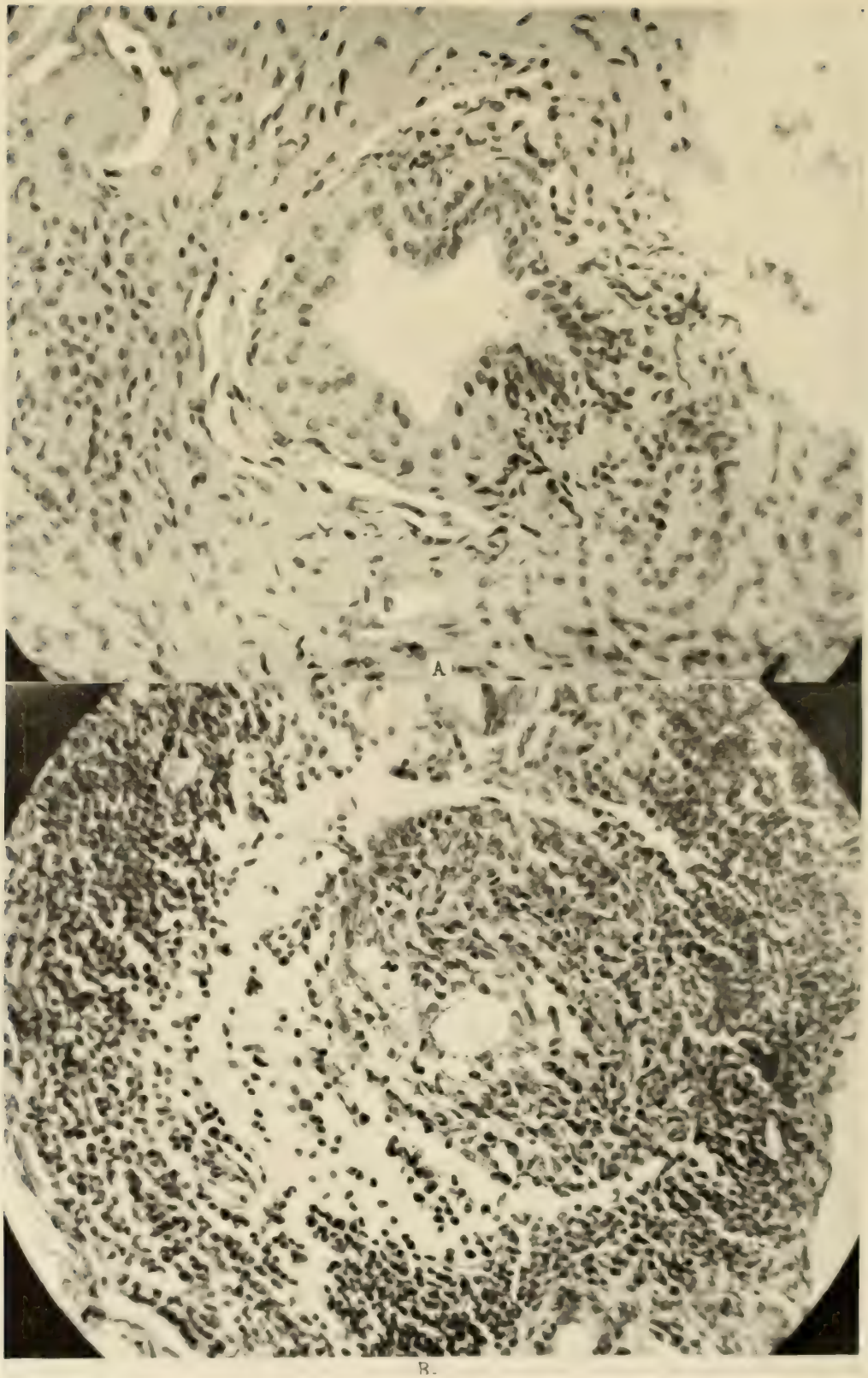

FIGURE 459. SECTION OF SUBLINGUAL GLAND FROM CASE NO. 1136, SUFFERING FROM XEROSTOMIA. NOTE MARKED DEGENERATION OF ACINUS AND SECRETING LOBULE.



FIGURE 460. A SUPPURATIVE AND HYPERTROPHIED SUBLINGUAL GLAND OF A RABBIT INOCULATED FROM CASE NO. 1136.

cases. Figure 461 shows a histological section of a piece of the sublingual gland of this patient in which it will be seen that the destructive changes and necrotic processes had not progressed nearly so far as in the preceding cases.

While, so far as we can find in literature, this is the first suggested interpretation of the pathology based on either dissections of the glands of the patient or animal experimentation, we do not feel that the explanation is so simple as a simple bacterial invasion of a streptococcal strain having elective localization for this tissue. Because of the marked beneficial effect in the last case cited of the use of cod liver oil, it seems very probable that the bacterial invasion is either related as a destructive factor to some essential hormone which is concerned with salivary and mucous production, or that such a substance has a counter part to some extent in the fat soluble vitamins, whether A or D, or some other with which we are not familiar.

ORAL HERPES.

It is not uncommon either in association with dental infections or following operations for their elimination, that patients are affected with herpes which may extend over a considerable area or be limited to local zones. The local structural pathology of this condition has been obscure. Our histological sectioning of these tissues has shown a diplo-streptococcus growing within the tissue. These tend to produce minute subepithelial abscesses

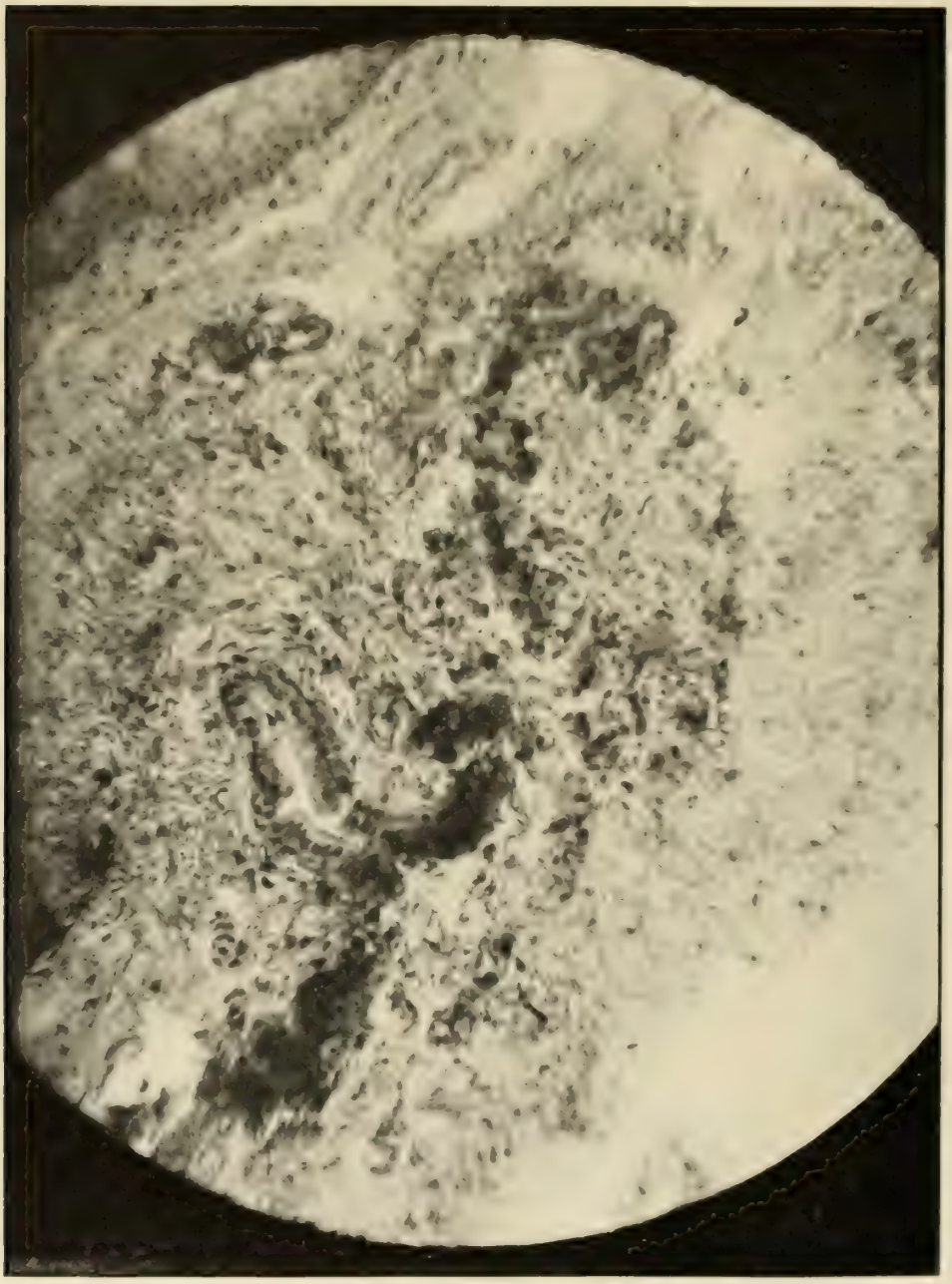

FIGURE 461. SECTION OF SUBLINGUAL GLAND OF CASE NO. 1185, SUFFERING FROM XEROSTOMIA. SHOWS A DEGENERATIVE LOBULE WITH FIBROSIS.



FIGURE 462. ORAL HERPES. AN ACUTE STREPTOCOCCAL ABSCESS BENEATH THE EPITHELIAL LAYER OF THE MUCOUS MEMBRANE.

immediately beneath the epithelial layer of the mucous membrane. A cross section of one of these is shown in Figure 462.

DENTAL CYSTS.

Probably no single dental lesion presents more obscure and at the same time serious systemic involvements than do dental cysts. It is probably because of the subtleness of the involvements that they are so generally overlooked except as they are accidentally found in general roentgenographic procedure. As an illustration of the extreme severity of the symptoms that they may produce, I present the following case. I was called at night to see a boy of about fifteen years of age, who had so acute a heart involvement that his pulse was running at 160, with very marked dyspnea, and conditions getting so progressively worse that I was called in consultation with his physician who was unable to find a contributing factor that could account for the extreme involvement.

An examination of his mouth disclosed that a deciduous cuspid had been retained and gave a history of complete freedom from local inflammatory processes. Over the position of the unerupted cuspid there was a tumor-like mass, entirely free from tenderness on pressure. A careful examination of the deciduous cuspid revealed that the pulp was non-vital. I decided that the tumor-like mass was a cyst and, accordingly, under a local anæsthetic perforated its bony wall and evacuated a quantity of cloudy cyst fluid not at all purulent. Later a roentgenogram was made of this



FIGURE 463. A DENTAL CYST WHICH PRODUCED A VERY ACUTE HEART INVOLVEMENT IN A BOY OF FIFTEEN. PULSE RATE DROPPED FROM 160 TO 80 IN A FEW HOURS AFTER EVACUATION OF CYST, WITH RAPID AND COMPLETE RECOVERY

condition, which is shown in Figure 463, with the cyst chamber surrounding the crown of the permanent cuspid. In a few hours' time this boy's heart rate was down to approximately half its rate for the twenty-four hours preceding this evacuation; and, though it was taken several times in the next few days, was never found above 90. That this cyst fluid contained, and was elaborating a toxic substance which had an elective localization for irritating his heart is very strongly suggested by his and several other cases. This boy has two brothers, both of whom have had heart involvement. His father died of heart involvement, and the evidence indicates that he has a predisposition, therefore, for sensitization affects or irritation of that tissue.

Sometimes the cyst elaborates a substance which produces an effect on an individual very similar to that of cerebral hemorrhage. Such a case is the following: This patient, at seventy-five, was brought by a physician with the statement that one foot was in the grave and that I must be very careful. His life had nearly passed out several times with an affection similar to a stroke. This affection would sometimes have a motor expression

only, as, for example, on one occasion when he went to walk toward the door, he involuntarily would turn to the right, a direction he did not wish to go and keep on walking, resulting in a circular movement. This would happen sometimes in the house and sometimes in the street. At times his speech would be thickened for a few hours. His blood pressure would vary from very high to very low in a short period of time.

A most important and significant incident happened in connection with the care of his case. A local anæsthesia was used for the drainage of this very large cyst, which had its origin beneath the lower left bicuspid and extended from the molar region on the left to the cuspid on the right, with the denudation of the roots and the devitalization of all the intervening teeth. Prior to his being brought to me, he had had an involvement which had kept him in bed for a day, similar to a stroke, involving his entire left side, including his speech. The operation, which I used for the drainage of this cyst, involved a liberal opening which uncovered the inferior dental nerve and blood vessels passing through the floor of the cyst; and in order that these might not be destroyed, the procedure involved the extending of the mucous membrane of the mouth to include the entire cyst chamber and thereby displace the pathologic membrane lining that orifice, sections of which are shown in the discussion of the next case. The chamber was, accordingly, packed lightly, while under the anæsthesia, to protect the sensitive structures. When this packing was removed on the following day, the reaction on the patient was to bring on instantly all the symptoms of a cerebral hemiplegia, which involved all of the motor control of his left side, including his speech. This paralysis was so complete that his foot and arm hung lifeless by his side. This paralysis lasted several hours.

A most remarkable factor in connection with these cysts is that mechanism of the progressive absorption in advance of the pyogenic cyst membrane. In this instance, as I have stated, all the teeth from the lower left bicuspid, about the apex of which the cyst started, to the lower right cuspid, had their apices denuded and were, accordingly, devitalized. Photographs of them are shown in Figure 464.

Two things are important in this case. The first is that the heart block and disturbances of arterial tension quite completely disappeared. Another is that notwithstanding this man's far



FIGURE 464. A DENTAL CYST WHICH STARTED WITH THE LEFT MANDIBULAR BICUSPIDS AND EXTENDED TO THE RIGHT CUSPID, SHOWN IN A AND B. C SHOWS THE ABSORBED ROOT APICES OF THE LOWER INCISORS AND LEFT CUSPID. PATIENT, SUFFERING FROM HEART BLOCK AND SYMPTOMS OF STROKE, HAD A REMARKABLE RECOVERY.

FIGURE 465. A, HUGE CYST BULGING THE CHEEK AND EYE. B, ROENTGENOGRAM OF ENORMOUS CYST CHAMBER FILLED WITH OPAQUE. THE MAXILLARY SINUS HAD BEEN ENTIRELY OBLITERATED.



FIGURE 166. ORAL APPEARANCE OF CYST SHOWN IN A. B, ENTRANCE MADE TO THE CYST IN THE ORAL CAVITY. CASE NO. 1098.

advanced age, in a few weeks' time he was able to walk five to ten miles without tiring, and for about three years has had most remarkably good health.

In another chapter, Figure 390, Chapter 65, I have shown a third molar that was pushed from its normal position nearly to the base of the condyloid process. This process of pressure may produce an extreme distortion of tissue, even to the extent of very serious facial deformity. Such a case is shown in Figures 465 and 466. This man, age forty-two, had a dental cyst developed to the enormous size shown in Figure 465-B, which is a roentgenogram, reduced size, of the cyst chamber temporarily packed with an opaque gauze. This chamber developed, pushing its walls in all directions until the maxillary sinus was entirely obliterated, the right naris was nearly obliterated, the eye was bulged, and the floor of the orbit pushed upward. The cyst extended mesially to the eye, up about two centimeters higher than the floor of the orbit. A digestive disturbance was an important factor in this case.

A section of the cyst membrane and bone adjoining it, is shown in Figure 467-C; and it will be seen that the osseous structure is being torn down by the osteoclastic cells as the hydrostatic osmotic pressure pushes the pathogenic membrane closely against the tissue and reëstablishes, continually, the pressure reaction which on the outer surface of this membrane results in the taking down of bone. The content of this and similar cysts is shown in Case No. 978 in the chapter on Skeletal and Muscular System.

In all these cases it is necessary to maintain a free opening into these chambers for sufficient time to permit the mucous membrane of the mouth to extend to all parts of the cyst chamber and make the new chamber a part of the oral or some other natural cavity, at least for a considerable period of time. Both because of the great size of this cyst, which made the surgical development of a connection with the oral cavity very simple, and because of the necessity for maintaining this opening and at the same time preventing the passing of food into this chamber, the dental restoration that was made carried a huge plumper which passed up into the face nearly to the eye, into the zone formerly occupied by the maxillary sinus and now a part of this cyst chamber. Results have been exceedingly gratifying, if not ideal. The external facial deformity has rapidly disappeared, for his cheek was badly bulged and the eye displaced, as shown in the photograph. The

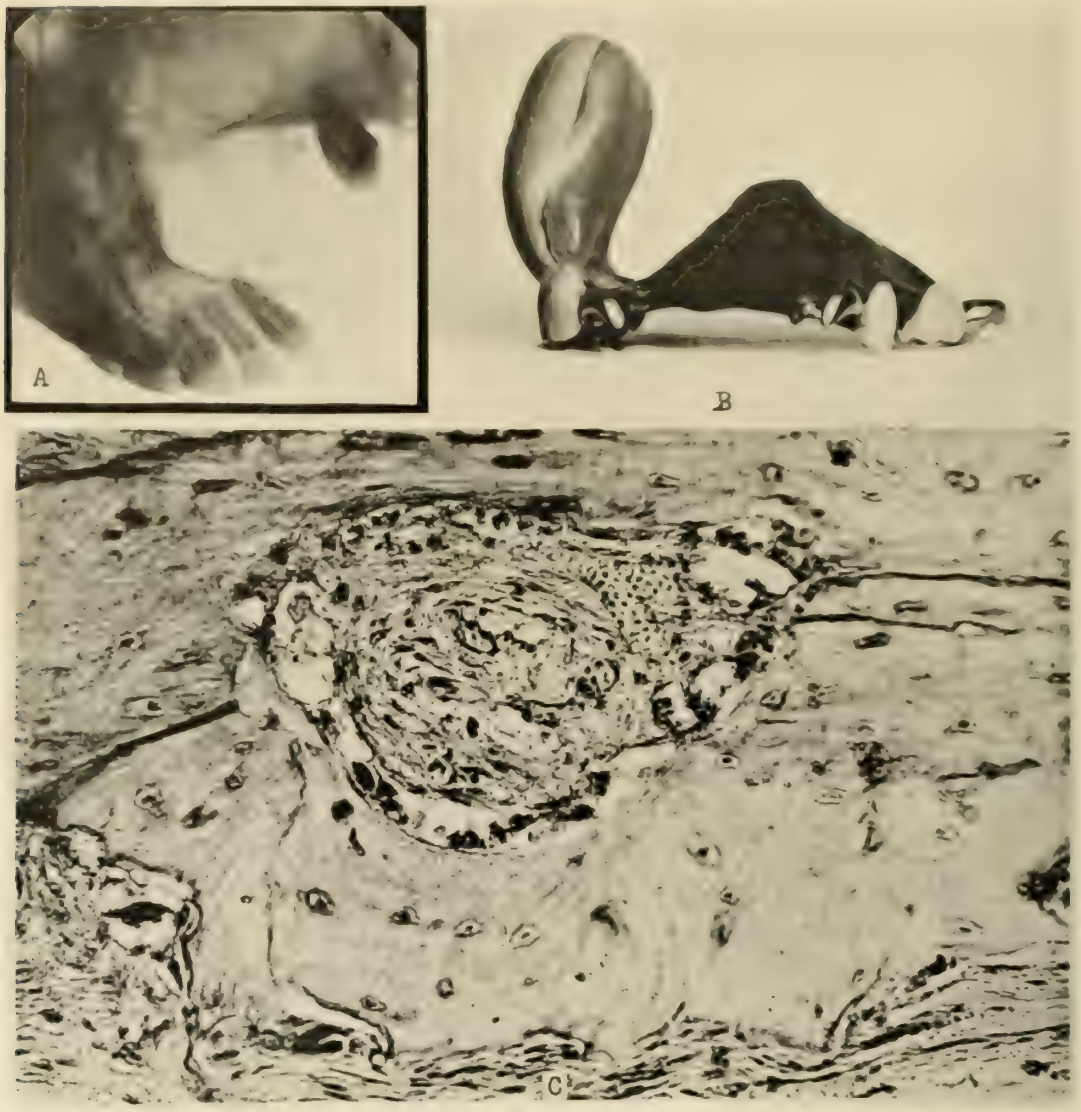

FIGURE 167. A, A ROENTGENOGRAPHIC VIEW; B, ARTIFICIAL DENTURE AND SPLINT TO SUPPORT THE DESTROYED CHEEK BONE AND PERMIT ORAL MUCOUS MEMBRANE TO EXTEND AND DISPLACE ALL CYST TISSUES. RESULTS EXCELLENT. C, SECTION OF BONE ADJOINING ADVANCING CYST. NOTE THE ACTIVE OSTEOCLASTIC PROCESS. CASE NO. 1098.

cyst chamber has slowly reduced in size and he wears this restoration with complete comfort and masticating efficiency.

A phase of this case is of particular importance. I have been advised that arrangements had been contemplated for a major operation, entering this zone from the external surface to remove a malignant tumor. Our method of study in this case, as in many of these cases where there is any doubt regarding the content, is to make a microscopic examination of aspirated material,

which in this case readily revealed the nature of the cyst. When cholesterol accumulates in these cysts to a concentration in which the osmotic pressure is greater than the osmotic pressure of the lymphatic circulation and of the blood stream, there is a flow of serous fluid to this salt of higher concentration in the pathological fluid than in the blood fluids. The membrane lining the cavity takes on a state of semipermeability, allowing the serous fluid to pass readily into this chamber, but not allowing the cholesterol to pass out. There is, in consequence, an ever enlarging chamber, which, by its own hydrostatic pressure, pushes back all flexible tissues, and by pressure on hard tissues accomplishes their absorption. It is a force analagous to that which makes plants grow.

The history of this case shows that four years prior to his being brought to me he had suffered a toothache on the right side of his face and had presented for treatment for same, a part of which included the placing of a bridge on the affected root. The symptoms reported indicated that he had suffered from an abscessed root. The evidence available seems to demand the general recognition of the fact, that teeth, and particularly roots of teeth, with an involvement for sufficient length of time for the peridental membrane to be destroyed at the apex of the tooth, will produce a condition which will in most instances constitute a potential factor of danger in that there is no evidence available that the cementum, when once denuded and devitalized, will ever again permit of the normal attachment of tissue; nor is there evidence that such tissue, even though it may be sterilized, which is questionable, can be retained in a sterile condition. Cyst material taken from this patient and inoculated into rabbits, produced the serious heart involvement of the rabbit shown in Figure 468. The patient complained of a marked lassitude, which symptom quite completely disappeared with the drainage of the cyst.

But dental cysts seem also to produce toxic substances which have a marked affinity for nerve tissues, and whether or not gravity is a chief factor, it seems probable that it is a contributing one since the cervical nerves are more readily involved with toxic invasion than those of any other part of the body. A most logical route for the toxic material developing under pressure from dental abscesses or dental cysts will be through the lymphatics draining that area, and these have a very wide anastomosis into the neck and thoracic cavity. A striking illustration of this will



FIGURE 168. HEART OF A RABBIT WITH ENDOCARDITIS PRODUCED BY THE INOCULATION OF CULTURE FROM CASE No. 1098.

be found in Case No. 978. Photographs of this patient's lesion are shown in Figure 367, Chapter 64, on Skeletal and Muscular System. The cyst in that case was in the maxilla. The most striking feature of it was that a lesion, which had dominated and greatly diminished the efficiency of this individual for many months, was greatly relieved within five hours after the draining of the cyst. It is also important that these symptoms returned at one time during which he failed to maintain drainage when the artificial substitute, which was closely adapted to keep food from getting to the chamber, was left in position for several days, the result of which was the development in the chamber of the characteristic cyst fluid, with a concentration of cholesterol and other substances, and which symptoms rapidly disappeared again with the complete irrigation and reestablishment of the proper treatment. The inoculation of a rabbit with the material contained in this cyst produced an acute involvement with the spasmodic contraction of the hind leg, which is shown in Figure 367.

In the chapter on Digestive Tract Disturbance, I have discussed a case of extensive cyst, to which I have just referred, in which the third molar was pushed backward and upward (See Figure 390). In that case the patient was suffering from a very acute digestive tract disturbance. The significance, then, in that case was that the patient had a colitis with evacuations on an average of every thirty minutes. Rabbits inoculated with the content of the cyst of that patient developed acute diarrhea in about forty minutes, and several of them developed very severe colitis, and, on posting, had extreme distention of the colon with typical spastic colitis.

APICOECTOMY.

It will not be possible to cover all of the involved phases of dental practice in this general analysis of the fundamentals of oral and clinical dental pathology. It is, however, important to emphasize again the type of individuals for whom certain operations should be considered more favorable than for others. It is not necessary for me to review here why individuals, with a broken defense or who by inheritance have never had a normal defense for streptococcal infection, should not have produced in their bodies conditions which can furnish the type of organism which even in small quantities may bring upon them their most to be feared disaster: namely, a streptococcal involvement of an essential organ or tissue. These individuals should in my judgment have all questionable teeth removed, by which I mean teeth that modern science cannot demonstrate not only the capacity of the operator with certainty to make them free from infection, but the capacity of the patient carrying them to maintain them in a sterile condition, assuming they have been made so; in other words, individuals with any of the following—a serious heart, kidney, or central nervous system involvement—not only should not have root-filled teeth left in their mouths, but should not have involved pulp chambers of teeth of such individuals root-filled. I am presenting this as my best judgment and I will ask those, who with perhaps a great deal of enthusiasm challenge my position, to measure carefully whether they have as good a basis for judgment in dental pathology as I am presenting in these volumes. If so, I would greatly desire that they will put me in touch with the data.

Nor is it my judgment that individuals with these serious handicaps of broken or absent defense should have the operation of apicoectomy with the expectation that these teeth will be safe. In the thousands of teeth that we have cultured from various individuals, a very large number of which were from individuals of this group, we have not found one in one thousand from the inner structure of which we could not grow streptococci. The

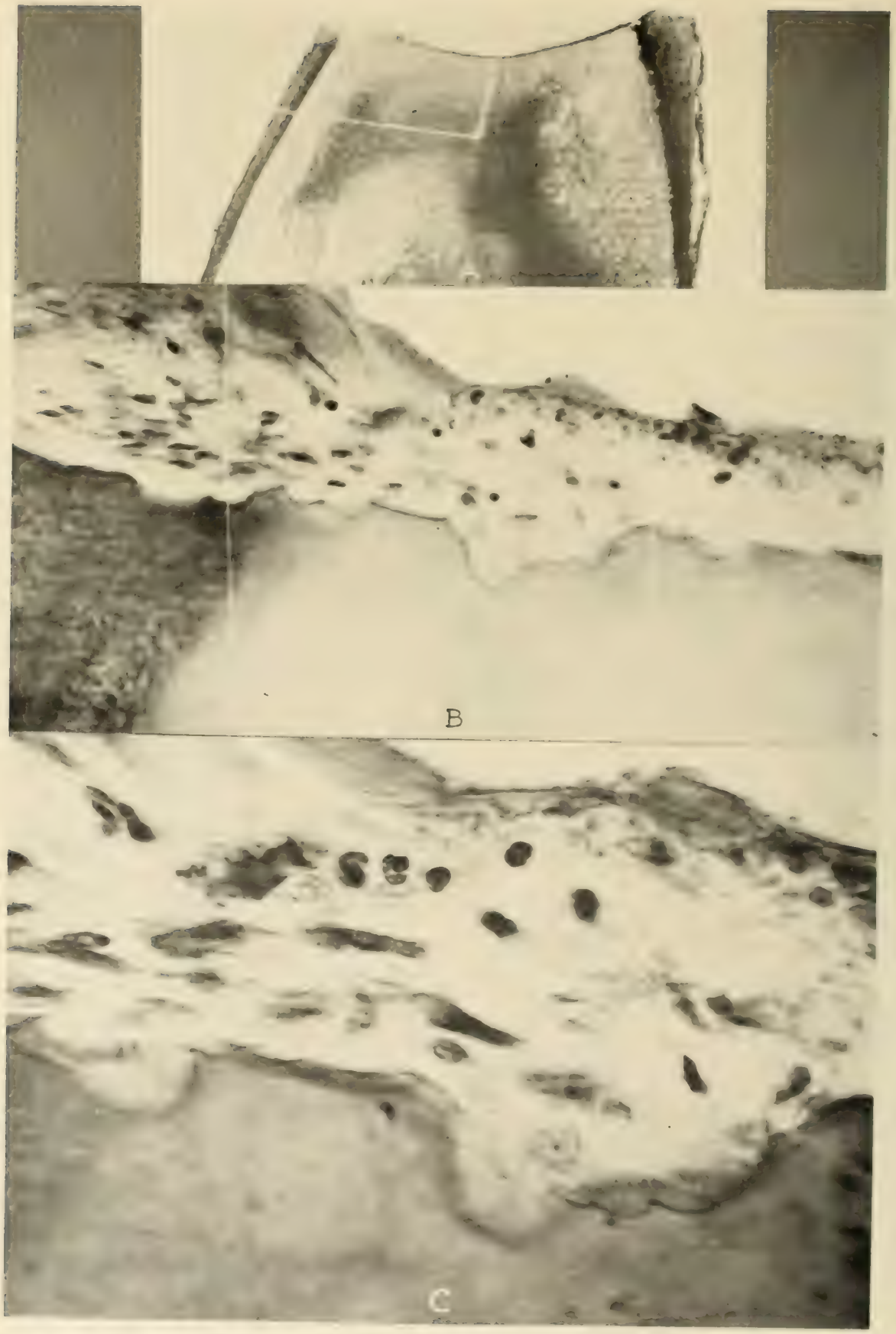

FIGURE 469. REACTIONS ON A RESECTED TOOTH: A, LOW POWER VIEW OF STUMP; B, ABSORPTIVE MEMBRANE, MEDIUM POWER; C, OSTEOCLASTIC ACTIVITY ABSORBING TOOTH.

problem, therefore, is not solved by placing a root-filling and taking off the apex. If, however, root resections are to be made with the expectation that they will conserve a very valuable tooth and therefore render an important helpful service, they should be made for those individuals with a high defense; and for those who are in a mood to resist or react against the sentiments I am expressing, I will ask them to turn quietly to Chapter 64 of the second volume or Chapter 41 of the first volume, and note the difference in the bactericidal properties of bloods of individuals of these two groups. These people only look alike because of our inability to see what they look like; and in no department of dentistry is a new truth so truly a new sense as in this matter of being able to see people more nearly as they are, than we have been accustomed to do when we used as our glasses comfort and serviceability as the evidences of efficiency and defense, and freedom from infection. With this new sense, these have little or no weight when compared with the bactericidal capacity of the blood, etc.

There is, therefore, an exceedingly great difference in the reaction that will be made by different individuals about either an infected root or an infected root apex. Individuals of one group make almost no effort and show by the results almost no capacity for neutralizing the toxic products, whereas those of the group of high defense may show a very great effort to get rid of and neutralize the toxic irritant. This will be illustrated in Figure 469, which shows three views of a root apex under different magnifications, demonstrating the activity of the host in trying to remove the infected root. A shows a cross section of a tooth from which the tip had been resected some months previously. The light line in A shows the zone removed for sectioning in B. In B it will be seen that a membrane has been formed over the excised surface which is showing a marked activity in absorbing the root, which to the host has become a sequestrum, for whether we are ready to acknowledge it or not, the dentin at least of every pulpless tooth is a sequestrum and often an infected sequestrum, but different from an ordinary sequestrum in that it is surrounded in part or in whole by vital cementum, which latter is surrounded by vital supporting tissue. Unfortunately it seldom, if ever, is true that it is surrounded in whole by vital cementum. Since the foramen or foramina become port holes of exit for toxins, and usually for bacteria, even though the dentino-cemental border

may be impervious to one or both. In C, which is a higher magnification, we see the osteoclasts actively engaged in the process of taking down the tooth structure to remove this tooth.

The type of individual that produces this type of reaction is carrying the fight right up to the point of contact and is closing in upon and making smaller the boundaries of that contact by tearing down the foreign process. In individuals of the groups with lower defense, we do not get this type of reaction. The fight is not carried up to the tooth, for little, if any, fight goes on immediately surrounding the tooth but must ultimately be waged far afield from this (the proper) battleground in the various organs and tissues of that individual's body. Nor does the presence of such an active process guarantee that this patient will always be safe from injury from this type of involvement. It is very probable that this type of reaction will mean for the individual who can make it, a tender tooth, as it did in this case. Comfort is not a measure of safety or assurance of success. It may mean just the opposite.

THE REPAIR OF DENTIN AND CEMENTUM.

Of all the structures of the body the teeth have the poorest capacity for repair. So far as I know there are no acceptable data demonstrating that a cavity of caries in enamel and dentin has actually been filled in by a normal tooth structure. I have seen cases where this was alleged to have transpired but I think they were mistaken. The very nature of these structures and of their formative processes precludes a reparative process except in vital tissue, and carious enamel and dentin cannot be considered to be vital. When, however, an injury happens to vital dentin and cementum, a reparative process may occur. This most frequently occurs at the pulpal surface of dentin, due to peripheral irritation, and produces a secondary deposit of dentin within the pulp chamber, which may very efficiently protect the pulp tissue from the disturbing irritant. When irritation disturbs the cementoblasts, they too may throw down a deposition of cementum, structurally quite similar to the normal. In the chapter on Skeletal and Muscular System in the discussion of Osteomalacia, I have illustrated different types of reaction in bone in patients of different groups. The process of building up and taking down cementum is dependent upon physical forces and may be physiologic or pathologic in accordance with contributing factors. In the treatment of periodontoclasia it will be a matter of exceeding great value if, in addition to checking the progressive destruction of the supporting tissues, they can be made to rebuild. I have demonstrated to my complete satisfaction that this process can occur, though I am convinced that the conditions necessary for it to take place extensively can be secured only relatively rarely.

In the case of a fracture through a vital tooth root, if the pulp tissue remains in situ, the dentin of the root may remain vital, the peridental membrane may fall over the fractured dentin and may build up on the root an osteoid structure. Such a case is shown in Figure 470, in which A shows the roentgenographic appearance of a long imbedded mandibular third molar root. B

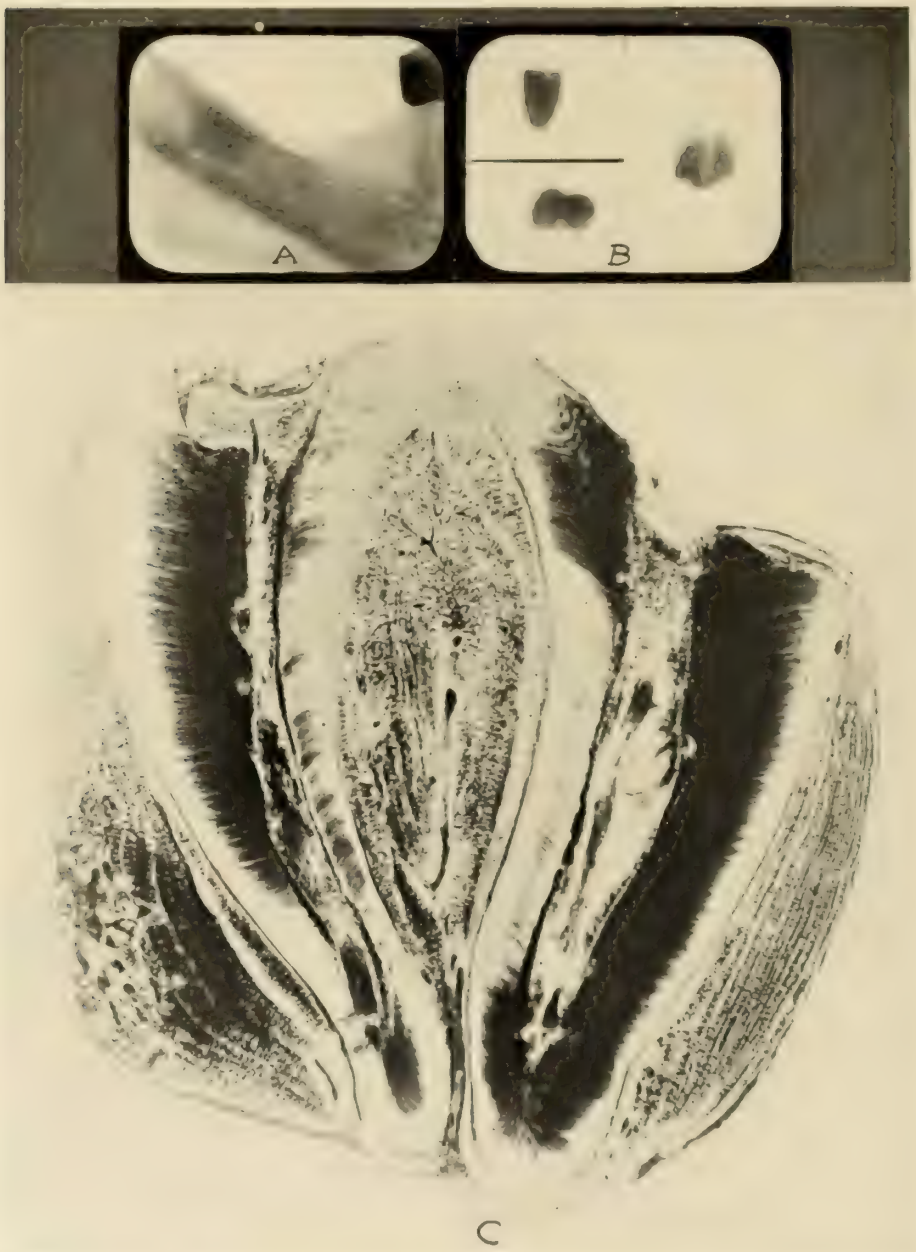

FIGURE 470. AN APPARENT REPAIR OF DENTIN OF AN OVERGROWN THIRD MOLAR ROOT LEFT BY A PREVIOUS EXTRACTION: A, ROENTGENOGRAPHIC APPEARANCE OF ROOT IN MANDIBLE; B, ROENTGENOGRAPHIC APPEARANCE OF IMBEDDED ROOT; C, SECTION THROUGH MESIAL AND BUCCAL ROOTS.

shows the roentgenograms of the root when surgically removed, and C a mesiodistal section through the two roots. It will be noted that there has been considerable excementosis by a process of successive laminations, greatly increasing the size of the root. The pulp chambers were filled in with an osteoid bone, and where the peridental membrane fell over the freshly fractured dentin, it has built a structure, very similar to cementum, onto the dentin. Higher powers of these different structures are shown in Figure 471, in which in A there will be seen the lumen for a blood vessel passing through the osteoid structure, which has displaced the pulp tissue of the mesial root. Note the lamination of this osteoid structure. B shows a higher magnification of the distal root, and the osteoid cementum can be seen in direct apposition with the fractured surfaces of the dentinal tubuli. D shows a higher magnification of B, and C a higher magnification of A.

It is not probable that this process can so readily obtain on dentin which is not potentially vital. In Volume One I have shown in many places, illustrations of an osteoid structure built into the dentin following an absorption process. It would be highly desirable if some such reparative process could be induced to develop about apical areas that have been rendered free from irritation products. Whether or not remote instances of this can be presented, it will make little difference to the clinical fact that the percentage of cases where it occurs is exceedingly small. There is, however, a structural approximation which takes place about excised root ends, which suggests either a very small amount of irritating material from the root end or, as is very frequently the case, a very low capacity for reaction to such irritant as does obtain in that tissue. This type of reaction is also ideal in periodontoclasia pockets.

In thirty years of very critical search for illustrations of such a process, the instances where I have been satisfied that it had actually occurred to any considerable extent are few. The following is an illustration. The patient, a young man, Case No. 935, was suffering from an exceptionally acute gingival inflammatory process with pocket formation. As a matter of experiment I used a burr beside the palatal root of an upper molar, thoroughly to curette the surface of the tooth and the alveolar bone adjoining, to and including healthy tissue. The case was watched carefully and there seemed to be quite perfect reattachment of tissues to the root surface. The tooth was

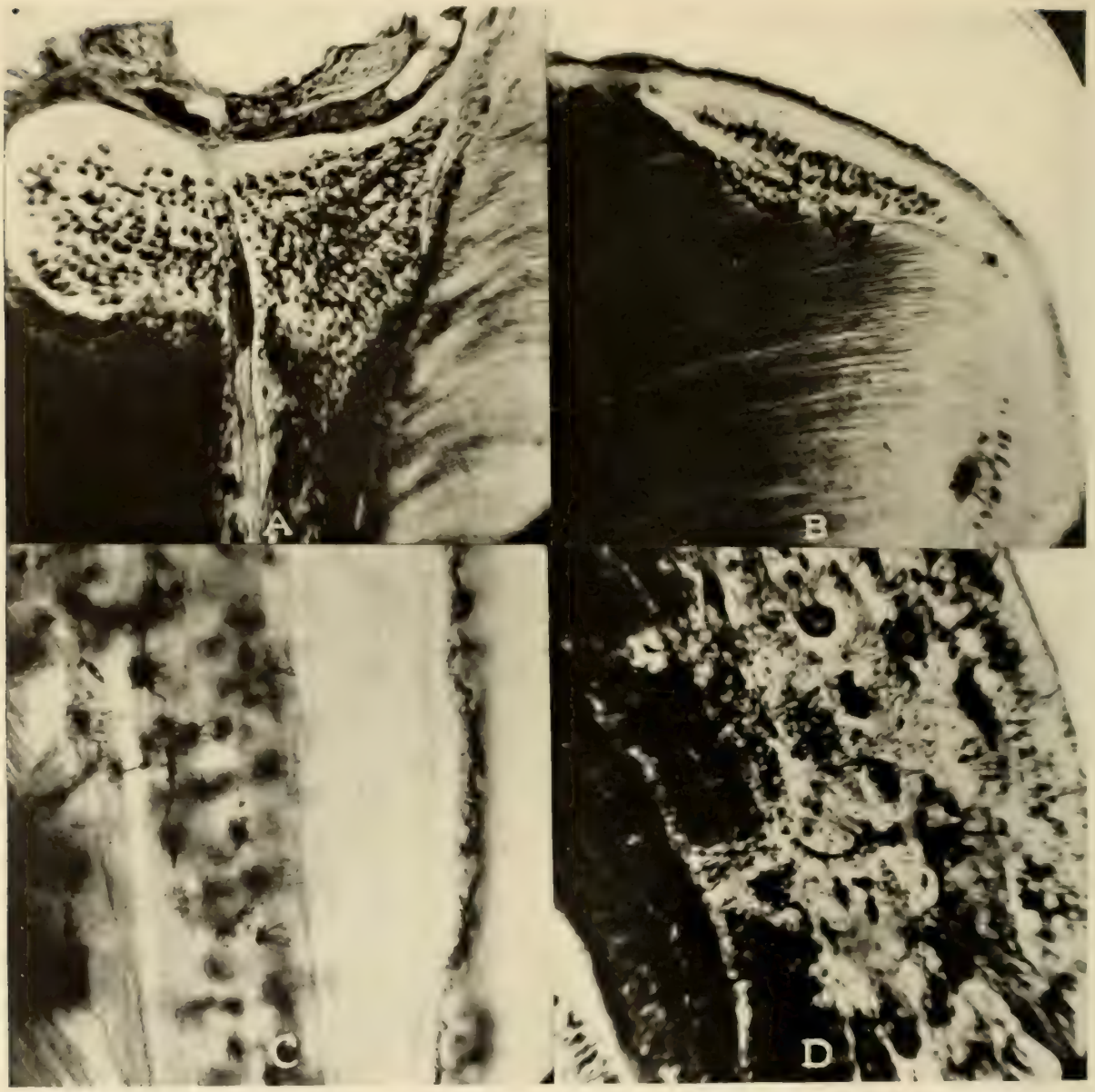

FIGURE 471. HIGHER POWER OF AREAS OF FIGURE 470. A SHOWS FILLING IN OF THE PULP CHAMBER WITH AN OSTEOID BONE THROUGH WHICH A BLOOD VESSEL WAS PASSING; B, AN OSTEOID BONE BUILT UPON THE FRACTURED SURFACE OF DENTIN, OVER WHICH IS A LAYER OF CEMENTUM; C, A HIGH POWER OF THE OSTEOID BONE OF A; AND D, A HIGH POWER OF THE OSTEOID BONE OF B.

carried for years with but little return of the periodontoclasia about it or in other parts of the mouth, part of the reason for which was a program of prophylaxis in which the patient splendidly coöperated. By a fortunate circumstance I was later able to secure this tooth and the attached alveolar bone. I persuaded the patient that he owed it to science to make a provision in his will so that that specimen would be preserved for proper study. He suggested that since the circumstances of his death were so uncertain I had better take it while I could control the conditions of its preservation and sectioning and urged that I do so, which I did. In cross section, the burr marks on the cementum could be seen and had been filled in with an osteoid structure so closely adapted to the tooth as to be apparently perfectly fused. This cementum was apparently vital at the time of the operation and in this particular was probably a quite exceptionally favorable condition.

CHAPTER LXX.

GENERAL DISCUSSION.

INTRODUCTION

In Part One, Chapters 1 to 45, I have outlined in detail a series of researches and presented data developed therefrom. These have dealt with fundamental problems underlying diagnosis, prognosis, and treatment of local and systemic dental infections. In Chapters 45 to 56, I have analyzed the various data and from them have made interpretations on which I have suggested a new basis for dental diagnosis, prognosis, and treatment. In Part Two, Chapters 57 to 70, I have presented a large series of typical cases, illustrating the application of these principles of interpretation and methods of application, together with special researches on both the patients involved and on animals with cultures and tissues taken therefrom. These latter researches on the patients have thrown a flood of new light upon the whole problem of dental pathology when studied in the light of these new interpretations. We have seen from the experimental data that the strain of organism involved is a very secondary matter to the environment in which it is growing: namely, the host who furnishes the soil for it; and this host is an extremely variable quantity when one individual is compared with the majority, while each one except under overload tends to maintain his or her own general characteristics. The elements of chance are almost entirely removed from the problem.

The bacteria, we have found, have the remarkable ability of adapting themselves to changes of environment through exceedingly wide ranges so that they will ultimately grow and flourish in a medium that at first would entirely inhibit their growth, if not kill them. It is an extremely important matter that streptococci can so accommodate themselves to such extremely toxic substances as formaldehyde, iodoform, phenol, alcohol, etc., for this completely changes our problem of rendering a tooth so toxic to them that they not only cannot take up and maintain a residence in it at the time of its treatment but that they shall not be able to take up residence in it again during the rest of the lifetime of that

tooth. We not only have now the problem that bacteria have been killed off in the tooth but that they may be able to take up residence in it again by becoming accustomed to an environment which at first was intolerable. It is for this reason that we find organisms growing in teeth, previously treated with iodoform, which still is present in sufficient quantities to be distinctly and even abundantly present by its odor, when they are opened years afterward.

We have also seen that with varying changes of oxygen tension, hydrogen ion concentration, the type characteristics of the organisms may be completely changed. We find we are dealing with forces that are very changeable and with units of life that are the sum total of these changing forces in terms of their reaction to them. In other words, we are dealing with problems of physics, physical chemistry, and biology, quite as distinctly as in quantitative chemistry or pure physics. The older methods of cut and try with the hope and expectation that, by chance, we shall stumble upon some drug or chemical that is specific for the condition at hand, gives little more hope of being the means of prognosis in the future than the past has so unhappily demonstrated it to be worthy of being. Nor are we justified in reading symptoms as evidences of either reactions or absence of reactions. It is not sufficient that a diabetic insists that he feels well; nor is it safe for the individual with a definite streptococcal susceptibility to carry the forces which will with mathematical certainty subtract from his already reduced factor of safety. The fact that he feels well does not prove that the corner stones of his health are not being slowly undermined by physiochemic processes which are drifting him, though unconsciously, toward a shorter life of health and usefulness. It is not so simple a matter as a bacterium skulking out of the corral about an infected tooth and taking up its residence in the far-away heart or kidney or nerve cell. It may be that, fundamentally, it is primarily a breaking down of the defensive mechanism by the pouring into the system, in ever so small quantities at first, of substances which destroy the efficiency not only of the defensive mechanisms but of fundamental nutritional processes.

It is no accident that there is a great variation in the type of local reaction about dental infections in different individuals. Nor is it a mere coincidence that different individuals of certain types and groups tend to have similar variations from the normal,

and that there are distinct and quite exact relationships between the local structural changes and physical expressions of focal infection. We begin to see some of the forces at work in the production of dental caries, of acute and chronic inflammations of the supporting structures of the teeth, the nature of chronic diseases of the organs and tissues of the body, and the role of heredity.

While there are doubtless many factors involved, regarding which we as yet know little, some others are becoming quite apparent. It is not an accident that, different elements which may be introduced, may produce the same symptoms, as, for example, a deficiency diet and a dental infection, such as a polyneuritis. Nor is it accidental or a mere coincidence that these two forces produce quite similar chemical changes in the blood or that physical overload will aggravate these very disturbances, particularly those which primarily disturb the very elements which are fundamental to the maintaining of the metabolic balance. Nor is it accidental that the same general laws obtain in the vegetable kingdom as in the animal. The gardner has learned to use ether and chloroform to put his plants to sleep, in order that he may hold them back without injuring their vitality, and allow his bloom or fruit to perfect on the very day that he shall desire. Nor is it an accident or a mere coincidence that just as plants cannot grow in a soil in which the ionic calcium is not available in a definite minimal amount and that the cells of our body cannot maintain their health except the ionic calcium of the body fluids does maintain a minimal balance. It is a truth that makes us stand aghast and more and more appalled as we realize our dependence upon the presence or absence of these simple elements. Have we realized that no civilization has ever been maintained on any soil that did not have either a limestone foundation or a water supply from such a foundation?

CHAPTER LXXI.

GENERAL SUMMARY.

INTRODUCTION.

If we would summarize the work of the preceding chapters and the suggestions presented, it would be somewhat as follows: Dental caries, deficient dental and osseous calcification, disturbed metabolism, and deficiency diseases are, fundamentally, expressions of a disturbed physical chemistry of the system. Some of the forces involved are enzymatic, some physical, and some quite purely chemical; and it is probable that when we have come to understand these, we will understand life itself, for disturbed life is but slightly different from the normal. This suggests, if it does not illustrate, how extremely involved the problems of defense and susceptibility are. We do not presume even to suggest what the final answers to these questions will be. We do find, however, in the data from these studies, suggestions as to the probable course that should be taken for future explorations. From the information available to date I would give as the most probable explanation for the various phenomena herewith presented the following:

Growth and health of the hard and soft tissues of the body are dependent upon the maintenance of definite concentrations among other substances of calcium in ionic form. The difference between the minimal and the maximal for health is small, and these limits are close to the optimal. Just as the range of variation from an isotonic sodium chloride solution is very small for it to become hyper- or hypo-tonic to cell tissues, just so the calcium in ionic form must have a very exact concentration; and this does not mean the total quantity of calcium to be found in either the blood, saliva, lymph, or tissue cells, but the amount of calcium in such a structural form as enables it to be available as an enzyme, both for the interchange of other chemicals and for contributing directly itself to life processes.

The total amount of calcium that is required to maintain the wear and tear of body function day by day is sufficiently great, frequently to tax the normal body when in environments where

foods are not available which have a ready supply of this element. Similarly, the calcium itself does not become available except in different ratios and proportions with phosphorus. Fundamentally, then, we are dependent upon bases of supply for these fundamentals as well as many others. But even the available calcium in the system becomes available only because of other substances, particularly the endocrine system, of which probably the parathyroids are the chief contributors. These endocrine glands doubtless are dependent upon the accessory food factors, such as Vitamins A, B, C, and D. The normal calcium of the blood of healthy individuals remains quite constant at about 10½ milligrams per hundred cc. of blood. In the normal blood in the blood vessels, approximately 6½ milligrams of this is always free in the ionic form and 4 milligrams in a combined form with normal constituents of the blood, but 10½ milligrams go into ionic form in the serum when the blood is entirely clotted, the total calcium being the same before and after that process. Forces which tend to destroy this normal calcium balance, destroy a fundamental of the environment of the various cells and tissues, and, thereby, destroy one of their most important factors of defense. Yet there are many forces which tend to disturb this balance, one of the simplest and most common of which is nutrition, both by the starvation of the individual for the very calcium itself and for those elements which, by their reaction upon the glands of internal secretion, establish and maintain the calcium metabolism.

Another force seems equally important: namely, the toxic substance developed by streptococcal infection, particularly in conditions of low oxygen tension and putrefactive tissue. We have shown that by the injection of this substance, bacteria-free, into animals, the ionic calcium has been immediately lowered and the pathologically combined calcium directly increased; also that the long continued tying up of part of the available calcium of the body fluids brings about chronic or diseased states; that these diseased states develop in the organs and tissues whose defense has been lowered either by trauma, starvation, physical or mental overload, or by heredity; and in case there has been no physical force to determine what tissue will break first, very often, if not generally, heredity answers the question; and hence we have in one family the kidney breaking first, in another the heart, in another the joints, etc.; and we call it "Heart disease running in

the family." And if to the toxic neutralization of partly available calcium, we shall add an excessive or undue overload of demand for calcium, such as pregnancy, we have enormously aggravated the pathological state; and if, perchance, the individual is not taking enough calcium to maintain even a normal calcium balance, let alone supply a large and new demand for the growing fetus, it then develops to be more than an embarrassment but a real tragedy to the system, for the neutralized calcium of the toxic element reduces the available to far below the minimum that is possible for the maintenance of health, and the defense is broken. A physiological strain becomes a pathological lesion.

Before we can know the full answer to this difficult problem of the role of calcium there are several additional things we must know, among them the following:

To what extent is the disturbed ionic calcium a primary condition, and to what a secondary expression or symptom? I have shown in the various experimental chapters that the same gross clinical symptom may be present in two different individuals and one of them have an abnormally high ionic calcium and the other have an abnormally low ionic calcium. For example, of all the cases that present to me for study of their rheumatism, probably nine out of ten have a low ionic calcium and one in ten an abnormally high ionic calcium. This proportion is not based on analysis of data and is only relatively correct, but for our purpose answers for an illustration. The symptoms, as presented by the patient, would under casual observation seem to be similar. Yet these groups represent two entirely different pathological states. The group with the low ionic calcium tends to have a proliferative type of arthritis; the other tends to have a degenerative type. Similarly, of the various patients presenting with pathological changes resulting from reactions from irritants and infections about teeth, some will have very marked diminution of bone, again a degenerative type of reaction, and others will have a marked condensation of bone, corresponding with the proliferative type; and in these two types the ionic calcium of the blood is low in the group with the proliferative calcification reaction, and is high in the group with the degenerative type of reaction. We, therefore, see that we have comparable conditions in these two pathological states, which we have used to illustrate divergencies, or what might be taken to be anomalies. They are not anomalies but are evidence of disturbance of entirely different

types of disturbances in calcium metabolism and general tissue reaction. It is evident, therefore, that it is not so simple a matter as the mere presence or absence of ionic calcium of the blood, but it has to do with factors which relate to fundamental processes in which calcium is a factor but only one of several.

I have shown that several other factors are variable quite parallel to that of the variation in ionic calcium. One of these is the alkalinity index and another the bactericidal property of the blood and leucocytes. If the maintenance of the alkali reserve of the blood or any fluids or tissues of the body comes to be dependent upon the utilization of calcium, the symptoms will be entirely different, as in practice we find them to be, from those which obtain if this abnormal demand does not exist. Hence in periodontoclasia we have a very extensive wastage of organized calcified tissue to maintain a large factor of defense as alkalinity of the bathing fluids. The cost of the maintenance of the defense of the host is paid for in calcium currency which is taken from alveolar bone. We do not know what all these abnormal demands are, but some of them seem clearly to be the neutralization of imperfectly oxidized acids which are not reduced to carbon dioxide and eliminated as gas, but are neutralized in the blood stream and tissues by calcium in the absence of cheaper bases. A perfect combustion will reduce all of the food taken into the blood to carbonic acid gas, urea, and water. Intermediate acids will, therefore, have to be neutralized and will be excreted largely through the kidneys where they may be identified. The mechanisms, by which the alkali reserve is maintained in the body, have not been disclosed. There is a strong suggestion, however, that the parathyroids play an important part in this mechanism as well as in the neutralization of the toxic products of bacterial invasion. We do not yet have tests to determine the efficiency of parathyroid function. The clinical data that I have herewith presented, however, seems abundantly to demonstrate that in many individuals the administration of small quantities of parathyroid for a few days greatly assists in reestablishing a broken defense.

But these researches have thrown a very important new light on the nature of these pathological lesions which result as a systemic expression of a focal infection. They have demonstrated not only that various forces, such as heredity and overload, predispose and that the predisposition carries with it tissue specialization for localization, but also strongly suggest, if they

do not demonstrate, that after the bactericidins of the leucocytes are exhausted, defense itself for streptococcal infections is under certain conditions almost exclusively a local quality of the various fluids, tissues, and organs of the body; in other words, individual cells in the various organs and tissues make the fundamental last stage warfare against streptococcal infection in strong contrast, for example, with the antitoxin that is developed by the body for the general circulation as a defense against the toxin produced by the Löffler bacillus which produces diphtheria. There have been many clinical conditions to suggest that this was true before it was demonstrated, as, for example, organisms of the streptococcal group, which are biologically similar, produce a very wide range of systemic involvements, almost as wide as the assortment of organs and tissues of the body; and also by the local tissue reactions to stimulation, such as heat, massage, etc. We have, therefore, two factors which are paramount, if not the most important, in this combat between the organism and the host: First, *the almost unlimited power of adaptability on the part of the type of organism which develops in dental infections;* and, second, *the reacting capacity of the various tissues of the body.* One of our greatest difficulties in combating focal infections will therefore be the raising of the defensive mechanisms of local tissue cells in a host in whom they are by inheritance or acquirement depressed or absent. We see very little hope for changing the biologic characteristic of this organism to deprive it of its marvelous ability for adaptation. The two most hopeful methods are by more efficient vaccines and by the development of synthetic bactericidins.

CHAPTER LXXII.

GENERAL CONCLUSIONS.

INTRODUCTION

It is too early, because the information available is too limited, to make more than general conclusions, and these should be considered tentative until further data shall be available from as large a number of sources as possible.

Conclusions.

1. Dental infections are not local, oral problems.

2. Dental caries is primarily a local expression of a systemic condition in combination with abnormal local physical conditions.

3. Periodontal infections with periodontoclasia (pyorrhea, Riggs' disease) in the primary stages are fundamentally the expressions of a vigorous reaction to local irritation, combined with a systemic exaltation of the defensive mechanisms.

4. Calcium metabolism disturbances are fundamental factors in both dental caries and periodontal diseases, though dissimilar disturbances.

5. The absence or presence of susceptibility to systemic involvement from dental infections is fundamentally an inherent quality inherited as other unit characters are, or a matter of broken defense due to overload, or a combination of both.

6. Inherited susceptibility, or Mendelism, as applied to susceptibility of various organs and tissues, is a unit quality pertaining to individual organs and tissues independently of other organs and tissues.

7. Dental infections are fundamentally chiefly an expression of the biologic qualities of the host or culture medium rather than of the invading strain or organism.

8. The phenomena of tissue reaction is in many instances a true allergic reaction of antibody and antigen.

9. The so-called rheumatic group disturbances are in part symptoms of systemic sensitizations, an important factor in which is an inherited or an acquired calcium metabolism disturbance.

10. Calcium disturbances are themselves secondary to the acid-base and toxin neutralization governing mechanisms, one of which is parathyroid functioning.

These suggest as imperative, exhaustive researches on the following problems:

1. The fundamental factors involved in calcium metabolism.
2. The role of calcium and its physicochemic relations to dental caries.
3. The mechanisms of sensitizations of various types.
4. Determination of Nature's chief defensive factors for the neutralization of toxins.
5. Determination of the nature of the toxins developed in both apical and gingival infections.
6. The role of oral toxins in the development of tissue sensitizations.
7. Artificial substitutes for natural defense.

These will require hundreds of skilled workers with every convenience and assistance that can add to their efficiency, which will be discussed in the following chapter.

CHAPTER LXXIII.

RESEARCH INSTITUTES FOR DENTAL DISEASES.

Some great new biological facts have come to the knowledge of the best students of public health, which establish the conviction that a great many of the affections which we have looked upon as diseases are only symptoms (of which there are many), of a general systemic invasion by a strain of organisms residing protected in special tissues and against which the body is not capable of making a successful warfare which can culminate in their complete elimination. A distinguished scientist and world surgeon, stated in substance in my hearing recently that of the several hundred people in his audience it was his belief that, when they died, the final blow would be struck in nine out of ten cases by an organism which they would be carrying, at the time, as an apparently harmless invader so long as their resistance was high, but that it would wait its chance, and when their resistance was lowered sufficiently from any cause, it would strike and strike hard, perhaps not suddenly. He stated that he was figuring that the other ten per cent would die by accident.

What he was saying is the thing that we are seeing in various ways and do not recognize. For example, we do not realize, until we study the statistics, that in one in ten of all the funerals that go by, a life has gone out by premature failing of the heart, due to its being diseased. A very large number, though not quite so large, dies from kidney involvement; another large group from nervous system or lung complications produced by this same organism. It is estimated that more than ninety per cent of the heart involvements are produced by germs of the streptococcus group (diplo-streptococcus) which also produce nearly all of the rheumatic group lesions, including many of the kidney lesions and many of the fatal complications of nervous breakdown and pneumonia, also rheumatism, neuritis, appendicitis, gall-stones, etc. This is the germ that in more than ninety-nine per cent of cases is found in infected teeth, though other organisms may often accompany it; and it is the one, and usually the only one, found

in the lesions developed in animals by inoculating them with infections taken from the teeth. It is also estimated that in about ninety per cent of cases of streptococcal infection, it finds its entrance into the body from the teeth or tonsils; and of this ninety per cent, before six years of age, the tonsils play the most important part, but after six and eight years of age the teeth are the portal of entry in by far the largest proportion of cases.

Applying this, then, to the premature funerals that we see going to the cemetery from heart infection, the data available at this time seem clearly to establish that the teeth are by far the most important contributing factor. In other words, the available evidence today indicates that the *average* span of human life is shortened by years, because of the direct and indirect effects of dental disease; or stating it otherwise, if there were no dental diseases, the normal span of life for individuals in civilized communities would be many years more, than at present.

We have not said anything about the great scourges which make life less to be desired than death, such as acute inflammatory rheumatism and deforming arthritis which so often make their victims steadily turn into castings, bound in every joint, suffering in many and sometimes apparently in every nerve, and chained to a rack of torture, unable to feed themselves or do themselves either good or harm. Of this affection, Sir William Wilcox[6] has stated in a recent issue of a British Medical Journal (Jan. 13, 1923) that he agrees with Dr. Beddard that over ninety per cent of the cases of non-specific infective arthritis are due to infection arising from the teeth.

The progress of the past twenty-five years has brought about simply an awakening of a danger, but the great public is nearly as helpless as it has been in the presence of any of the plagues during the past centuries. Its members do not know where their danger is nor how to prevent it; nor can their guides, the members of the dental and medical professions, tell them, for the information is not available. So far as humanity is concerned, there are practically as many cases of periodontoclasia today as there ever were. This disease takes, as its toll, more teeth than most, if not all other dental diseases combined. It is not at all probable that one in a hundred of the citizens of the United States has either the information or the equipment to keep that disease under control; nor is it probable that one per cent of the dental profession could furnish the information and equipment adequate for so doing,

[6] See bibliography

certainly not five per cent. There is, today, as much or more dental decay, and statistics seem to indicate very much more, than ever before in the history of the world. This can be judged by the indelible records written in the skeletons for of all the tissues of the body the teeth last the longest and the cavity of decay will be present relatively unchanged, regardless of the age of the skeleton.

And why is it that with the efficiency of modern social organization and the greatly advertised dental science that all this has not been, and cannot be corrected in a few months or years at the most? First, because the universally accepted fundamentals of dental diseases and their symptoms are based on fundamental misconceptions or half truths; and second, because the amount of effort that is being made is so small, when compared to the enormity of the task, that it will take many generations before humanity, even in far advanced and cultured communities, can be saved as a mass. The present generation of dentists cannot solve this question for they have neither the fundamental education to make them capable (and many have not even the disposition to acquire it) nor the facilities with which to correct their misinformation and establish the facts. Dental diseases are so related to the special dental anatomy, physiology, and pathology that these problems must be solved by individuals with special training in both of these broad fields. Neither the medical profession alone nor the dental profession alone can solve them. There is little more general knowledge about the causes of dental decay and the causes of periodontoclasia today than twenty-five years ago, and very little more then than twenty-five years before that. In other words, during the thirty years that I have been in active dental research, not five per cent of the necessary new information has been acquired. I recently asked a distinguished dental educator how long he thought it would take before the dental colleges would be teaching an adequate and safe program of prevention, and his estimate was forty years. The medical profession has been trying for fifty years to solve the problems of dental decay and mouth infections and has made exceedingly little progress. This work must be done by men with a very broad training in the minute clinical and structural pathology of dental disease as well as of general medicine and the biological sciences. It will take several centuries to accomplish the solution of these problems at the rate we are going under the present arrangement of having

the research work done at night by men who are exhausted from the efforts of the day to earn the bread and butter for themselves and their families, either in dental practice or in preparing lectures and teaching dental and medical students. This work must be done in institutions in which every function and detail is adapted to the fundamental requisite of research on dental diseases.

This has been a physical impossibility in the past because there have been no institutions in which these great problems could be adequately studied. For example, it is estimated that there are funds available today for general medical research, as endowment, aside from equipped laboratories, amounting to over $250,000,000; while there is not $1,000,000 available as endowment, according to recent evidence, for research on dental diseases, which is a problem that is second to none in all the interests of humanity.

It is because of a realization of these important facts that I have so earnestly endeavored to create a spirit of research and to organize an adequately endowed institution and by assisting in so far as I can in organizing its work on an efficient and permanent basis, and start a new order of progress which will go forward with as much dispatch as possible. I have no doubt that in my dental practice, single-handedly, I have added several hundreds of years to the sum total of the efficient and comfortable life of my patients, and I am only one of forty thousand practicing dentists. I am very sure that my efficiency is far short of what it can be and will be for the coming, better informed, efficient members of the dental profession.

Hence, who can estimate the value in years that may be added to the comfort and life of the individuals of the nation in coming generations? Nor is this all. Much of the dentistry of today not only is not intelligently removing from individuals those sources of available infection which the undisturbed decay and gingival infection have produced, but many of the operations of the so much heralded American Dental Science are establishing and retaining the very conditions, which if Nature were undisturbed she would more readily throw off, for in spite of the splendid service of the majority, modern dentistry frequently takes infected roots and with elaborate structures anchors them solidly to other teeth. In this way incalculable harm may be done by some of the legally practicing members of the dental

profession. For some of these it is gross ignorance; for some, we are sorry to say, it is indifference plus ambition to make money as fast and as easily as possible. My observation is that a considerable number of the members of the dental profession of today do not want to hear the message that condemns the teeth upon which they desire to make operations. It is necessary for this and for other reasons, including politics and jealousies and institutional ambitions and pride, that for the greatest efficiency the institutions that will do the most fearless and aggressive dental research will be independent to function in every way that will best accomplish the attainment of new truth.

They should have as a minimum an available annual income for prosecuting their researches of not less than $50,000, and preferably much more than that amount. The former would be equivalent to an endowment of $1,000,000 at five per cent. Buildings adequate for housing the work in an efficient manner that would be represented by an annual budget of $50,000 would probably cost $150,000 or more, if built, especially for the work of brick or stone. This would not include equipment which would cost approximately $50,000.

In addition to developing the new truths which underlie both correct living and adequately improved medical and dental methods of practice, there must be developed a new type of practitioner. He will be neither a physician nor a dentist, nor both in the sense that he will be a combination of the two as they exist today. The science and art involved in the interpretation of the profoundly obscure and involved relationships, which may exist between the local and the systemic expressions of dental disease, can only be provided by men who have had a special training, quite unlike that that can be furnished by any dental or medical schools of today.

These researches, which I have recorded in this book, illustrate splendidly how neither the medical nor the dental profession has been able with its training and equipment of the past to diagnose, prognose, and treat these most intricately involved pathological interrelationships; and while we have arrived at the point where we can see the necessity for this new type of practitioner, we could not develop him today in any institution, available for teaching, that now exists. There must be developed both a new foundation of combined special medical and dental science and new methods of application.

The progress that has been made in the researches reported in this volume has been accomplished, largely, by changing the method of approach to this whole problem. In the past, effort has been made, mostly, to solve fundamental problems, etc., by either one of two chief methods, namely, the clinical or the laboratory point of attack. If I have made progress, it is because I have combined the two methods in one institution. Neither can ever accomplish it alone.

Efficient research institutes for dental disease must have exceedingly good clinics which will not only provide a great variety of types of associated local and systemic dental pathology, but a sufficiently large number of the different groups which may be considered comparable, to make possible the tabulation of data and thereby enable the research workers to trace the symptoms through the maze of confusions to their source; and these institutions must be so well equipped with trained scientists and the newest apparatus that it will be possible to apply all the available newer methods to these studies. Nor will it be sufficient to have great clinics and equipped laboratories manned by skilled scientists. They must have, and this is the most difficult of all to find, directing minds and hands whose vision is as far in advance of the teachings of the profession as it is possible to obtain. These men are rare and they can only be interested by furnishing an environment and equipment that supplies as nearly ideal working conditions as possible for a life devoted to scientific research. Such an atmosphere will not only attract men already possessing a well developed vision, but it will create such a vision in its developing staff.

Probably the greatest source of wastage in all world progress is the lack of understudies. Men climb through weary hours of almost endless struggle over the foothills to the watershed range, and just as they get to a point of vantage, where they can see somewhat of the probable course of the stream they are seeking to explore, they fall exhausted and a new explorer must start again at the foothills. We must keep pushing our advanced bases continually so that as little as possible of the ground that is gained will be lost, for the lifetime of any worker, at best, is short. Probably no worker in the field of dental bacteriology has ever climbed so high on the watershed as Professor Miller twenty-five years ago; nor has anyone arrived again at the milestone reached by Michaels in sialology twenty-three years ago. Therefore, the

competent research institutes for dental diseases would be organized not only to develop men for their own enlarging staffs, but men for going out to other institutions to build up similar work and, particularly, to man the dental colleges.

The most important change that must come in all the applications of dental science is in the viewpoint. Dentistry was born as a mechanical art. The whole attitude of medicine has been to treat it as such and the attitude of the dental profession, until recent years, has been to recognize it only as such. Before any dental operation whatever can be given even preliminary consideration, the problem of the tissue involved must be considered from the standpoint of human economy; and in that problem, the future as well as the immediate present must be considered. In the future it will not be: What mechanical art is dental science able to apply to a given broken or disfigured tooth? but, first of all, What is the relation of that affected member to the health and efficiency, as well as the comfort and appearance, of the individual? The dentistry of the future must be fundamentally based upon a foundation of pathology rather than of mechanical skill and art. No less art and skill will be needed in the legitimate restorations, but the operation of choice will not be decided on mechanical bases. Therefore, the dental colleges of tomorrow must have as their controlling motive, health and efficiency; and every motive, policy, and purpose, will first be decided on the basis of pathology; and I will make a prophecy that every dental school in the land will go out of business that is not organized upon that basis.

Accordingly, adequately organized research institutes for dental diseases will provide for very advanced postgraduate work on the fundamental knowledge of the relation of oral infections to systemic disease and the most advanced means for their application, since every operating dentist, no matter what his specialty, must be, primarily, a dental diagnostician unless he be so fortunate as to be associated with a group, some member of which is skilled in that important branch and is able to suggest the course that should be pursued. *It follows, therefore, that the organization of adequate institutions for most advanced investigation and most helpful professional assistance will have the following:*

(1) An ample endowment to make possible both a large and a permanent work;

(2) Adequate buildings, well lighted and well

located;

(3) Most up-to-date scientific equipment;

(4) A director with an appreciation of the problem from the standpoint of the patient, the healing professions, and the development of their sciences, the most advanced methods for scientific research, the needs of the scientist for his most efficient service, the skill in the organization of the clinic, the needs of teaching institutions, and familiar with methods of publication;

(5) A staff of skilled scientists, trained in the application of various branches of biological science; and

(6) Last, because it is first, a board of trustees with a love for humanity, which makes possible the consummation of this great work, and in whose hearts must come a joy that is known only by the world's greatest benefactors and is that one quality which makes man a superman because he becomes a coworker with his Creator.

BIBLIOGRAPHY

1. Dublin, Louis I.: Incidence of heart disease in community. Nation's Health 4:453-456, Aug. '22.
2. Maver, M. E., and Wells, H. G.: Biochemistry and chemotherapy of tuberculosis; chemical composition of calcified tuberculous lesions. Am. Rev. Tuberc. 6:649-658, Oct. '22.
2. Olitsky, P. K., and Gates, F. L.: Methods for isolation of filter-passing anaerobic organisms from human nasopharyngeal secretions. J.A.M.A. 78-1020-1022, April 8, '22.
4. Goadby, K. W.: Diagnosis of latent infection about the jaws. J.N.D.A. Part I, May, 1922, p. 371; Part II, June 1922, p. 504.

   Streptococcal infections arising from mouth. J. State Med. 30:415-423, Oct. '22.

   Importance of industrial medicine to community. Brit. M. J. 2:317, Aug. 27, '21.
5. Banting, Best, Collip, Hepburn, and Macleod: Trans. Roy. Soc., Canada 1922, Vol. 16, Sec. 5, p. 35.
6. Wilcox, Sir William: British Medical Journal, Jan. 13, 1923.
7. Pearl, Raymond: From Proceedings of National Academy of Sciences, Dec. 1919, Vol. 5, No. 12.
8. Libman, E.: Characterization of various forms of endocarditis. J. A. M. A., Vol. 80, No. 12.
9. Rosenow, E. C.: Mouth infection as a source of systemic disease. A. M. A. Jnl., LXIII, 1914. 2027. Disc. 2029-2032. Summary, XXXV, 1915, 4-6.

   Elective localization of the streptococcus from a case of pulpitis, dental neuritis and myositis. Ortho. Int. Jnl. II, 1916, 713-725, 16 illus., 1 table. Cosmos, LIX, 1917, 561-562. Abstract.

   The relation of dental infection to systemic disease. Allied XII, 1917, 400. Abstract. Cosmos, LIX, 1917; 485-491, 2 tables. Pacific D. Gaz., XXV, 1917, 612-620, 2 tables. Selected. Register, LXXI, 1917, 286-289. Abstract.

   The pathogenesis of focal infection. Cosmos, LX, 1918, 303. Abstract. N. D. A. Jnl., V, 1918, 113-124, 6 illus.

   Focal infection with special reference to oral sepsis. Minneapolis Dist. D. Jnl., II, Dec., 1919-20, 3-5.

   Studies on elective localization: Focal infection with special reference to oral sepsis. N. D. A. Jnl., VI, 1919, 983-1023, 46 illus. Disc. 1024-1029. Portrait, 982. Research Jnl., I, 1919, 205-267, 1 illus., 2 tables, 9 plates. Disc. pp. lxxii-lxxxi, 6 illus. Comment, 519-522.

   Elective localization and focal infection from oral sepsis. Register, LXXIII, 1919, 557-567. Abstracts. Brit. D. Jnl., XLI, 1920, 223-224. Abstract.

Elective localization of bacteria following various methods of inoculation, and production of nephritis by devitalization and infection of teeth in dogs. J. Lab. & Clin. Med. 7:707-722, Sept. '22.

and Meisser, J. G.: Nephritis and urinary calculi after production of chronic foci of infection, preliminary report. J. A. M. A. 78:266-267, Jan. 28, '22.

10. Billings, Frank: Focal Infection. New York: D. Appleton & Co., 1917, 1918.

Mouth infection as a source of systemic disease. Pacific D. Gaz., XXV, 1917, 261-262. Selected.

11. Hunter, W.: Coming of age of oral sepsis. Brit. M. J. 1:859, June 11, '21.

Oral sepsis as a cause of disease. London, Paris, N. Y. and Melbourne: Cassel & Co., Ltd. 1911.

The role of sepsis and antisepsis in medicine and the importance of oral sepsis as its chief cause. Register, LXV, 1911, 579-596. Abstract.

Oral sepsis in relationship to "Septic Anemia." Brit. D. Jnl., XXXV, 1914, 161. Disc. 161-163. Record, XXXIV, 1914, 144. Disc. 144-146. Selected.

12. Mayo, Charles H.: Mouth infection as a source of systemic disease. A. M. A. Jnl., LXIII, 1914, 2025-2026. Disc. 2029-2032. Amer. D. Jnl., XII, 1914-15, 407-412, 2 illus. Brit. D. Jnl., XXXVI, 1915, 122-124. Selected. Digest, XXI, 1915, 195-196. Selected. Ortho. Int. Jnl., I, 1915, 35-38. Abstract. Summary, XXXV, 1915, 1-4.

The relation of mouth conditions to general health (re care of school children). N. D. A. Jnl., VI, 1919, 505-512.

13. Wells, H. G., DeWitt, L. M., and Long, E. R.: The chemistry of tuberculosis. Williams & Wilkins Co., Baltimore, U. S. A. 1923.

14. Farrand, Livingston: Science review on "The Nation and its health." January, 1923.

COMBINED INDEX FOR VOLUMES I AND II

†PAGE

ABSCESS—See Lung

ABSORPTION
- apical, as related to danger . . . 68, 109, 121, 167, 630, **28**
  - extent of area not a measure . . . 630, **28**
  - related to high resistance . . . 630, **28**
- apparent or actual, not danger in a given infection . . . 176
- as an expression of dental infection in bone . . . 89
- at root apex should not determine diagnosis . . . 121
- extensive . . . 68, *69, *84, **132**
- gingival and apical, as related to systemic defense . . . 601
- hidden by other structures . . . 627, **25**
- of bone . . . 41, 68, 71, 79, 112, 124, *577
- of roots . . . 45, 112, *489
- periapical . . . 51, 77, 119, 126
- relative to extent . . . 167, 627, **25**
- tooth . . . *42, ***388**
- visible, and tooth infection . . . 121, *123, 629, **27**
  - absence of, even in presence of infection . . . *39, 122, 629, **27**
  - may have other causes . . . 629, **27**

ACID
- and alkali balance of blood . . . 542
- —base of blood as related to symptoms and treatment . . . *558
- —base relationships in blood . . . 262
- bases for neutralizing . . . 540, **402**
- calcium base for neutralizing . . . 540, *544, *547, **402**
- in dental caries . . . 361
- producing bacterium in caries . . . 133, 154, 636, **35**
- uric, in blood . . . 261

ACID-ALKALI BALANCE AND CALCIUM . . . 641
- dental infections disturb their relationship . . . 540, 546, 547, 641

ACID-BASE BALANCE . . . **363**
- and susceptibility to tuberculosis . . . **121**

ACID-BASE FACTORS . . . 555, *557, *561, **405**

ACIDOSIS . . . 546, 555, 633, **103**, ***106**, **122**, **229**, **245**, **31**

ADAPTABILITY
- streptococcal . . . 55, *57, **396**, **403**

ADHESIONS . . . **266**

ADRENALIN
- produces serious effect on patients with hyperglycemia . . . 426

AGE
- as a contributing overload which modifies defensive factors 265, 633, **31**
- as related to root-filled teeth and infection . . . **44**
- heart disease increases with . . . 265, **51**
- over 90 per cent of individuals forty-five years of age and over have dental infection . . . **51**

*Illustration or chart

†Plain face figures, Vol. I; bold face, Vol. II.

†Page

ALBUMINS . . . 241, **132**

ALCOHOL
as an overload to dental infections 282
used to determine ability of streptococci to adapt themselves to environment 61

ALIMENTARY TRACT AND ASSOCIATED ORGANS 285, *295, 318, **246**

ALKALI—See Acid
and acid balance of blood . . . 542
of saliva in dental caries . . . 359
reserve
and ionic calcium related to gingival infections . 241, 636, **34**
depression . . . *242, *259, 540, 555, *558, *561, **103**
of blood 633, **31**
of blood and saliva, in etiology of periodontoclasia . . . 354

ALKALINITY INDEX 241, 540, 555, **107**, **245**, **402**
and the relation of calcium to . . . *547
of blood . . . *557
relation of, to calcium . . *544, *561

ALLERGIC REACTION 364, *371, **404**

ALVEOLAR
bone, a cross section of *473
bone, streptococcal infection in . . 109, 113, **226**
destruction about infected roots . . . 112

AMEBA
deep in gingival tissue in region of periodontoclasia . . *412, *413
from abscess, which probably was caused by dental infection . *410

AN INTERPRETATION OF RADIATION REACTIONS 592

AMEBA AND SPIROCHETE INFECTIONS . . 409, *410, *411
may pass to other tissues . . 638, **36**
may produce systemic involvements . . 638, **36**
not usual 638, **36**

ANAPHYLACTIC REACTIONS
produced by sensitization reactions . 364, *371, 636, **35**

ANAPHYLAXIS—See also Sensitization
from dental infections 611
produced in animals by injection of toxic substance from teeth 373, 596

ANATOMICAL
complications in roentgenograms . . 48, 130
diagnosis, toxemia as cause of death . 63

ANATOMY
of the aorta, microscopic . . **61**

ANCESTRAL INVOLVEMENT 90, *93, **48**

ANEMIA **73**
secondary 241, **79**

ANESTHESIA
infiltration of, depends on supporting structures 475, 608
infiltrative in various groups of varying conditions 87
inspired mouth infection in . **128**
maxillary . 126

*Illustration or chart

†Plain face figures, Vol. I; bold face, Vol. II.

†Page

ANGINA PECTORIS *70, 93
dental infection involved in 71
heart involvement from 71, *72
kidney involvement from 71, *72
tooth implantation from case of 71, *72

ANIMAL—See also Implantations, Guinea-Pigs, Rats
best suited for sensitization tests 374
defense, determination of (study of blood chemistry and physical expressions of leucocytes) 504
experimentations, with dental infections, effect on ionic calcium of blood 607
inoculation, with various dental cultures and toxic substance from teeth, gain and loss of weight *404
passage
coccus only organism found in root canal infection . . 66
destroys organisms except diplococcus 56
makes infections more virulent 457
reactions and patients' symptoms *288

ANKYLOSIS
relieved *199, *200
typical illustration *499

ANTERIOR POLIOMYELITIS *273, 95

ANTRUM
continuation of pyorrhea pocket to 41
empyema of 261

AORTA
microscopic anatomy of 61

AORTIC ARCH LESION *297

APICAL REACTIONS AND PERIODONTOCLASIA
direct relationship between 150, 158, 167, 630, 28

APICAL RESORPTION
as related to danger 121, 167, 630, 28
extent of area not a measure 630, 28
related to high resistance 630, 28

APICES
of roots
different types of reaction involving 69
organism found when infected 66

APICOECTOMY 387
when it is a favorable operation for certain individuals . . 179

APPENDICITIS
acute 85, 252, *255, 261, 264
reproduced in rabbits 264, *265, 267
frequent attacks following dental operations 257

APPENDIX 246

ARSENIC
being used by dentists for devitalization of dental pulps? . . 131
causing necrosis in dog's mouth (supporting structures) . . 129
tends to be specific for treponema pallidum 329

*Illustration or chart

†Plain face figures, Vol. I; bold face, Vol. II.

†Page

ARTHRITIC
changes in external surfaces of tooth with calcified pulp . . *495
cripples and pregnancy overload 265, *153
involvement of dental attachments . . . 470, 486, *489, 128

ARTHRITIS See also Rheumatism . . . 116, *234, *292
and education 149
and heredity 193, *194, 195
and inherited susceptibility 150
and ionic calcium 192
and joint infection *173
arthritic knee . . . . . *Frontispiece B
Deforming *65, *174, *176, *177, 180, *181, *194, *198, 226, 264, 407
and heart involvement 96
and streptococcal pneumonia 128
and susceptibility chart *182, 183
bedridden 175
of dental infection origin 407
Degenerative *94, 185, *193, 225, 287, 296, *298, 401
in patients
causing dental involvements 486, 500
Deforming *185, 486
teeth from patient with *74, 487
Proliferative 73
in pregnancy 146, *148, 149, 192
in rabbits
Degenerative 70, *478, *479, 484
Proliferative 70, 73, *334, *476, *480
Purulent 37, 38
typical deforming 63, *64, *184, *197
involving teeth 128
multiple, may attack attaching membranes of teeth . . . 639, 38
normal knee . . . . . *Frontispiece A
of the spine *179, 236, *237, 238, *239
Proliferative 296, 401
Purulent *67, *178, 231, *232, *233, *234, 296
pulps of arthritic patients tend to become involved . . . 640, 38
Suppurative *373

ASPIRATION
from apical area showing giant cells 112
from dental fistulae to study contents 178
of infection 126
to compare blood count with patient's circulation . . . 47
to establish location of cyst 45

ASTHMA 132
and dental infection 133
may be produced by sensitization reactions . . 364, 636, 35

ATROPHY—See also Marasmus
of muscle 401, *403, 95, 280, *281
tissue, in rabbit after injection of dental culture . . . *402

AUTOGENOUS—See Vaccines
vaccines 82, 96, 175
AXILLARY GLAND INVOLVEMENT *67

BACILLUS
found after culture injected from original focus . . . 56

*Illustration or chart
†Plain face figures, Vol. I; bold face, Vol. II.

†Page

BACTEREMIA **108, 344**
means for diagnosing **62**
of dental origin **62**
streptococcal ***63, 343**

BACTERIA—See also Organisms, Strains
fortress for, environment produced by infected pulpless teeth 215, *223, 634, **32**
in a large proportion destroyed by granuloma ***468**
acid producing, in caries 358, 636, **35**
rarely shut out by root canal fillings 199, 229, 631, **29**

BACTERIAL
examination after medicaments are placed in root canals . . 190
examination of pulps of teeth with caries and no exposure . 138
flora in periodontoclasia 346
invasion
and pus affected by radiation 336, 635, **34**
causing elective localization 286
in dental infection 67
property which determines localization 303

BACTERICIDAL
content of blood, decreased, susceptibility to . 501, *516, 526, **82**
power of blood *531, *537
properties of individuals, marked difference . . . 640, **39**
property, marked difference in 501, **97**
property of blood . . *505, *506, *507, *511, 513, *516, 523, 529
property of blood, illustration of high and low defense . *516, ***102**

BACTERICIDINS 526, **125**

BASE
calcium, for neutralizing acids 540, **402**
for neutralizing acids 540, **402**

BEDRIDDEN
patients with deforming arthritis **175**

BIOLOGICAL
and morphological characteristics and local and systemic tissue expressions related 58
factors and Mendel's Law 589
qualities of organisms involved in root end infections . . 56, 66
units in dental focal infections (unicellular and multicellular) . 569

BLADDER
infection and cystitis ***165, *166**
infection of **163**
ulcer and cystitis ***272**
BLINDNESS ***326, *329, 331, *346**
progressive **344**

BLOOD
acid-base relation of, to symptoms and treatment . . . *558
acid-alkali balance of 542, 563
alkalinity index of *557
alkali reserve of, and clinical symptoms, related in the healing of sockets 352
and its defensive mechanisms 322, 529, 615
bactericidal power of *531, *537

*Illustration or chart

†Plain face figures, Vol. I; bold face, Vol. II.

†Page

BLOOD—(continued)
bactericidal property of *505, *506, *507, *508, *509, *511, *516, 523, 529
illustration of high and low defense . . . *516, ***102**
marked difference in . . . **97**
calcium . . . **87, 154**
as related to clinical conditions of individuals . . . 607
changes produced by infected teeth . . . *254, 328
chemical analysis, marked difference in . . . 241, **97**
chemical changes in, by implantations, and relation of ionic calcium to body weight . . . *257
chemical changes produced by dental infection . . . 241, 632, **31**
chemical constituents of, and systemic disturbance (sensitization) . . . 388
chemistry
abnormality of . . . 241, **84**
and physical expressions of leucocytes to determine defense . . . 504
and tuberculosis . . . **122**
as compared with dental pathology and systemic involvements . . . *242
need for . . . **245**
count
compared with general circulation . . . 47
of over 1000 animals discloses different strains of organisms which may produce different results . . . 234
culture . . . **62**
decreased bactericidal content of, and susceptibility to . . . 501, **82**
defensive factors of, variations in . . . 501, 640, **39**
hematological changes produced by dental infection . . . 234, 632, **31**
high pressure . . . **110**
produced by dental cyst . . . ***111**
hydrogen ion concentration of . . . 542
morphology, comparison of changes . . . *258, 560
of rabbits, morphological and chemical analyses . . . 545
response, tooth toxins compared with bacteria of tooth . . . 510
stream . . .
cultures . . . ***63**
infection of . . . **128**
seriously affected by toxic substance from irritant . . . 635, **33**
sugar in, see Hyperglycemia
vaccination *in vitro* . . . 501, 526, 529, ***99**
Walker Index of . . . 237

BLOOD-BORN INFECTION . . . **126**

BLOODSHOT . . . **341**

BONE
absorption of . . . 41, 68, 78, 89
alveolar
cross section of . . . *473
destruction of . . . 112
streptococcal infection in . . . **226**
changes, different types . . . 68, *70, *72, 470, ***241**
condensation of, and poor defense . . . 109, **53**
dense . . . 45, 74, 77
destruction, evidence of, whether teeth properly root filled . . . 199
maxillary, widened to develop bones of face . . . 436, *438
normal and pathological, roentgenographic appearance of *471, *472

*Illustration or chart

†Plain face figures, Vol. I; bold face, Vol. II.

†PAGE

BONE—(continued)
of rabbit, different types of reaction in 71
osteoid **391**, ***392**, **393**, ***394**
osteoid, filling in 139, 148, 499
radiopaque and radiolucent, as related to ionic calcium of blood 608
reconstruction, about apex 75
streptococcal infection in 487
surrounding roots (roentgenographic evidence of same) . . 77

BRAIN
cortex, lesion from dental infection ***278**, **279**
diseases **314**
fatty degeneration of, from dental infection **280**
infection ***295**
lesion, production in rabbits **325**
poor repair of **305**

BREATH
shortness of **45**

BRIGHT'S DISEASE
and dental infection *462, **155**

BULGING EYES **252**
and retinal hemorrhage ***336**

CALCIFICATION
and tubercular defense **121**
arrangement of structures *471
groups 68, 90, 109, **242**
of pulp 489, 490, *493, *494, *498, **227**, **242**
and arthritic changes in external surfaces . . *495
osseous, hyper, and hypo *70, *72, **242**
within pulps beneath caries . *137, *140, *144, *146, *147, 148, 152

CALCIUM—See Ionic, Blood
and acid-alkali balance 540, 641, **39**
dental infections disturb their relationship . . . 641, **40**
and the relation of alkalinity index to *544, *561
and whether or not we can tell if quantity is sufficient for body and blood stream 552
as it relates to alkalinity index *547
balance disturbed in various sera of body 586
base for neutralizing acids 540, **402**
changes in blood 241, 633, **31**, **154**
compound, studies to determine nature of 257
determinations of saliva and blood as related to dental caries . 358
determinations, variations in, as made by different methods . 248
ionic of blood
a factor in the healing of sockets 352
changes, compared with blood morphology, due to culture . *258
changes in and various determinations *534, 540
changes produced by infected teeth *254, 455
depends upon high or broken defense 431
depressed by implanting infected teeth *258
effect of treatment *251
low or high, depending upon conditions 261
of blood and saliva, important role in the etiology of periodontoclasia 354
of rabbit changed by implantation . . . 503, 587, 608
lack of, lowers defense to infection . . . 241, 638, **37**

*Illustration or chart

†Plain face figures, Vol. I; bold face, Vol. II.

†Page

CALCIUM (continued)
lactate given to raise ionic calcium of blood 433, *434, 535, 549
metabolism 59, **400**, **404**
and endocrine glands 421, **400**
considerations in connection with 551, 607
reserve in relation to pregnancy 265, **97**
rich diet 416, **85**
role of, in life and metabolism 609
should be increased during pregnancy 406
very low, case of 241, **79**

CANAL
Fillings
efficiency related to solvent 184, 631, **29**
rarely shut out bacteria 184, 631, **29**
reduction in efficiency of 184, 199, 631, **29**
relation of danger to activity of patient's defense 184, 199, 631, **29**
Medications
difficulty in sterilization 184, 631, **29**
frequent injury from 184, 631, **29**
overstrong medicaments 184, 631, **29**

CANCER
of stomach **269**
skin 392, *393, **355**

CARBOHYDRATE METABOLISM **362**
and dental infection 398, 637, **35**
may produce hyperglycemia and glycosuria 398, 637, **35**
may produce marked changes in 398, 637, **35**
probably injure Islets of Langerhans of pancreas 398, 421, 637, **35**

CARDITIS **133**
chronic, inherited susceptibility to 90, 285, *299 **79**

CARIES
and pulp infection 133, **47**
deep, pulp generally infected 629, **27**
moderate, pulp frequently infected 629, **27**
and systemic involvement 154
proportional, as related to symptoms 629, **27**
proportional, both as cause and effect 629, **27**
arrested, microscopic appearance of section *362
as calcium of the blood and saliva are related to it 358, 607
deep or moderate, may or may not involve pulps 133, 149
dental **404**
increase of **408**
etiological factors in 358
and acid-producing bacterium 636, **35**
and change in the chemical constituents upon bathing fluid 636, **35**
dependent upon reduction of hydrogen-ion concentration 636, **35**
irritating and causing pulp changes *140, *142, *143
related to
susceptibility in 681 individuals *155
susceptibility to rheumatic group lesions *155
systemic susceptibility *156
type of rheumatic group lesions *156
with pulp necrosis 134

CASTS
from dental infection *462, ***169**, **170**, ***171**

*Illustration or chart

†Plain face figures, Vol. I; bold face, Vol. II.

†Page

CATABOLISM
disturbed by accessory food factors and toxic substances . . 550

CECUM
invagination of **252**, *255

CELL
permeability 336, **213**
reaction, a study of 575
and Roentgen-ray treatments . . 593
resistance and proliferation . . .
caused by radiation 336, 635, **33**

CEMENTOSIS
hyper and hypo *244

CEMENTUM
ability to sterilize same by medication . . 188, 198
and dentin
repair in **391**, *392
repair rare **393**, *394, **395**
attacked and destroyed 481, *490

CENTRAL NERVOUS SYSTEM
disturbances **273**, **306**
reproduced in rabbits 265, 285, **273**

CHARACTERISTICS—See also Organisms
of dental infections and local tissue pathology related to degree of susceptibility 110
of morphology and biology and local and systemic tissue expressions 58
of organisms, biology 56, 66
of organisms, morphology 55, 66

CHARTS—See Table of Charts in front of book 285
for rheumatic susceptibility *318
showing inherited susceptibility *247
showing stomach involvement *260

CHAULMUGRA OIL
compounds used in periodontoclasia . . 349
injections *331, 333
used in the treatment of leprosy . . . 329

CHEMICAL
analysis of blood 241, **97**
basis for groupings 241, **123**
changes in blood 241
dental infections produce serious . . 241, 632, **31**
development of acidosis . . . 540, 555, 633, **31**
development of nitrogen retention . 241, 633, **31**
development of products of imperfect oxidation . 241, 633, **31**
increase in blood sugar 241, 633, **31**
increase in uric acid 241, 633, **31**
ionic calcium 241, 540, 633, **31**
presence of pathologically combined calcium . 241, 633, **31**
reduction of alkali reserve 555, 633, **31**
changes in caries 358, 636, **35**
means for increasing defense . . 329, 526
results encouraging 635, **33**

*Illustration or chart
†Plain face figures, Vol. I; bold face, Vol. II.

†Page

CHEMICALS—See also Medicaments
as a means for increasing defense *330

CHEMISTRY
blood 241, 540, 555
and tuberculosis 122
need for 245
shows abnormality 84

CHEMOTAXIS
a reaction of, with toxin *502, 620
as a means for increasing defense 329
results encouraging 635, **33**
caused by decrease of leucocytes for reaction from dental infections 532

CHILDREN
break earlier than parents 90, **50**
may die from heart disease from infected deciduous teeth . . **59**

CHILLING
as an overload 265, **283**

CHLORALHYDRATE
efficiency of, for the sterilization of infected teeth . . . 186

CHLORAMIN-T—See Chlorazene

CHLORAZENE (Chloramin-T)
efficiency of, for the sterilization of infected teeth 186, 188, 192, 208

CHLORINE
compounds, used in periodontoclasia 349

CHLOROFORM
dissolving gutta-percha for root fillings 202

CHLOROPERCHA
used in root fillings 200

CHLOROPHENOL
efficiency of, for the sterilization of infected teeth . . . 186

CHOLECYSTITIS 285, *295, ***253**, ***256**, ***258**

CHOLELITHIASIS 285, *295, **256**

CHOREA 285, 294, **314**, ***315**
and dental infection **57**, ***278**, **279**
of dental origin **312**, **313**

CHOROID
hemorrhagic infiltration into *293, **341**

CIRCULATION
disturbances, local and general, from dental infections . . 252

CIRCULATORY SYSTEM **54**
lymphatic circulation 519, **228**

CLINICAL
and physical conditions as related to the blood . . 248, 607
studies of tuberculosis **120**
symptoms and their relation to the removal of dental infections . 565

CLOTTING TIME
lengthened in rabbits 241, **77**

CLOVES, Oil of
efficiency of, for the sterilization of infected teeth . . . 186

*Illustration or chart

†Plain face figures, Vol. I; bold face, Vol. II.

†Page

Coccus
dominating organism found in dental tissues involved . . 56
only organisms found in root canal infection through animal passage 66

Cod Liver Oil **372**

Colds
recurring, and dental infection 364, *131, **132**

Colitis 285, *295, **258**
acute **250, 263**
spastic **386**

Colleges, Dental
responsibility of **53**

Colored Persons
more susceptible to heart disease **51**

Comfort
and safety **397**
as a symptom **210**
lack of reaction a danger constituting a paradox . . 631, **29**
local comfort not an index of safety 631, **29**
not a measure of safety **390**
of teeth, not a measure of success of operation . . . 210, 214

Community
and health problems **55**
causes of heart trouble one of most important . . . 285, **55**

Compensation
supreme, of dental practice **192**

Complications
of pregnancy 265, 406, **96**
tendency to **83**

Conclusions
regarding
calcium and acid-alkali balance of blood 553
changes in supporting structures of teeth, due to infection and irritating processes 485
chemical changes in blood by dental infections . . . 263
chemotaxis as a means for increasing defense 335
comfort and serviceability a measure of success of operation . 214
constancy and efficiency of root fillings 209
contributing overloads to defensive factors 382
dental infections
and pregnancy complications 406
and tissue and organ degeneration 567
causing marasmus 405
producing serious changes in blood and sera of the body . 240
dental involvements caused by arthritis 500
efficiency of root canal medications 198
elective localization
and organ defense 324
and tissue and organ susceptibility 308
environment provided by an infected pulpless tooth . . 316
etiological factors in dental caries 363
general 626, **404**
infection expressing itself in bone as absorption . . . 89

*Illustration or chart

†Plain face figures, Vol. I; bold face, Vol. II.

†Page

CONCLUSIONS—(continued)
methods for reinforcing a deficient defense 539
morphological and biological characteristics of organisms . 66
nature of discharge from dental fistula 183
nutrition and resistance to infection 420
pathology of gingival infections (periodontoclasia) . . 356
precancerous skin irritations 397
quantity, systemic effect, and tooth capacity 227
radiation effects on dental pathological lesions . . . 343
relation of
caries to pulp infections 149
dental caries to systemic disturbances 157
extent of absorption to danger 175
glands of internal secretion to dental infections and developmental processes 440
irritant to type of reaction 328
periodontoclasia to periapical absorption 166
periodontoclasia to pulp infections 153
periodontoclasia to systemic disturbances 162
relationships between local and systemic reactions . . 119
researches on dental infections and carbohydrate metabolism . 498
roentgenograms 54
roentgenograms deciding dental infection 132
spirochete, ameba, and other non-streptococcal infections . 414
susceptibility of individuals 108
the nature and function of the dental granuloma 468
the nature of sensitization reactions 391
toxic substance formed in pulpless teeth 233
variations in the defensive factors of the blood and serophytic microörganisms 523

CONDENSING Osteitis 68, 109, 167, **97**, **176**, ***177**, ***180**, **211**, **249**, ***288**, **627**
accompanying low defense ***101**

CONJUNCTIVITIS 285, *293, ***332**

CORTEX
of brain, lesion from dental infection ***278**, **279**

COUGH
streptococcal **113**

CREATIN
in urine and blood in humans and experimental animals . . 562

CREATININ
in urine and blood in humans and experimental animals . . 562

CREOSOTE
efficiency of, for the sterilization of infected teeth . . . 186

CROWN—See Gold

CRYING ***304**

CULTURE—See Medium, Blood, Dental, Pulp

CULTURE MEDIUM—See Media

CULTURES
aerobic and anaerobic, comparison of, in root-filled teeth . . 62
dental, injection of, kills fetal forms of rabbit *407
filtrate of, caused toxemia 63
from tooth and tooth toxin, comparison of *327

*Illustration or chart

†Plain face figures, Vol. I, bold face, Vol. II.

†PAGE

CULTURES—(continued)
infected, placed in pulp chambers 222
mixed, inoculated, recover generally coccal group . . . 519
whole, and washed organisms, comparison of 65

CYSTITIS **163**, *274
and bladder infection *165, *166
and bladder ulcer *272

CYSTS—See also Dental, Muscle, Ovarian, Vas Deferens
contents *222
mandibular *380
maxillary *381, *382, *384
membrane *220
presence established by examination of aspirated material . . 45

DANGER
and symptoms 167, 210, 641, 642, **40**
as apical absorption relates to it
extent of area not a measure 630, **28**
related to high resistance 630, **28**

DEATHS
caused in twelve hours by spontaneous hemorrhage *304, *305, 306, **85**, *86, *88
from heart disease *299
in children from deciduous tooth infection **59**
related to age and sex **51**
percentage from heart **407**

DECALCIFICATION
extending from caries to pulp *141, *142, *143
process 470, 486, **107**
and tubercular susceptibility **121**
surrounding periodontoclasia pocket 474

DEFENSE
affected by root canal fillings 215, 229, 631, **29**
against anaphylactic reaction to dental infection . . . 388
amount of, does not determine number of organisms destroyed . 620
and contributing overloads 265
and fistula discharge 177, 630, **28**
and ionic calcium 241, **121**
and its ultimate decline from root-filled teeth and infection . **44**
and local and systemic expressions 585
and local reaction 109, 167, **289**
as a factor in contributing overloads 265, 633, **31**
barricade of 442, **107**
broken
and influenza 265, **124**, **125**
and periodontoclasia 158, 344, **120**
and streptococcal invasion 265, **125**
by faulty nutrition 416
compared, patients and animals 227
comparison of high and low 90, **100**
deficient, methods for reinforcing 539, 640, **39**
vaccines 640, **39**
high, accompanied by periodontoclasia . . . 158, 344, *101
high and a vigorously functioning granuloma . . . *460, *461
high and low, and bactericidal property of blood 501, *511, *516, *102

*Illustration or chart
†Plain face figures, Vol. I; bold face, Vol. II

†PAGE

DEFENSE (continued)
high or broken, establishes ionic calcium of blood . . 431, 551
increased by chemical means 329, 635, **33**
local and systemic, mechanisms of 610
low, accompanied by condensing osteitis 109, ***101**
low and high in patients, comparison of roentgenograms . . *514
may be lost because of gingival infections . . 344, 636, **34**
mechanisms of
against organisms of cocci group 311
by which toxins are neutralized 65
which protect tissues and organs of individuals . . 614, 615
of individuals, active or broken 118, 527
of organs and elective localization . . . 285, 318, 634, **32**
of rabbits against dental culture by injection of medicaments . 329
of rabbits and rats, to implantations 522
poor, and condensation of bone 109, **53**
produces environment for organisms in dental focal infections . 572
provides in blood stream defensive factors suited to various tissues 322
quality of, and susceptibility of organs and tissues . . . 298
systemic, and the relation of gingival and apical absorption to . 601
to infection, lowered by lack of calcium and limitation of vitamins 241, 416, 540, 638, **37**
tubercular, and calcification **121**
type of operation indicated by, not symptoms . . 109, 210, 642, **40**
variations in the factors of, of the blood 503, 529

DEFENSIVE
Factors of blood, Variations in 241, 501
marked difference in bactericidal properties of individuals 501, *511, *516, 526, 640, **39**
this factor directly related to susceptibility classification 90, 640, **39**

DEFORMING ARTHRITIS **63**, ***64**, ***65**, **96**, ***174**, ***176**, ***177**, ***180**, ***181**, ***182**, **183**, ***194**, **226**, **264**, **407**
and streptococcal pneumonia 265, *269, **128**
bedridden patient **175**
of dental infection origin **407**
reproduced in rabbits *70, *72, ***184**, ***197**
susceptibility to 90, **198**

DEGENERATION—See also Diseases
fatty, of brain, from dental infection **280**
of pulp 215, 229, **250**, ***338**
of tissues and organs from dental infections . . . 567

DEGENERATIVE
arthritis . . . *70, **94**, **185**, **193**, **225**, **287**, **296**, **298**, **401**
myelitis **215**, **216**, **217**

DELIRIUM
from dental infection **322**

DENTAL
attachments, arthritic involvement of 486, **128**
caries 133, 154, 358, **404**, **408**
culture **57**
and heart involvement 285, *299, **57**
endocarditis in rabbits from 285, *299, **60**
exophthalmos produced in rabbits from . . 285, *293, ***339**

*Illustration or chart

†Plain face figures, Vol. I; bold face, Vol. II.

†PAGE

DENTAL—(continued)
from pulp infection produces endocarditis and rheumatism in rabbits *291, *299, **57**
osteomyelitis from *547, ***202**, ***208**
paralyzed rabbit from *273, 274, ***219**
spontaneous hemorrhage produced by . . . 285, *304, *305, ***340**
cysts—See also Cyst **219, 262, 263, 377, 383, 386**
and heart involvement ***378**
pathology of **385**
producing high blood pressure ***111**
related to heart block **73**
diagnosis and prognosis 90, 167, **350**
diseases, research institutes for **406**
granuloma, nature and function of 442
constitutes a quarantine station 639, **38**
name a misnomer 639, **38**
not a neoplasm 442, 639, **38**
overgrown ***223**
involvements, caused by arthritis 486
multiple arthritis may attack attaching membranes of teeth 486, 639, **38**
pulps of arthritic patients tend to become involved 486, 640, **38**

DENTIN
and cementum, repair in **391**, ***392**
as it relates to the surrounding structures (dentino-cemental) . 312
attacked and destroyed 481, *490
sterilization, when infected, by medication . . . 188, 198

DEPRESSION
psychic **285**

DERMAL—See also Skin
sensitizations developed in rabbits *390
test (extract of toxic substance taken from tooth) . . . *383
tests for sensitization, individuals responding to . . . 598

DERMATOSIS 364, 392, ***354**

DIABETICS
and periodontoclasia 241, 398, **103**
poor surgical risks **103**

DIAGNOSIS
and treatment, incorrect 109, **282**
dental, and prognosis 90, **350**
dental diagnosticians require great knowledge of human body 643, **41**
dental, in general practice (with or without visible absorption) . 121
for bacteremia **62**
importance of, in inherited susceptibility 90, **53**
marasmus, a symptom for 401, 637, **36**
of teeth of arthritic patient 494
what an adequate procedure involves 642, **41**

DIARRHEA
obstinate *295, **263**

DICHLORAMIN
efficiency of, for the sterilization of infected teeth . . 186, 188

*Illustration or chart

†Plain face figures, Vol. I; bold face, Vol. II.

†Page

DICHLORAMIN-T
efficiency of, for the sterilization of infected teeth . . . 193

DIET
deficiency
an overload to dental infections 416
as a study to determine whether or not dental infections are more injurious in individuals with same 419
effects of, to infection 416, 638, **37**
factors and ionic calcium changes in blood *534
milk, to raise ionic calcium of blood 435
normal and deficiency in rats to determine implantation effects . *521
rich in calcium 416, **85**

DIGESTIVE
tract disturbance in patients; variability in elective localization in rabbits *295
tract involvement 285, *295, ***255**
tract, may be disturbed by sensitization reactions . 364, 636, **35**

DIPHTHERIA
as an overload 265, **152**

DIPLOCOCCI
and streptococci, chief organisms growing in serophytic microorganisms 501, 641, **39**
found in dental tissues involved 56, 66
from arthritic joint ***292**
Gram-positive **82**
in smear from rheumatic joint *481

DISCHARGE
from abscess caused by dental infection *410
from fistula *178, *181, 630, **28**, **125**
constituted largely of neutralized products . . . 630, **28**
more safe than absence of reaction 630, **28**
pus may be an evidence of active defense . . . 630, **28**
purulent uterine 421, **139**, ***144**
relieved by removal of dental infection **144**

DISCUSSION
general . . . . . 569 to 643, **396**

DISEASES—See also Brain, Bright's, Dental, Heart, Hip, Pott's, Raynaud's, Rigg's
degenerative
and relationship between focal infections 97
developed from implantations 450
produced by dental infections 566, 622

DISPLACEMENT
of third molar ***262**

DOOM
impending **285**

DOSAGE
quantity of
in experiments, for comparison of infection . . . 215, 219
measured by injection of small glass tube in rabbits . 220, *223
to weight of rabbit, in elective localization 289
small, fatal (one-millionth of a gram) 215, 58

*Illustration or chart

†Plain face figures, Vol. I; bold face, Vol. II.

†PAGE

DRY MOUTH—See Xerostomia

DRY SOCKET
treatment of **347**

DYSPNEA **61**

EAR
involvements ***346**
pain in, of dental origin **345**

EDEMA ***66, 68**
of kidney **85**

EDUCATION
and arthritis **149**

ELECTIVE
localization **57, 85, 86, 88, 89, 264, 333**
and organ and tissue susceptibility, relation between . . 285
and organ defense 285, 318
diseased organs affect dental infections . . . 634, **33**
incompleteness of information 634, **33**
organisms influence organs 634, **33**
and organism quantity factor 229, 318, **59**
and tissue and organ susceptibility 285
definitely related to inheritance 90, 633, **32**
may be related to injury or lowered defense of involved tissue 265, 633, **32**
not destroyed in dental infection by removal of organ in question 318, 633, **32**
obeys laws of Mendelism . . . *100, *104, 633, **32**
organisms from dental infections may or may not have elective localization 285, 633, **32**
qualities found to be related to neither morphology nor sugar fermentation qualities 66
quality of a strain decreases *304, *305, *307
related to culture medium furnished by patient . . . 427

EMACIATION
as symptom of rheumatic group lesions 401

EMETIN
and Succinimid of Mercury injected for periodontoclasia . . 348
and Succinimid of Mercury injected (sensitization) . . . 365

EMPHYSEMA **128**

EMPYEMA
of antrum **261**

ENCAPSULATION—See also Granuloma
of infection *451, *453, *465, ***109**

ENCEPHALITIS **280**
epidemic lethargic 215, **323**, ***324**

ENDOCARDITIS 285, **61, 96, *105, 111, *386**
acute in rabbits ***56**
fatal ***58**
from dental infection, fatality from **57**
heart involvement and toothache 215, **55**
in heart of rabbit *548
in rabbits from dental culture **60**

*Illustration or chart

†Plain face figures, Vol. I; bold face, Vol. II.

†PAGE

ENDOCARDITIS—(continued)
in rabbits from pulp infection culture **57**
malignant **343**
pulpitis and heart involvement **55**
relation to dental infections **55**
relation to tonsils **55**

ENDOCRINE
glands and calcium metabolism 421, 540, **400**
system 421, **357**, **361**

ENDOWMENTS
needed **409**, **410**

ENVIRONMENT
accommodations of organisms to 55, **95**
for organisms in dental focal infections 571
furnished by an infected pulpless tooth 311
produced by infected pulpless tooth 311
host's only protection is exfoliation 634, **32**
is a fortress for bacteria within the host . 215, 311, 634, **32**
organisms may pass out, defensive factors cannot pass in 634, **32**
soluble poisions may pass out and nutrition may pass in 311, 634, **32**
protected, of a tooth 311, **95**

EPIDEMIC LETHARGIC ENCEPHALITIS 215, **323**

EPITHELIAL
structures, meaning and function of 460

ERYTHROCYTOSIS 234, *235
blood change produced by dental infection . . . 632, **30**
produced by tooth implantations *235

ERYTHROPENIA 234, *235, **79**
blood change produced by dental infection . . . 632, **30**
produced by tooth implantations *235

ETHYLHYDROCUPREINHYDROCHLORATE
injections *330
may have injurious effects on eyes when injected for pneumonia 333, 335
used in the treatment of pneumonia 329

EUGENOL
efficiency of, for the sterilization of infected teeth . . 190, 192

EUCALYPTOL
dissolving gutta-percha for root fillings 203
efficiency of, for the sterilization of infected teeth . . . 186

EVIDENCE
absence of 167, 210, **361**

EXCEMENTOSIS *76, **201**, **203**, **242**, ***330**
showing marked 76, 82

EXCRETORY
organs, kidney related to **155**

EXHAUSTION
physical and nervous, as an overload to dental infections . . 280
nervous **315**

EXOPHTHALMIC
goiter 421, ***359**, **361**

*Illustration or chart

†Plain face figures, Vol. I; bold face, Vol. II.

†Page

EXOPHTHALMOS **249, 252, 335, *336**
produced in rabbits from dental culture ***339**

EXPOSURE
as a contributing overload which modifies defensive factors 265, 633, **31**
as an overload to lower defense and increase susceptibility to dental infections 276, *277
as overload 265, **282**

EXTRACTION
rapid recovery after **87**

EYES
bulging **252**
bulging, and retinal hemorrhage ***336**
definitely improved by removal of dental infections . . . 112
high percentage of localization in, when process is acute . . *293
involvement **65, *66, 327, *329**
acute ***342**
in rabbit 285, *293, ***328**

FACIAL
neuralgia and neuritis, of dental origin ***348, 349**

FACTORS—See also Defense
contributing, to aid in diagnosis 97
Mendelian *100, 104

FEAR
as a contributing overload which modifies defensive factors 265, 633, **31**

FECES
and urine, lack of control of **273**

FETAL
forms dead following injection of dental culture into rabbit . *407

FETUS
may be affected by dental infections . . 406, *407, 637, **36**

FEVERS
infective, as overloads 265, **152**
yellow **95**

FIBROSIS ***99**
in pulps *136, *140, *142, *151, *152, 484

FILLINGS—See Root Canal Fillings

FILTRATE
inoculation **296**
of cultures inoculated into rabbits 62, 64, 66, 232

FISTULA
and putrescent pulp 177, **52**
discharge from *178, *181
quality of, depends upon stage of defense 179
discharge, nature of 630, **28, 125**
constituted largely of neutralized products . . . 630, **28**
more safe than absence of reaction 630, **28**
pus may be an evidence of active defense . . . 630, **28**
presence or absence of, not a measure of infection . . . 177
subjected to radiation in earlier days 336

*Illustration or chart

†Plain face figures, Vol. I; bold face, Vol. II.

†Page

FORMALIN
efficiency of, for the sterilization of infected teeth . 186, 192, 195
treatment in dog's teeth 129
used to determine ability of streptococci to adapt themselves to environment 59

FORMOCRESOL
efficiency of, for the sterilization of infected teeth . . 186, 192

FUNERALS
one in ten a heart case **53**
possible relation of dental conditions to same **53**

GALL-BLADDER
infection 285, *295, **110**, **252**, *253

GALL-STONES **246**
multiple 285, **257**, *258

General Summary and Restatement of Fundamentals . . . 626

GINGIVAL—See also Periodontoclasia, Infections
infections
a new meaning for 604
an extreme case with much free pus *577
their pathology and significance 344
a direct expression and direct measure of vital capacity 635, **34**
confusion between safety and absence of reaction . 636, **34**
high defensive capacity may be lost 635, **34**
relative to ionic calcium and alkali reserve . . . 636, **34**
results of loss of defense 636, **34**

GLANDS
axillary, involvement *67
circulating (leucocytes) 619
endocrine, and calcium metabolism . . 241, 421, 540, **400**
of internal secretion and dental infections 421
disfunction of, often corrected by removal of dental infection 638, **37**
similar lesions often produced in inoculated animals . 638, **37**
of internal secretions
as related to dental infections and developmental processes 421, 431
function improved by mechanical stimulation . . . 435
salivary, infection of **365**, *372
sublingual *369, *370, 371, *375
hypertrophied *373, *374, *376

GLYCOSURIA—See Sugar
may be produced by dental infection and carbohydrate metabolism 398, 637, **35**

GLOOM **285**

GOITER—See also Thyroid 421, **357**, *360
exophthalmic *359, **361**

GOLD
crowns and heart murmurs **52**

GRANULOMA—See also Dental
almost no vascularization *448
a physiologically acting tissue 501
a protective mechanism of *444, 458
compared with roentgenogram 39, 41

*Illustration or chart

†Plain face figures, Vol. I; bold face, Vol. II.

[Page

GRANULOMA—(continued)
comparison of, from patient and rabbit, latter caused by tooth implantation *453
degenerating *443, 458
destroys large number of bacteria present 467
highly vascular *446, 458
interpreted by some scientific men 447
showing extensive mass 48, 50, 51, *460
size of, is not measure of infection 442
types of, tested in suspensions of organisms and freshly infected culture media 459
vigorously functioning, patient with a high defense . . *460, *461

GRAPHIC
expressions
of ability of streptococci to adapt themselves to environment 59
of types of lesions produced by different strains of streptococci 71
of various types of streptococci 57

GRIEF
as a contributing overload which modifies defensive factors 265, 633, **31**
as related to root-filled teeth and infection **44**

GROUP
similarities, significance of 68, 90, **397**

GUANIDIN
relation of toxic substance in infected teeth and 562

GUINEA-PIG
immune to anthrax 286

GUMS
hemorrhage from 241, **73**

GUTTA-PERCHA
behavior of, in root fillings 201, *202

HEALING
of sockets after extraction 351, 475, 608

HEALTH
of patient versus service of teeth **52**
problems of community **55**
causes of heart trouble one of most important . . . **55**

HEART—See also Carditis, Endocarditis, Myocarditis, Pericarditis **97, 104, 105, *Frontispiece C**
and rheumatism 285, *288, *291, *299, **83**
angina pectoris ***70, 71, 93**
block, dental cysts related to **73**
disease ***299**
colored persons more susceptible **51**
deaths from, in children, from deciduous tooth infection . **59**
deaths from, increase rapidly after age of forty-five . . **51**
deaths from, per cents at different ages **51**
incidence of, increases with age **51**
over 90 per cent of individuals forty-five years of age and over have dental infection **51**
relation of sex to deaths from **51**
function versus tooth function **43**
high fatality rate **100**

*Illustration or chart

†Plain face figures, Vol. I; bold face, Vol. II.

†Page

HEART—(continued)
involved by types of streptococci 59
involvement *360
and deforming arthritis 96
and dental cyst *378
and heredity 90, 54
and streptococcal invasion 55, 54, 55
dental infection due to streptococci 54
in elective localization *299
may be better than expected 45
mitral murmur 50
severe, teeth in *90
showing in susceptibility study 90, *78, *164
lesions vary according to age of culture and kind of media . . . 73
murmurs and gold crowns 52
muscle, hemorrhage in *304, 85, *86
one in ten funerals a heart case 53
percentage of deaths from 90, 407
resistance and susceptibility 90, 48, *49
strong for, in susceptibility chart 90, *91
trouble (involvement) 84
and dental culture 90, 57
from angina pectoris 71, *72
one of most important health problems of community . . 55

HEMATOLOGICAL
changes in blood, produced by dental infections . 234, 632, 31
most frequent leucopenia, erythropenia, erythrocytosis, hemophilia 632, 31

HEMOLYSIS
produced by tooth toxins 510, *511

HEMOPHILIA 73, *74
blood change produced by dental infection . 285, *304, 632, 30
serious case of 252, 606

HEMORRHAGE
clotting time 77
lengthened in rabbits 241, 77
relation to dental infection 77
from gums 241, 73
in sclera *340
into heart muscle *304, 85, *86
into pulp as involvement *283, *67, 68
muscle *304, *305, *307, 85
postoperative 85
retinal 335
spontaneous . . . . . *267, *Frontispiece C
caused death in twelve hours . . *304, 306, 85, *86, *88
in kidney *76
in rabbit, causing death 306, *75
produced by dental culture 306, *340

HEMORRHAGIC
infiltration into choroid 341

HEREDITY—See also Susceptibility 398
and arthritis 90, *193, *194, *195
and heart involvements 90, 54
as a contributing overload which modifies defensive factors 265, 633, 31
laws of 590

*Illustration or chart

†Plain face figures, Vol. I; bold face, Vol. II.

†Page

HERPES **352**
oral ***375, 376, *377**
zoster **353**

HIGH BLOOD PRESSURE—See Blood

HIP
disease *70, *72, **289, *290, *291**

HISTAMINE
inoculation and reaction effects 374, *377, 562

HISTOLOGICAL
changes about teeth of arthritic patient *489, 490
sections of tissues (kind of organism) 56, *491

HYDROGEN DIOXIDE
efficiency of, for the sterilization of infected teeth . . . 186

HYDROGEN ION CONCENTRATION
caries dependent upon reduction of . . . 358, 636, **34**
identification for diplococcus 56
of blood 262
test of saliva to test improvement in periodontoclasia by radiation 339
of periodontoclasia pockets 351
of saliva, as it relates to dental caries 359
of urine *558, 586
of various fluids 542

HYPERCEMENTOSIS ***244**

HYPERGLYCEMIA—See also Sugar
and effect of disturbance of dental infections 426
may be produced by dental infection and carbohydrate metabolism 398, 421, 637, **35**
to the calcium factors 259, 398

HYPERTENSION. ***111**

HYPERTHYROIDISM 421, **357, *358**

HYPERTROPHIC
nodule on root (arthritic) *496

HYPERTROPHY
of kidney **161**
from dental infection ***169, 170, *171**

HYPOCEMENTOSIS ***244**

HYPOTENSION
relieved by removal of dental infection **73**

HYSTERIA ***316**

IGNORANCE
price of **59**
vanity of **50**

ILLUSTRATIONS—See Table of Illustrations in front of book

IMBECILE
patient, median suture opened *437, *438

IMMUNITY
characteristics of active and deficient *323
establishment of, in individuals 576, 604
from dental infections, phenomena of 615

*Illustration or chart

†Plain face figures, Vol. I; bold face, Vol. II.

†Page

IMMUNITY—(continued)
quality of, to systemic involvements 582, 610
to dental caries 363

IMPLANTATIONS (rabbit)—See also Tooth
effect of passing tooth from animal to animal 221
effects in depressing polymorphonuclears and increasing lymphocytes *238, *239
in rabbit produces abscess *454
of coin and its effect *225, *449
of infected teeth, chemical changes in blood and relation of ionic calcium and body weight *257, 587
of pieces of infected teeth in rats during pregnancy 408
of teeth 65, 219, 234, 258, 316, 338, 404, 414, *451, 456, 497, 503, 522, 560
of teeth and result on supporting structures 191
of teeth causing pneumonia *466
of teeth in rats, expel teeth *524
of teeth in rats (normal and deficiency test) *521
of teeth producing no irritations *463
of tooth with infected cementum killed rabbit *196
producing encapsulations about teeth . . . *451, *465, *467
reduced hemorrhagic myositis 85
subdermal *226
tooth, and pneumonia . . . 265, *269, 129, *130

INDIGESTION 246
nervous 246

INFANTILE
paralysis 95, 224

INFECTION—See also Ameba, Gingival, Pulp, Spirochete, Streptococcal, Tooth
acute ovarian, in rabbits 421, *137, *138
and root-filled teeth 184, 199, 44
as overload . . 265, *310
aspiration of . 126
blood-born 126
brain *295
capacity of root-filled teeth for 215
not necessary that quantity be large 632, 30
organisms may pass to other parts of the body . . 632, 30
soluble poisons may pass to other parts of the body . 632, 30
toxic substance may sensitize the body or special tissues 632, 30
encapsulated 442, *451, *109
in gall-bladder 285, *295, 110, 252, *253
inspired mouth, in anesthesia 128
nutrition and resistance to 416, 638, 37
of bladder 163
of bladder and cystitis *165, 166
of joint and arthritis . . . 285, *288, *291, *173
of lung and dental infections *269, *115
of muscle torticollis *205
of the bood stream 128
of tooth and sequestrum 107
oral, inspiration of 128
ovarian, tubal *146
in relation to syphilis 146
quantity of, in putrescent pulp 215, 52

*Illustration or chart

†Plain face figures, Vol. I; bold face, Vol. II.

†PAGE

INFECTION—(continued)
spinal *72, *275, *276, 277
streptococcal, in neck muscle 204
streptococcal, predisposes toward other attacks . . . 55
tubal 136, 139

INFECTION, Dental—See Tooth, Pulp
acute and chronic, as overloads to dental infections . . . 281
acute neuritis from 285, *288, *310
affected by diseased organs 318, 634, 33
and asthma 364, 133
and Bright's disease 398, 421, 155
and calcium and acid-alkali balance . . . 540, 555, 641, 39
and carbohydrate metabolism 398, 637, 35
may affect fetus and expectant mother . . . 406, *407, 637, 36
may produce hyperglycemia and glycosuria . 398, 421, 637, 35
may produce marasmus and loss of weight . . 401, 637, 36
may produce marked changes in 398, 637, 36
probably injure Islets of Langerhans of pancreas . 421, 637, 36
and chorea 215, 57, *278, 279, 312, 313
and deforming arthritis . . . *70, *72, 470, *476, *478, 407
and facial neuralgia and neuritis *348, 349
and glands of internal secretion 421, 638, 37
and insanity 285, 301
and lung infections 265, *269, *115
and mucous membrane inflammation 132
and nephritis *288, *290, 155
and pneumonia 265, *269, *130
and pregnancy complications 406, *407, *151
and recurring colds 364, *131, 132
and rhinitis 364, 131
and stroke 379
and tuberculosis 118
as related to endocarditis 285, *299, 55
changes in supporting structures, due to . . . 470, 639, 38
delirium 322
disturbances in other parts of body . 90, 285, 318, 627, 25
due to streptococci 55, 54
expressed as absorption 68, 628, 26
expressing itself in bone as absorption 89
expressions related to groups 68, 90, 628, 26
fatty degeneration of brain from 280
from dental infections, phenomena of 615
a factor in disturbance of various sera of the body . . 600
affect directly ionic calcium and acid-base balance of blood . 566
and causative factors in systemic involvements . . . 118
and etiological factors in rheumatic group affections . . 579
and local expressions *174, 569
and microörganisms involved therein 409
and systemic expressions *93, 581
as it expresses itself 109
causes break when individual is subjected to overload . . 284
changes produced in blood and sera of the body by 234, 240, 263
contributing to skin irritation 392
defense against, is decreased by faulty nutrition . . . 416
dental, contributed to by arthritis 500
extent of is not a quantitative measure of 574

*Illustration or chart

†Plain face figures, Vol. I; bold face, Vol. II.

†PAGE

INFECTION—(continued)
may or may not contain organisms with specific elective localization 310
removed and thyroid involvements subside rapidly 424
to determine quantity of in various cases . . . 215
to what extent does it contribute to degeneration of tissues and organs 555
tubercular, probably enters through cavities of dental caries 412
which is similar and varied reactions 69
which is similar in members of family tend to produce same type of tissue reaction 79
gingival 41, 577, 604
in individuals, as carriers, eliminated by removal of dental infections and caries 413
in over 90 per cent of individuals forty-five years of age and over **51**
in root canal fillings 209
in root canal grows coccus 66, 71
involved in angina pectoris **71**
lesion in cortex of brain from *278, **279**
local expression in different people 68, 628, **26**
may apparently not injure in absence of an overload 265, 633, **31**
may produce precancerous skin irritations . . 392, 637, **35**
may sensitize patient or may disappear with the removal of 364, 636, **35**
paralysis from . 265, *273, *274, ***271**, ***272**, ***274**, **275**, ***276**, **277**
periapical 41
caused by putrescent pulp 45
produces hematological and chemical changes in the blood 234, 241, 632, **31**
produces hypertrophy of kidney *169, **170**, *171
obscure 68, 109, 121, 167, **84**
oral, and influenza complications *267
osteomyelitis in patient from 540, *547, ***228**
reactions from near and distant parts of body on supporting structures of teeth 477
related to clotting time of blood 241, **77**
removal of, relieves hypotension **73**
removal of, relieves purulent uterine discharge *144
rheumatic neuritis from **280**, *281
sciatic neuritis from **282**
streptococcal 55, 627, **25**
with little or no absorption 68, *88, 167, 628, **26**

INFILTRATION
hemorrhagic, into choroid **341**

INFLUENZA
and broken defense 265, **124**, **125**
as a contributing overload which modifies defensive factors 265, 633, **31**
as an overload 265, **92**, **116**, **124**
as related to root-filled teeth and infection . . . *267, **44**
as the greatest overload to transfer absent to acquired susceptibility 282
complications and dental infections 265, *267
virus **126**
washings from nasopharynx (lung of rabbit) . . . *269, *271

*Illustration or chart

†Plain face figures, Vol. I; bold face, Vol. II.

†PAGE

INHERITANCE
and susceptibility 90, **404**
definitely related to elective localization and tissue and organ susceptibility 90, 318, 633, **32**
of susceptibility
90, **96**, **118**, **246**, ***247**, **261**, **283**, ***284**, ***286**, **317**, **329**, **360**
and arthritis **150**
for insanity 90, **301**
for stomach involvement 90, ***268**
striking illustration *93, *98, *100, *102, *104, **97**

Inherited Susceptibility and Mendel's law 589

INOCULATION
filtrate 229, *231, **296**

INSANITY **299**, **300**, **301**, **302**, **303**, **306**, **307**
and dental infections **301**
cured **309**
not related to dental conditions **309**
preventive measures as prophylaxis for **305**
susceptibility inherited for 90, **301**

INSTITUTES
research, for dental diseases **406**

INSULIN 398, 421, **363**

INTERNAL SECRETIONS—See Glands

Interpretation of Serological Studies 600

INTERPRETATIONS—See also Conclusions
bone absorption in dental infection in bone 68
comfort and serviceability as symptoms of success of operation . 210
dental, re medicated sterilization of infected teeth 184
disturbances from streptococcal infections 615
evidence of bone destruction and proper root fillings . . . 199
medical and dental, dental infection factor in systemic involvements 117
medical and dental, of organism involved 55
medical and dental, of roentgenograms 37, 121
medical and dental, re fistulae a measure of infection . . . 177
medical and dental, re flowing pus and systemic involvements 117, 181
of a new light on the phenomena of immunity and susceptibility to old and new 626
of inherited susceptibility and Mendel's law 589
of literature re injurious substances (bacteria) in pulpless teeth . 229
of non-dental diagnosticians on dental infections . . . 131, 167
of patient regarding judgment of operator placing filling over pulp 138
of professions and laity regarding the etiology of periodontoclasia 344
of radiation reactions 592
of systemic involvements as overwhelming natural defenses by quantity of dental infection. 215
of the dental granuloma by some scientific men 447
of the local phenomena of dental focal infection 569
of the mechanisms of local and systemic defense 610
of the phenomena of local reaction 573
of the phenomena of relationships between local and systemic expressions 585
of the phenomena of sensitization reactions 596

*Illustration or chart

†Plain face figures, Vol. I; bold face, Vol. II.

†Page

INTERPRETATIONS—(continued)
of the phenomena of systemic expressions of dental infections . 581
of the relation of gingival and apical absorption to systemic defense 601
of the relation of local tissue reaction to calcium metabolism . 606
serological studies 600
wrong diagnosis of case of neuritis 48

INTESTINAL
stasis *259

INTESTINES 285, *295, *258

INVAGINATION
of cecum 252, *255

IODIN
absence of, causes thyroid involvements 422
efficiency of, for the sterilization of infected teeth . . . 186
preventing pathological process of goiter 564

IODIN CREOSOTE
efficiency of, for the sterilization of infected teeth . . . 192

IODOFORM
in root fillings, environment for streptococci 60
saturated in alcohol
used to determine ability of streptococci to adapt themselves to environment 61

IONIC CALCIUM 87, 399, 401
and alkali reserve and gingival infections . . 344, 540, 636, 34
and arthritis 241, 192
and defense 241, 501, 540, 121
and kidney function 168
deficiency 540, 555, 229, 230
low 241, 84

IONIZATION
as a disinfectant through pulp canal 190, 197
used to test passing of medicaments from pulp chamber through dentin and cementum 313

INSULIN
injected into rabbits to reduce blood sugar 425, 550, 564

IRRITANTS
mechanical, Nature's reaction to 447, *449, *463, 575, 604
of skin (precancerous) 397
related to type of reaction 325, *327
two types present, bacterial and toxic 634, 33
toxic, seriously affects blood stream 635, 33
relation of, to type of reaction 328
skin, these may be produced by dental infections 364, 392, 637, 35

ISCHEMIA 172

ISLETS
of Langerhans of pancreas 363
probably injured by dental infection and carbohydrate metabolism 398, 421, 637, 35

JOINT
infection and arthritis 285, *288, *291, *173

JUDGMENT
need for basis for 93

*Illustration or chart

†Plain face figures, Vol. I; bold face, Vol. II.

†PAGE

KIDNEY
function and ionic calcium **168**
hypertrophy of **161**
from dental infection *169, **170**, *171
involvement *66, *167, **168**, *294
edema **85**
from angina pectoris **71**, *72
spontaneous hemorrhage in *76
susceptibility to 90, 285, 318, *156
related to excretory organs **155**
section, nephritic, with pus *160

LACTATION
a period which contributes to susceptibility to rheumatic group lesions 406

LAMINA DURA
abnormal condition of 45

LANGERHANS
islets of 398, **363**

LASSITUDE **45**, *316

LAWS
of Mendelism 95, 589

LESIONS—See also Tissues, Organs, Pathological
analysis of
of different rabbits, inoculated with, joint and muscle involvement *291
in elective localization *293, *295, *297, *299
aortic arch *297
brain, production in rabbits **325**
dental pathological, effects of radiation 343
prevalence of, in affected patients *104
relation of local to systemic *174
skin 364, *381, *385, 392, *393, **355**
special tissue, dominance of, in patients and families *104
spinal *273, *274, *190, *293
types of, produced by different strains of streptococci 71

LETHARGIC ENCEPHALITIS *324
epidemic 215, **323**
patient having same, implantation of in rabbits 414

LEUCOCYTES
as circulating glands which pass to every tissue of the body 619
capacity for reaction decreased by presence of dental infection 532
contain activating substance capable of inducing cell defense 395
from fistulae *182, *183
migration of, in a glass tube *502
type of, found in sockets of extracted teeth 351

LEUCOCYTOSIS
produced by tooth implantations *236

LEUCOPENIA **79**
blood change produced by dental infection *237, 632, **31**

LIVER *253

*Illustration or chart

†Plain face figures, Vol. I; bold face, Vol. II.

†PAGE

LOCAL—See also Expressions, Reactions, Relationships, Symptoms
expressions as related to systemic expressions 585
reactions
and defense 109, **289**
groupings on the basis of 68, 90, 109, 628, **26**
significance of inadequate 109, 167, **53**

LOCALIZATION—See Elective

LOSS
of memory ***320**, **322**
of sight **333**

LUNG
abscess and pulmonary tuberculosis **113**
infections and dental infections 265, *269, ***115**, **134**

LYMPH
and its defensive mechanism to take care of invading organisms 615
experiment with *520
human and animal, organisms growing in 519, 571

LYMPHATIC
circulation **228**
involvement **62**

MALIGNANT
endocarditis **343**

MALNUTRITION
as a contributing overload which modifies defensive factors 265, 416, 633, **31**

MARASMUS—See also Atrophy
a diagnostic symptom 401, 637, **36**
a symptom of rheumatic group affections . . . 401, *403
produced by dental infections 401, 637, **36**
relative to loss of weight 401, 637, **36**, **92**

MEDIA
artificial, organisms regrown in 56, 73
as an influence upon quality of elective localization 287, 308
determines type of tissue involved—not organisms . . . 75
great influence on organisms found in dental infections . . 66
kind in which organisms will grow 62
variations of, influence organisms 59, 73

MEDICAMENTS—See individual listing:
Adrenalin, Alcohol, Arsenic, Chaulmugra Oil, Chloralhydrate, Chlorazene, Chlorine, Chloroform, Chloropercha, Chlorophenol, Oil of Cloves, Creosote, Dichloramin, Dichloramin-T, Emetin, Eucalyptol, Eugenol, Ethylhydrocupreinhydrochlorate, Formalin, Formocresol, Guanidin, Histamine, Hydrogen Dioxide, Iodin, Iodin Creosote, Iodoform, Insulin, Succinimid of Mercury, Mercuric Nitrate, Mercurophen, Phenol, Quinine, Sulphuric Acid, Thymol, Thalium Sulphate, Trypsin, Zinc Compounds, Silver Compounds, Sodium Bicarbonate, Sodium Chloride, Rosin, Salicylates, Silver Nitrate, Salt of Ammonium Silver.
ability of, to maintain sterility of root dressing sealed in an infected tooth 186, *187
for sterilization (subdermal implantations) 227

*Illustration or chart

†Plain face figures, Vol. I; bold face, Vol. II.

†Page

MEDICATION
root canal 184
difficulty of sterilization 631, **29**
efficiency of, for sterilization 184
frequent injury from 184, 631, **29**
overstrong medicaments 184, 631, **29**

MEDIUM, CULTURE
five per cent of pulpless teeth after root filling may be . 215, **43**

MEMBRANE—See Mucous, Cyst

MEMORY
loss of *320, **322**

MENDELISM **404**
analysis of data to see evidence of 107
and inherited susceptibility 589
factors *100, *104, 583
illustrated 90, *100, *104, **314**
laws of 95, 589
obeyed by elective localization and tissue and organ susceptibility 90, 633, **32**
quality of organ and tissue susceptibility follows . . . 309

MENINGITIS
spinal **294**

MENSTRUATION
disturbed 285, *297, **135**

MENTAL
cloud **114, 283, 315, *316, 322**
deficiency in patient; median suture opened . . . *437, *438
irritability **87**
strain makes individual more susceptible to dental infections . 275

MERCURIC NITRATE
a drug used in periodontoclasia 349

MERCUROPHEN
efficiency of, for the sterilization of infected teeth . . . 186

MERCURY
Succinimid of,
amebacide and disinfectant, healing abscess 409
and emetin injected for periodontoclasia 348
and emetin injected for sensitization 365

METABOLIC
balance 555, **398**

METABOLISM—See Carbohydrate, Calcium
calcium, disturbed in sera of body 586
calcium, disturbed by accessory food factor and toxic substances 550
carbohydrate, as related to dental infections . . . 398, 427
changed by removal of dental infections 565
disturbed by toxic substance from infected teeth (marasmus) . 404
disturbed within host by toxic substance formed in pulpless teeth 233
process of 543

MICROORGANISMS—See also Organisms, Serophytic
of the mouth, growth factors of, in juices of living tissues . . 519

MICROSCOPIC
anatomy of the aorta **61**

*Illustration or chart

†Plain face figures, Vol. I; bold face, Vol. II.

†Page

MOLAR
third, displacement of . *262

MONGOLIAN
patient, median suture opened *437, *438

MORIBUND
condition and streptococcal pneumonia . 129

MORPHOLOGICAL
characteristics
changes in blood 236, 560
of organisms 55
related to biological characteristics and local and systemic tissue expressions 58

MORPHOLOGY
conclusions regarding 66

MOTHERHOOD
need for protection 406, 152

MOUTH
infection, inspired in anesthesia 128

MUCOUS
membrane inflammation and dental infection 132

MULTIPLE
arthritis 285, *288, 468, 639, 38
foramina, position of . 50
gall-stones 257, *258
pulp stones . 150, *151, *152, *338

MUSCLE
atrophy 401, *402, *403, 95, 280, *281
hemorrhage . . . 85
hemorrhage in heart muscle *304, 85, *86
infection, torticollis . *205
spasm . . 221
spasm, cyst in 217
system and skeletal system . 401, 172, *205
trapezius . *205

MYELITIS
degenerative 215, *216, 217

MYOCARDITIS
*Frontispiece C, 61, *80, 83, 85, 97, *98, 103, *105, 267, 289
in rabbit . *304, *548
new light on 83
prognosis more favorable 83

MYOSITIS 57, 203, *205, 215, 217
reduced hemorrhagic, from implantation . 85

NECK
involvement 116, *207, *219, *270
in rabbit 215
muscle, streptococcal infection in 204

NECROSIS
area of, in pulp tissue underneath caries 134, 149
in patient and in dog's mouth (latter caused by arsenic) . . 129
of spine *273, *274, *190
process of, in otherwise perfectly normal tissue . . . 611

*Illustration or chart

†Plain face figures, Vol. I; bold face, Vol. II.

†Page

NEOPLASMS
and cell function; radiation as treatment . . . 342
defined from granulation tissue . . . 447
dental granuloma not one . . . 442, *451, *453, 639, **38**
not around root but a protective membrane . . . 458
skin irritations . . . 392

NEPHRITIS . . . ***167, 168, 289, *294**
and dental infection . . . **155**
in kidney section, with pus . . . ***160**
interstitial . . . **161, *162**
parenchymatous . . . ***158**
produced by implanted tooth . . . ***159**
produced in a rabbit . . . ***157**
produced in rabbit by implantation . . . *452, *462
produced with infected tooth chips . . . **158**

NERVE—See also Tissue
degeneration of . . . **347**
tissues invaded by types of streptococci . . . 58, 59

NERVOUS
breakdown . . . **301, *302, 311, 312, *360**
exhaustion . . . **315**
indigestion . . . **246**
strain, as related to root-filled teeth and infection . . . **44**
system
and sense organs . . . **269**
breaks with acquired susceptibility caused by overload . . . 108
central, disturbances . . . *273, *274, **273, 306**
reproduced in rabbits . . . *273, ***271, 273**
culture from patient with symptoms of, inoculated into rabbit and produced arthritis . . . 73

NEURALGIAS
facial and neuritis, of dental origin . . . ***348, 349**
obscure . . . **347**
some cases furnishing explanation for so-called . . . 138

NEURITIS . . . ***117, 134**
acute . . . ***259, 311**
acute, from dental infection . . . ***310**
and facial neuralgia, of dental origin . . . ***348, 349**
looking for cause, teeth involved . . . 48
rheumatic . . . **283**
from dental infection . . . **280, *281**
sciatic, from dental infection . . . **282**
severe . . . **311**

NEUROSIS
psychic . . . **322**
vasomotor . . . **69**

New Light on the Phenomena of Immunity and Susceptibility to Disturbances from Streptococcal Infections . . . 615

NORMAL
conditions, various factors in, found in health and disease . . . 586

NUTRITION
and resistance to infection . . . 416, 638, **37**
effects of deficiency diets not quickly expressed . . . 416, 638, **37**

*Illustration or chart

†Plain face figures, Vol. I; bold face, Vol. II.

†PAGE

NUTRITION (continued)
lack of calcium lowers defense . . . 416, 540, 638, **37**
limitation of vitamines lowers defense . . . 416, 638, **37**
as it relates to localized community conditions . . . 419
faulty, as an overload to dental infections . . 279, 416, 583
in infected pulpless teeth, soluble poisons may pass out and nutrition may pass in . . . 311, 634, **32**

OBSCURE
neuralgia . . . **347**

ODONTOCLASTIC
reaction . . . **123**
and tubercular susceptibility . . . **123**

OPACITY—See also Radiopaque
shadow of, in roentgenogram . . . 48, 50

OPERATION, Dental
contributing overloads help decide . . . **45**
depending on quarantine . . . **44**
success of, measured by comfort and serviceability . . . 214
teeth filling in . . . **103**

OPERATIVE
risks, poor . . . 90, **103**

ORAL
herpes . . . **375**, *376, *377
infection, inspiration of . . . **128**

ORGANISMS—See also Bacteria, Strains
See individual listing: Ameba, Bacillus, Coccus, Diplococci, Spirochete, Staphylococcus, Streptococcus
accommodations of, to environment . . . 55, **95**
characteristics of, and the lesions they produce in dental infections . . . 569, 575
characteristics of, growing in infected teeth . . . 60
compared with strains . . . 56
dead, required to produce reaction in blood . . . 529
destroyed by blood of rabbit and patients . . *506, *507, *516
destroyed one wound by placing dressing on from another (defensive) factor . . . 506
effects of, without filtering or washing . . . 64
from dental infections, may or may not have elective localization 55, 285, 318, 633, **32**
grown from lesions developed in rabbits from dental infections still have elective localization qualities . . . 320
grown in lymph, animal and human . . . *520, 523
influence organs in elective localization and organ defense 318, 634, **33**
in infected pulpless teeth may pass out, defensive factors cannot pass in . . . 311, **634**
injured by toxic factors in culture medium . . . 230
in root-filled teeth . . . 62
invading, determines tissue reaction . . . 58
involved in root canal and root apex infection . . . 66
not capable of passing from pulp chamber through dentin and cementum . . . 314
of root-filled teeth may pass to other parts of the body 311, 632, **30**
producing toxic substances . . . *62
qualities of, influenced by variations of culture medium . 59, 66

*Illustration or chart

†Plain face figures, Vol. I; bold face, Vol. II

PAGE

ORGANISMS—(continued)
quality of, to elect certain type of tissue 290
quantity factor of, and elective localization . . 215, 229, **59**
role of infecting, in dental infections 615
sealed in pulp chamber 222
secured from dental tissues 55, 56
stained directly in the tubuli *217
used in making vaccines. 537
washed, and whole culture, comparison of 65
washed, injected into rabbit intravenously . . . *218, 229
washed, inoculated, causes structural changes 63

ORGANS
and their defense against invading organisms 615
and tissue involvement of groups 302
and tissue susceptibility and elective localization . 318, 633, **32**
defense, and elective localization 318, 634, **32**
excretory, kidney related to **155**
generative (elective localization) *297
internal, invaded by types of streptococci 59
sex, primary and secondary *297, **135**
structural lesions produced in 64
susceptibility of *300
to what extent do dental infections contribute to the degeneration of 555

ORTHODONTIC
pressure, cross section of tooth *482
procedures produce type of apical involvement due to trauma . 131

OSSEOUS
calcification *70, *72, **242**
spicules *72, **184**

OSTEITIS 627, **25**
condensing 39, 50, 74, 79, 82, 86, 88, 109, 111, *443, *471, *472, 486, **97, 176, *177, *180, 211, 249, *288**
accompanying low defense ***101**
rarefying 39, 50, 74, 84, 86, 109, 111, 627, ***180, 261**
and absence of rheumatic susceptibility **224**

OSTEOBLASTIC
activity and defense for tuberculosis **124**

OSTEOBLASTS
activity of *483, *491, *492
degenerating, beneath zone of caries 148
in process of removing alveolar bone in periodontoclasia . . *473

OSTEOCLASTIC
activity ***220, 390**
and tubercular susceptibility **121, 124**

OSTEOID
bone **391, *392, 393, *394**

OSTEOMALACIA **240**
and periodontoclasia **240, *241, *243**

OSTEOMYELITIS *547, **103, *200, 203, 209, 227**
bactericidal capacity of blood of patient with *537
chronic **191, 192**

*Illustration or chart

†Plain face figures, Vol. I; bold face, Vol. II.

†Page

OSTEOMYELITIS—(continued)
from dental culture *547, *202, *208
in patient from dental infection *547, *228
maxillary, roentgenogram of *547

OTHER
tissues 364

OVARIAN
cyst 112, *140, *141, *142, *143
reproduced in rabbits *429, *142
infection, acute, in rabbits *297, *429, *137, *138
involvements *136, 139
tubal infection *146
in relation to syphilis 146

OVARIES
as dental infections relate to them 425, 428, *429

OVERLOADS 265, 50, 92, 116, 118, 124, 211, 277, 316, 322
and pregnancy 406, 150
and arthritic cripples *153
and safety for root-filled teeth and infection 44
chilling 265, 283
contributing 265
chief contributing are: Influenza, Pregnancy, Malnutrition, Exposure, Grief, Worry, Fear, Heredity, and Age 265, 633, 31
to defensive factor 265
which modify defensive factors 265
dental infections may apparently not injure in absence of an overload 265, 633, 31
diphtheria as 265, 152
exposure 265, 282
help decide operation for root-filled teeth 199, 265, 45
infective fevers as 265, 152
infection 265, 301
influenza *267, 92
in patients, lowering defense 526, 583
pregnancy as 265, 406, 401

OXIDATION
imperfect, in blood 555, 633, 31

OXYGEN
tension, anaerobes are grown in 62
tension positive identification for diplococcus 56

PABULUM—See Media

PAIN
in ears, of dental origin 345

PALATE
obstruction of, in roentgenograms 48, 51

PALSY *310

PANCREAS 362
Islets of Langerhans of
probably injured by dental infection and carbohydrate metabolism *430, 637, 35
normal histology of, of rabbit *430
pathological histology of, of rabbit *430
substance from, injected into animals, lowers blood sugar 399, 425

*Illustration or chart

†Plain face figures, Vol. I; bold face, Vol. II.

[Page†

PARALYSIS **287**
from dental infection . . . *273, *271, *272, *275, *276, 277, *292
general *273, 188, *189
infantile *273, 95, 224
in rabbit from dental culture *273, 219
of sphincters 188, *189, 273
spinal *273, *274, *276

PARATHYROID
extract 421
administrations of benefit, stimulation of pituitary *437, *438, 639, 37
used to raise ionic calcium of blood of patient . 432, *434, 535
used to raise ionic calcium of blood of rabbit 535
removed from dogs 432
use of 85

PARENCHYMATOUS
nephritis *452, *462, *158

PARENTS
resistance of; children break earlier . . 90, *100, *104, 50

PATHOLOGICAL
lesions, dental, and radiation effects . . 336, 635, 33

PATHOLOGY
dental
as compared with blood chemistry and systemic involvements *242
of gingival infections 344, 635, 34
type, and susceptibility to tuberculosis 119
different conditions of 41
of dental cyst *451, 385
of gingival infections 356

PEPTIC
ulcer *251

PERIAPICAL
absorption 50, 51, *164
as it is related to periodontoclasia 163
involvement of root not sterilized by medicament (root dressing) 185

PERICARDITIS 62

PERICEMENTUM
destroyed 45

PERIODONTOCLASIA 250, 264, 404
accompanying high defense 158, 344, *101
ameba infection found near region of 412
and apical reactions, direct relationship between . 163, 630, 28
and broken defense 158, 120
and diabetics 344, 103
and its relation to pulp infections 150
and osteomalacia 240, *241, *243
and pulp infection 150
deep pockets, pulps generally infected . . . 150, 629, 27
moderate pockets, pulps frequently infected . . 150, 629, 27
and systemic involvement 158
reduced susceptibility to rheumatic group lesions 158, 344, 629, 27
when appearing, an acquired factor . . . 158, 629, 27
and tubercular susceptibility 119, 120
as related to periapical absorption 163

*Illustration or chart

†Plain face figures, Vol. I; bold face, Vol. II.

†Page

PERIODONTOCLASIA—(continued)
a study of the bacterial flora in 346
a study of the factors and types involved 348, 350
cessation of development of pus not a cure for the lesion . 338
condensing osteitis surrounding *471, *472
discussion of causes for 344
drugs most efficient in 349
extreme case of *477
pocket continuing to antrum 41
pockets, comparing elements contained therein . . 353
pockets of, deep or shallow, may injure pulp of tooth . 153
related to
susceptibility to rheumatic group lesions . . *159
systemic susceptibility *160
type of rheumatic group lesions . . *161
suppurative 344, **134**
treated by Roentgen-rays 593
treated with ultraviolet rays *339

PERITONITIS
streptococcal **264, 265, 266**

PERMEABILITY
of a tooth *315
of cell **213**

PHAGOCYTOSIS
from flowing fistula *182

PHENOL
efficiency of, for the sterilization of infected teeth . . 186
2% with organisms, in glass tube, injected into rabbit . *224
used to determine ability of streptococci to adapt themselves to environment 61

PHLEBITIS **108, *110**

PHOTOGRAPHS
comparison with roentgenograms . . . *42, *43, 47, *48, 50
of extracted teeth *43, *48, 51, *220

PHYSICAL
strain, as related to root-filled teeth and infection . . 199, **44**

PITUITARY
as it relates to development of the bones of the face . . . 436
benefited by parathyroid extract administrations 421, *437, *438, 639, **37**

PNEUMONIA **150**
and dental infection *269, ***130**
following implantation of infected tooth *466
streptococcal . . . *269, **113, 116, 124, 126, 127, 279, 282**
and deforming arthritis 265, **128**
and moribund condition **129**
recurring **129**

POLIOMYELITIS *273, **306**

POLYNEURITIS **398**

POSTGRADUATE
work **412**

POTT'S DISEASE *273, **236, *237, 238, 277**

*Illustration or chart

†Plain face figures, Vol. I; bold face, Vol. II.

†Page

PRACTICE
dental, supreme compensation of **192**

PRECANCEROUS
conditions 392, **118**, **267**
and sensitizations 392, **269**
causative factors of conditions of dental infections indirectly associated 613
of skin on nose 393
skin irritations 364, 392
dental infections may produce local sensitization reaction 364, 637, **35**

PREGNANCY
as a contributing overload which modifies defensive factors 406, 633, **31**
as an overload 265, **401**
complications . . . . . 406, **96**, *__151__, **152**, **185**, *__187__, **188**
and arthritis . . . . . 406, **146**, *__148__, **149**, **192**
and dental infections 406
and overloads 265, **150**
and arthritic cripples . . . . . *__153__
calcium reserve related to 406, 540, **97**
chronic systemic involvements begin with pregnancy 406, *407, 637, **36**
dental infections may affect the expectant mother 406, *407, 637, **36**
dental infections may affect the fetus . . . *407, 637, **36**
in animals, effect of dental culture 522
in rabbit lowered resistance, causing pneumonia and death *273, *274
lowers resistance and often favors development of rheumatism, heart involvement, etc. 268

PRESENT
generation immature **408**

PREVENTIVE
measures, as prophylaxis for insanity **305**

PROGNOSIS
and dental diagnosis 90, **350**
for myocarditis more favorable **83**
good **213**

PROGRAMS
intelligent one, value of **53**
preventive **45**
selection of **46**

PROLIFERATIVE
arthritis *70, *334, **296**, **401**

PROTEIN
compound produced by high temperatures, irritating or poisonous 467
effects from injection into animals 596
injected parenterally into animals 367
sensitizations in individuals 597

PSYCHIC
depression **285**
neurosis **322**

PULP CANALS—See Root Canals

*Illustration or chart

†Plain face figures, Vol. I; bold face, Vol. II

Page

PULPITIS—(See Chapter VII on Pulp Involvements)
and endocarditis . . . **55**
and streptococcal infection **57**
disturbances from 145, 149
produced by orthodontic pressure 481

PULPLESS TEETH
studies of . 229
environment produced by 311
host's only protection is exfoliation 442, 634, **32**
is a fortress for bacteria within the host 229, 311, 634, **32**
organisms may pass out, defensive factors cannot pass in 311, 634, **32**
soluble poisons may pass out and nutrition may pass in 311, 634, **32**
tooth toxins may produce very profound effects . 215, 632, **30**
tooth toxins tend to prepare tissues of host for infection 364, 632, **30**
tend to become infected 199, 229, **43**
they may contain 5 per cent of culture medium even after root filling 199, 215, **43**

PULPS—(See Chapter VII, Figures 65 to 80)
calcification of 490, *493, *495, **227**, **242**
canal, capacity of, for infection 218
capping, still more or less common 133
culture . . **84**
decalcification of *493
degenerated . . **250**
degeneration **338**
changes in, without caries . . 484
hemorrhage in . . . *483
infection of
and caries . . 133, 154, **47**
deep, pulp generally infected . 629, **27**
moderate, pulp frequently infected 629, **27**
and periodontoclasia . . 150, 629, **27**
as caries relates to them 149
as periodontoclasia relates to them . 153
culture produces endocarditis in rabbits 215, **57**
culture produces rheumatism in rabbits 215, **57**
involved, but not exposed, by deep caries *135, 136, 137
involvement, hemorrhagic . 285, 318, ***67**, **68**
may be injured by deep caries 133
of arthritic patients tend to become involved 470, 486, 640, **38**
of teeth not comparable as to quantity of infection . 69
pathology of 497
putrescent
and fistula 177, **52**
and history of soreness 177, **52**
and their quantity of infection 215, **52**
a study of root end infection . 574
related to acquired and inherited susceptibility *92, *93, *94, *95
with periapical involvement . . . 45, 57, *164
stones, multiple *140, *151, 492, **242**, **338**

PURULENT
arthritis *38, *44, ***67**

*Illustration or chart

†Plain face figures, Vol. I; bold face, Vol. II

†PAGE

PUS
flowing from decayed teeth may or may not have systemic expressions 117, 181
flowing from fistula is or is not dangerous 183
from hip joint *292
in nephritic kidney section *160
in urine *89
synonymous with virulent infected organisms (fistulae) . . . 177

PYELITIS *160, *294

PYORRHEA ALVEOLARIS—See Periodontoclasia

QUANTITY—See Dosage
and systemic effect 215, 160
factor
in fatality of rabbits *218, *290, 59
of organisms and elective localization 285, 59

QUARANTINE
adequate 108
against dental infections 578, 584, 593
dental granuloma 442, 639, 38
local, absence of *88, 442, 93
low capacity for maintaining 68, 43
dental operation depending on 109, 44

QUININE
in bark chewed by natives of Peru to fight malaria 329

RABBITS—See Implantations, Animal
acute appendicitis reproduced in 264, *265, 267
acute ovarian infection in 296, *297, *137, *138
blood of, morphological and chemical analyses 545
bone of, different types of reaction in 71
brain lesion production in *273, *274, 325
central nervous system disturbances reproduced in . *273, *274, 273
clotting time lengthened in rabbits 241, 77
deforming arthritis reproduced in . . *277, 285, *291, *184, *197
eye involvement in 285, *293, *328
nephritis produced in 285, *288, *290, *157
ovarian cyst reproduced in 285, *297, 142
paralyzed, from dental culture *273, *274, *219
quantity factor in fatality 215, 59
reproduction in 136
spontaneous hemorrhage causing death *304, 306, *75
torticollis in *214, *218
washings from crushed teeth fatal to . . 55, 215, 229, *231, 59
with endocarditis 285, 318, *56
from dental culture 215, 60
from pulp infection culture 215, 57
with exophthalmos produced by dental culture *339
with neck involvement 215
with rheumatism, from pulp infection culture . . 285, 318, 57
with typical deforming arthritis 285, 318, 63, *64

RADIATIONS
applied to neoplasms 337
effects on dental pathological lesions 336, 592
affect pus and bacterial invasion 336, 592, 635, 34
evidence cell resistance and proliferation . 336, 592, 635, 34

*Illustration or chart

†Plain face figures, Vol. I; bold face, Vol. II.

PAGE

RADIATIONS—(continued)
quite definite 336, 592, 635, **34**
some definitely helpful and some definitely harmful 336, 592, 635, **34**
from mercury vapor quartz arc 192
to determine clinical effects in periodontoclasia 338
to determine effects on blood calcium of normal rabbit *341
to determine effects on blood of normal rabbit *340
to determine effects on dental pathological lesions 343
reactions from . 592
tended to close fistulae; an early discovery 336
ultraviolet 192, *339

RADIOLUCENCY
and radiopacity 35, **176**

RADIOPAQUE
areas over roots 44, 471, 487

RADIUM—See also Radiation
used to terminate the tendency to malignant cell proliferation . 593

RAREFACTION
extensive zone of 50, 79
produced by local reaction adequate 584

RAREFYING
osteitis 68, 627, **25**, **180**, **261**
accompanying high defense 109, ***101**
and absence of rheumatic susceptibility . . . 109, **224**

RATS—See also Animal, Diet, Implantations
susceptibility to infection with the absence of vitamins . . 418

RAYNAUD'S DISEASE **69**

REACTIONS—See also Allergic, Anaphylactic, Apical, Local, Odontoclastic, Sensitization, Systemic
apical are less with decline of individual's defense against that infection 173
compared in gingival and apical irritants . . . 165, 603
compared in patients and in rabbit 73
comparing type of, in different members of same family *80, *81, *82
comparing type of, in individuals of various groups . . . 83
confusion between safety and absence of, in gingival infections 163, 344, 636, **34**
different types of, in bone of rabbit 71
from radiation 592
local, most important characteristic of local dental infections . 610
local, the phenomena of 573, 584
local tissue, found about teeth 110
measure of quantity and type 118
of infection from near or distant parts of body on the supporting structures of the teeth 477
periapical, of patient *180
relationships between local and systemic 113
sensitization, the nature of 391, 596
supporting structure changes, largely an expression of the capacity for 344, 639, **38**
type of, from food packs and gingival irritants . . . *161
type of, related to irritant 325
two types present, bacterial or toxic . . 325, 634, **33**
toxic, seriously affects blood stream . . . 325, 635, **33**

*Illustration or chart

(Plain face figures, Vol. I; bold face, Vol. II.

(PAGE

REACTIONS—(continued)
vary because different conditions occur at different periods (bone changes) 85
vary in individuals from similar dental infections 69

RECOVERY
rapid after extraction 325, 344 **87**

RELATIONSHIPS
between apical reactions and periodontoclasia . 163, 630, **28**
between local and systemic expressions 109, 628, **26**
groupings on the basis of local reactions . 68, 628, **26**
groupings on the basis of systemic reactions 90, 628, **26**

REPAIR
of brain, poor **305**
of cementum, rare **393**, *394, **395**
of dentin and cementum **391**, *392

REPRODUCTION
in rabbits **136**

REQUIREMENTS
for advanced investigation **412**, **413**

RESEARCH
institutes for dental diseases **406**

RESISTANCE
nutrition and, to infection 416, 638, **37**
effects of deficiency diets not quickly expressed . 416, 638, **37**
lack of calcium lowers defense . . 416, 501, 540, 638, **37**
limitation of vitamins lowers defense 416, 638, **37**
and susceptibility chart **48**
advantage of **48**
ancestral involvement **48**
children break earlier than parents . . *100, *104, **50**
involvements of members of family . 90, *93, *98, *102, **48**
nine cases of heart disease in same family . . . *49
of heart of Case 383, Figure 263 . . **48**, *49

RESPIRATORY
system **113**

RETINAL
hemorrhage **335**

RETINITIS *326, *329

RHEUMATIC
group lesions and systemic reactions 90, 628, **26**
dental infections are important etiological factors in . . 579
developed by complications of flu, pneumonia, or tuberculosis 265
faulty nutrition contributes to the susceptibility to . . 419
of individuals and relatives *93
pregnancy contributes to the susceptibility to . . . 406
related to dental focal infections (suscept. of patient) . . *102
susceptibility
as caries relates to it *155, *156, 157
as related to systemic involvement and periodontoclasia 158, 629, **27**
periodontoclasia relates to it *159
neuritis **283**
from dental infection **280**, *281
susceptibility **280**, **317**
chart for *318

*Illustration or chart

†Plain face figures, Vol. I; bold face, Vol. II.

†PAGE

RHEUMATISM *234, *373
acute 45, 57, 68, 116, 180, 195, 196, 207, 292
and heart 285, *288, 83
and ionic calcium of blood (arthritis) 541
effect on, by administering salicylates 532, *534
hereditary 90, 314
in rabbits from pulp infection culture . . 57
of patient, caused by dental infections . 47, 50
often brought on by pregnancy . . 268
types of streptococci in 58, 67

RHINITIS
and dental infection 364, *131
and sensitization 364, 596, *131
may be produced by sensitization reactions 364, 637, 35

RIGG'S DISEASE—See Periodontoclasia

RISKS
diabetics are poor surgical risks 103
poor, operative 103

ROENTGENOGRAMS
at different angles 41, *45, 48, 51, 53, 122
conclusions regarding 54
conditions not disclosed by . . 37, 41, 45, 47, 50, 54, *123, *124
compared with actual conditions 41, *44, *45, 47
comparison of, in reactions from similar dental infections . . 69
comparison with photographic . *42, *43, 47, 48, 50, 51, 220
density shown in, caused by surroundings . . . 41, 48
difficulty in securing—anatomical complications . . . 48
evidence in, of a vigorous reaction about the tooth . . . 84
evidence in, showing limited reaction, with or without condensing osteitis 88
from patients with a low and high defense . *451
of condensing and rarefying osteitis 86
of cysts 45
of pockets with gutta-percha points 41
of root fillings 45
of teeth involving a skin lesion *382, *394
of teeth of sensitization patient *369, *387
revealing infection . . . 37, 124
showing granulomata 41
used as a final decision as to diagnosis of infection . 132
what they will reveal 35, 627, 25

ROENTGENOGRAPHIC
evidence, absence of 35, 68, 62

ROENTGEN-RAYS
diminish flow of pus when infected teeth are exposed to . . 592
tended to close fistulae, an early discovery 336

ROOT CANAL—See also Root Fillings
half filled produces radiolucency without granuloma . . 77
infected cultures placed in 222
infection grows coccus 66, 71
medication
difficulty of sterilization 184, 631, 29
efficiency of, for sterilization 184
frequent injury from 184, 631, 29
overstrong medicaments 184, 631, 29

*Illustration or chart

†Plain face figures, Vol. I; bold face, Vol. II.

†Page

ROOT FILLINGS
are source of infection (conclusions) 227
efficiency of 41, 45, 199, 454, 486
efficiency related to solvent 199, 631, **29**
in infected teeth not sterilized by medication 187
low percentage of, not infected 209
molar **47**
of tooth show definite infection (definite case) . . . 194, *205
physical state and properties of materials used in . . . 199
projection of, after absorption of roots 45
rarely shut out bacteria 199, 631, **29**
reduction in efficiency of 199, 631, **29**
relation of danger to activity of patient's defense 167, 199, 229, 631, **29**
showing at different angles 51, 53
shrinkage *207
testing of teeth to determine when they are ready for . . 62
when favorable operations for certain individuals . . . 179
with iodoform 60

ROOT-FILLED TEETH
all under suspicion 167, 199, **45**
contributing overloads help decide operation . . 265, **45**
and subsequent infection 199, **44**
defense and its ultimate decline 167, 199, **44**
overloads and safety 167, 265, **44**
capacity for infection 199, 229
not necessary that quantity be large . . . 215, 632, **30**
organisms may pass to other parts of the body . 215, 229, 632, **30**
soluble poisons may pass to other parts of the body 215, 229, 632, **30**
toxic substances may sensitize the body or special tissues 364, 632, **30**
may contain 5 per cent of culture medium after root-filling 215, **43**

ROOTS
absorption of 45, 47, 112
crooked *47
density of, in roentgenograms 41
penetration of **47**
radiopaque area over 44

ROSIN
used with chloroform in root fillings 202

SACRO-ILIAC
involvement **134**

SAFETY
and comfort 210, **397**
comfort not a measure of 210, **390**
demands of 210, **52**
factor and structural changes about infected teeth . 210, 215, **52**
in root-filled teeth and infection 210, 215, **44**

SALICYLATES
administered for rheumatism (animal and human) . . . 532

SALIVA
and a study of its pH as it relates to dental caries . . . 359
a study of, as related to elements in periodontoclasia pockets . 353
ionic calcium of 541

*Illustration or chart

†Plain face figures, Vol. I; bold face, Vol. II.

PAGE

SALIVARY
glands, infection of 365, *372

SAPROPHYTIC
streptococci 343

SCIATIC
neuritis, from dental infection 282
rheumatism *308

SCLERA
hemorrhage in *340

SENSE
new truth a new sense 27, 344
organs and nervous system 269

SENSITIZATION—See also Anaphylaxis 132, 303
and precancerous conditions 364, 392, 269
and rhinitis 364, 596, *131
as related to precancerous skin irritations and dental infections . 392
by protein 367
dermal, developed in rabbits *390
in patient, produced by dental infections *371, *379
in patients, caused by curettement 364
produced in rabbits 365,*375, *376, *377
reactions 364, 392, 356
and a study of the dental pathology 388
nature of
dental infections may sensitize the patient . . 364, 636, 35
may disappear with the removal of dental infection 364, 637, 35
may produce a disturbance of the digestive tract 364, 392, 637, 35
may produce rhinitis or asthma 364, 637, 35
produce anaphylactic reactions 364, 636, 35
sensitizing substance may be very toxic . . 364, 636, 35
the phenomena of 596, 610
to tooth toxins *366

SEPTICEMIA
streptococcal 314

SEQUESTRUM
infected 69, 107

SEROLOGICAL—See also Blood, Saliva, Urine Studies
and local and systemic expressions 586
an interpretation of 600

SEROPHYTIC
microorganisms, diplo- and streptococci chief organisms growing in same 519, 641, 39

SEX
organs, primary and secondary . . . 285, *297, 135
relation of, to deaths from heart disease . . . 51

SHADOWS
objects causing 51
of opacity in roentgenogram 48

SHOCK
expressions of, due to acidosis 566

SIGHT
loss of *293, 333

*Illustration or chart

Plain face figures, Vol. I; bold face, Vol. II.

†PAGE

SILVER
compounds used in periodontoclasia 349
nitrate, efficiency of, for the sterilization of infected teeth 188, 192, 195
salt of ammonium 188

SIMILARITIES
group, significance of 68, 90, 109, **397**

SKELETAL
and muscular system **172**, *205

SKIN—See also Dermal **352**
cancer 392, *393, **355**
disturbances expressed as dermatoses . . . 378, *381, *385
irritations 364, 392, *393, ***354**
are contributed to by dental infections 392, 612
precancerous 392, *393
these may be produced by dental infections . . . 637, **35**
lesions 364, *381, *385, **355**
of rabbit from implantation of calcified root from arthritic patient *497

SLEEPINESS **298**, ***300**

SLEEPLESSNESS **96**, **264**, **298**, **299**, ***300**

SOCKETS
of extracted teeth, variation in healing . . . 351, 475, 608

SODA
bicarbonate of, to furnish to blood a cheaper base to neutralize pathological acids 456, 549

SODIUM CHLORIDE
suspension of strains in 64

SORENESS
history of, and putrescent pulp **52**

SPASM
of muscle 285, **221**
cyst in **217**

SPASTIC
colitis **386**

SPHINCTERS 188, *189
paralysis of **273**

SPINAL
arthritis *72, **236**, ***237**, **238**, ***239**
infection *72, *274, ***275**, ***276**, **277**
lesions ***190**, ***293**
necrosis *274, ***190**
paralysis *273, ***274**, ***276**

SPIROCHETE
and ameba infections 409
may pass to other tissues 638, **36**
may produce systemic involvements . . *410, *411, 638, **36**
not usual 638, **36**
from mouth entering body, may be rapid and severe . . *411

STAPHYLOCOCCI
found after culture injected from original focus 56

*Illustration or chart

†Plain face figures, Vol. I; bold face, Vol. II.

†Page

STERILIZATION
difficult by root canal medications 631, **29**
of infected teeth with medicaments 184, 195
whether complete, through pulp canal, destruction of peridental membrane 195

STOMACH
cancer 392, **269**
chart showing *288, 295, ***260**
inherited susceptibility for ***268**
involvement **84, 246**
lesion *304, **88**
perforated ***251**
ulcer ***248, 249, *251, *267**
with perforation **249**

STRAINS—See also Organisms, Bacteria
difference in pathogenicity 65
different, found in dental tissues 56
behavior of, from infected teeth 64
washed, suspended 64

STREPTOCOCCAL
adaptability 55, **396, 403**
and tubercular susceptibilities, difference in **119**
cough **113**
infection
and pulpitis . . . . . *Frontispiece, Vol. I, **57**
bacteremia ***63**
comparing defensive efficiencies of blood . . . 515
immunity and susceptibility to disturbances from . . 615
in alveolar bone **226**
in neck muscle **204**
in torticollis ***205**
predisposed **95**
predispose toward other attacks **55**
invasion
and broken defense 265, **125**
and heart involvement 318, **54, 55**
dental infections due to streptococci **54**
peritonitis **64, 265, 266**
pneumonia *269, **113, 116, 124, 126, 127, 279, 282**
and deforming arthritis **128**
and moribund condition **129**
recurring 265, **129**
septicemia **314**
susceptibility 90, **81, 92, 116, 129, 200, 316**
susceptibility inherited 90, **314**
temperature **113, 133**

STREPTOCOCCI
adapting themselves to environment **95**
and elective localization 285
and diplococci, chief organisms growing as serophytic microörganisms 519, 641, **39**
bacterial classification in relation to tissue affected . . . 57
biological qualities varied in 56
found in bone 487
found in dental infections involving root canals and apices and supporting structures 67, 71

*Illustration or chart

†Plain face figures, Vol. I; bold face, Vol. II.

†PAGE

STREPTOCOCCI—(continued)
graphic expressions in types of 57
organisms involved in dental tissues understood to be . 55, 627, **25**
present in root fillings with iodoform 60
saprophytic 519, **343**
strike last blow **406**

STROKE
and dental infection **379**

STRUCTURAL CHANGES
about infected teeth and safety factor . 109, 158, 167, 344, **52**
as basis for classifying characteristics of individuals . . . 89
disclosed in photographs 47
do not denote quantity or quality of infection 573
due to periodontoclasia 153
local 68, 109, 628, **26**
produced by small quantities of germs 63
related to systemic susceptibility *111
similar in members of a family 80
surrounding granulomata 51
which develop about infected teeth 580
which occur in the supporting structures of the teeth . . 470

ST. VITUS' DANCE 285, **315**

SUBLINGUAL
glands ***369, *370, 371, 375**
hypertrophied **373, *374, *376**

SUGAR
in blood 259, 400, 425
increase in blood 241, 398, 633, **31**
in urine 259, 398, 425

SUGAR FERMENTATIONS
biological properties and expressions in animal tissues not related 58
determine biological qualities of organisms in root end infection, show diplococci 66

SULPHURIC ACID
efficiency of, for the sterilization of infected teeth . . . 186

SUMMARY
general . . . . . 569 to 643, **39**

SUPPORTING STRUCTURES—See also Structural Changes
changes in, due to dental infection 344, 639, **38**
chiefly determined by the host 109, 639, **38**
largely an expression of the capacity for reaction 90, 109, 639, **38**
different types of reaction involving 69
effect on, by implantation of teeth in rabbits 191
injured to some extent by use of medicaments . . . 198, 208
necrosis of, in dog, with arsenic 129
structural changes in, due to infection and irritating processes . 470

SUPPURATIVE
arthritis *38, *44, ***373**
periodontoclasia 158, 344, **134**

SUSCEPTIBILITY
absent 90, 109, ***210**
absent, to putrescent pulps *168

*Illustration or chart

† Plain face figures, Vol. I; bold face, Vol. II.

Page

Susceptibility continued
acquired, patients, grouping lesions *86, *93, *111
acquired, to putrescent pulps *169
and contributing factors by modifying defense of individuals 265
and decreased bactericidal content of blood . . 501, 526, **82**
and inheritance 90, **404**
and resistance, chart *93, **48**
strong for hearts *102, *104, 318, ***91**
chart of deforming arthritis 90, ***182, 183**
classification and defensive factors of blood directly related 501, *514, *516, 640, **39**
comparison of the three groups of . . . *98, *100, 109, 213
inheritance of 90, **96, 97, 118**
and arthritis 285, 318, **150**
inherited . . . 90, **246, 261, 283, *284, *286, 317, 329, *360**
chart *93, ***247**
inherited, and Mendel's Law 589
inherited for insanity **301**
inherited, for stomach involvement . . . 90, 318, ***268**
inherited, importance of and diagnosis . . . 90, 109, **53**
inherited, of patients, grouping lesions . *88, *93, 105, 107, *111
inherited, streptococcal 90, **314**
inherited, to chronic carditis 90, 318, **79**
inherited, to putrescent pulps *170, *172
non, of patients, grouping lesions *84, *93, *111
of organs *300
of patient with rheumatic group lesions related to dental infections *102, 120, 583
organ and tissue, and difference between elective localization . 285
organ and tissue, and elective localization . 285, 318, 633, **32**
quality of, to systemic involvements 582
record, importance of and use 90, 109, **92, 209**
rheumatic **280, 317**
absence of in rarefying osteitis 109, **224**
chart for ***318**
streptococcal and tubercular, difference in **119**
study showing heart involvements . . 90, *78, ***164**
tends to develop systemic involvements according to family history 108
to caries, gingival infections, periodontoclasia, symptoms of infected teeth 91
to deforming arthritis 90, 318, ***198**
to dental caries 157, 358
to kidney involvement 90, 318, ***156, *167, 168**
to rheumatic group lesions
during pregnancy and lactation 406
not increased by periodontoclasia . . . 158, 344, 629, **27**
periodontoclasia related to same *159
to sensitization, periodontoclasia, skin irritations . . . 396
to streptococci 55, 90, **81, 92, 116, 129, *200, 316**
to tuberculosis
and acid-base balance **121**
and decalcification **121**
and odontoclastic reaction **123**
and osteoclastic activity **121, 124**
and type of dental pathology **119**
tubercular, and periodontoclasia **119**

*Illustration or chart

†Plain face figures, Vol. I; bold face, Vol. II

PAGE

SYMPTOMS
and danger 109, 167, 210, 215, 641, **40**
symptoms not a safe guide 167, 210, 641, **40**
type of operation indicated by patient's defense, not by symptoms 210, 642, **40**
as related to caries and systemic involvement . . 154, 629, **27**
clinical, and physical conditions as related to the blood . . 248
diagnostic, marasmus 401, 637, **36**
of an infected tooth 90
of comfort
lack of reaction, a danger constituting a paradox . 210, 631, **29**
local, not an index of safety 210, 631, **29**
of underweight 210, 401, **92**
patients', and animal reactions *288

SYPHILIS
and ovarian and tubal infection ***146**
an overload to dental infections 281

SYSTEMIC EXPRESSIONS—See also Reactions, Relationships
as related to local expressions 585
compared with chemical constituents of blood (sensitization) . 388
in dental caries 154
in periodontoclasia 158
of dental infections 48, 96
related to individual susceptibilities 108, 118
the phenomena of, and dental infections 581

SYSTEMIC INVOLVEMENTS
and caries 154
proportional, as related to symptoms . . 154, 629, **27**
proportional, both as cause and effect . . 154, 629, **27**
and periodontoclasia 158, 344
reduced susceptibility to rheumatic group lesions . 158, 629, **27**
when appearing is an acquired factor . . 158, 344, 629, **27**
and pregnancy 265, 406, 637, **36**
and quantity effect 215, **160**
as compared with blood chemistry and dental pathology . . *242
may be produced by spirochete and ameba infections 409, 638, **36**

SYSTEMIC REACTIONS
and rheumatic group lesions . . . 90, 109, 285, 318, 628, **26**
not uniform 285, 318, 628, **26**
related to groups 90, 628, **26**

TACHYCARDIA **114**, **358**

TEETH—See Root-filled, Pulpless
borderline 109, **81**
capacity of, for containing toxic and bacterial products . 367
crushed, washings from, fatal to rabbits . . . 215, 229, **59**
deciduous, delayed exfoliation **59**
different, in same individual, compared 73, 77, 227
filling in dental operations **103**
if comfortable, a measure of success of operation? 210, 214
infected, a study of the forces operating about root end . . 574
infected, boiled, effects of 457, 464, *465
infected deciduous can cause death in children from heart disease **59**
infected from blood stream 486, ***342**
infected, provide substance which combines directly with ionic calcium of blood 254, 510

*Illustration or chart

†Plain face figures, Vol. I; bold face, Vol. II.

†Page

TEETH—(continued)
infected, structural changes about and safety factor . 109, 470, **52**
involved by arthritis 486, **128**
justification for extraction of too many (mastication necessary) . 488
pulpless, furnishing environment for bacteria 311
pulpless, whether safe or not 227
section of, used as a permeable membrane *315
sockets, after extraction, variation in . . . 351, 474, 608
service of, and patient's health 210, **52**
testing, for root filling 62
when infected, must be dealt with as foreign substance . . 315

TEMPERATURE
streptococcal **113, 133**
subnormal **65**

TESTICLES
as dental infections relate to them 425, 428
inflammation of *147

THALIUM SULPHATE
used to determine ability of streptococci to adapt themselves to environment 61

The Local Phenomena of Dental Focal Infection 569

The Mechanisms of Local and Systemic Defense 610

The Phenomena of Local Reaction 573

The Phenomena of Relationships between Local and Systemic Expressions 585

The Phenomena of Sensitization Reactions 596

The Phenomena of Systemic Expressions of Dental Infections . 581

The Relation of Gingival and Apical Absorption to Systemic Defense 601

The Relation of Local Tissue Reaction to Calcium Metabolism . 606

THIRD MOLAR
displacement of *262

THYMOL
efficiency of, for the sterilization of infected teeth . . . 186

THYMUS 421
hypertrophy of *362

THYROID
disturbance of function of, may control factor in metabolism . 587
involved by lack of iodine in food 422
involvements subside by removal of dental infections . . . 424
pathological process of, prevented by iodine 564
removed from dogs 432

TISSUES
affected by types of streptococci 57
affinity—See Elective Localization
and organ involvement of (susceptibility) groups . . . *302
and organ susceptibility and elective localization 285, 318, 633, **32**
and their defense against invading organisms 615
degeneration of, to what extent do dental infections contribute? . 555
diseased, influence on organisms in distant focus . . . 318
granulation, comparison of rabbit and patient *453
granulation, nature of 445
may be affected by spirochete and ameba infections . 409, 638, **36**

*Illustration or chart

†Plain face figures, Vol. I; bold face, Vol. II.

†PAGE

TISSUES—(continued)
other **364**
proliferation of, normally and after extraction 355
reaction
local, as related to calcium metabolism 606
local, found about teeth 110, 458
related to factor other than type of organism . . . 71
structural lesions produced in 64

TONSILS
as they relate to endocarditis **55**

TOOTH
absorption 121, *42, ***388**
-ache and endocarditis 133, 134, **55**
a protected environment 311, **95**
chips, infected, produce nephritis ***158**
function versus heart function 133, 134, **43**
implantation and pneumonia 466, **129**, ***130**
implantation from angina pectoris **71**, ***72**
implanted, produces nephritis 452, 462, ***159**
infected and infected sequestrum **107**
infection and visible absorption 121, 629, **27**
structure, change in weight to determine capacity of tooth . . *216
toxin and blood calcium 241, 540, **87**

TORTICOLLIS **203**, **204**, ***207**, ***219**, ***270**
in rabbit ***214**, ***218**
muscle infection ***205**
streptococcal infection in ***205**

TOXICITY
in tissues, produced by organisms 62
preventing growth of organisms 60

TOXIC SUBSTANCE
formed in pulpless teeth disturbs metabolism in host . . 233
from irritant seriously affects blood stream 229, 234, 241, 635, **33**
from pulpless teeth 229
may produce very profound effects . . *230, 401, 632, **30**
tends to prepare tissues of host for infection . . . 632, **30**
from root-filled teeth may sensitize body or special tissues 364, 632, **30**
from teeth differs from histamine and guanidin . . . 562
from tooth and blood calcium 241, 540, **87**
in culture medium injurious to organisms. 230
involved in infection process 240
may sensitize body and tissues and produce reactions . . 228
of bacteria passes through dentino-cemental border . . . 316
produces tissue reaction in sensitized tissues 382

TOXINS
and bacterial invasion, injurious effects of 326
are neutralized and host maintains defensive mechanism . . 65
are produced by organisms growing in dental infections . 67, 569
from tooth and tooth culture, comparison of *327
from tooth, sensitization reactions to *366

TRAPEZIUS
muscle ***205**

TRAUMA
as type of irritation 131, 275

*Illustration or chart

†Plain face figures, Vol. I; bold face, Vol. II.

PAGE

TREATMENT
and diagnosis, incorrect 282

TRENCH MOUTH
shows fusiform and spirochetes 414

TRUTH
new truth a new sense VI, 27, 344

TRYPSIN
used to predigest organisms 539

TUBAL
infection *136, 139
ovarian infection, in relation to syphilis *146
ulcer *145

TUBERCULAR
infection probably enters through cavities of dental caries . . 412

TUBERCULOSIS
and blood chemistry 122
and dental infection 118
clinical studies of 120
defense for, and calcification 121
defense for, and osteoblastic activity 124
pulmonary, and lung abscess 113
susceptibility to
and acid-base balance 121
and decalcification 121
and odontoclastic reaction 123
and osteoclastic activity 121, 124
and periodontoclasia 119, 120
and streptococci, difference in 119
and type of dental pathology 119

ULCER
of bladder and cystitis *272
of eye *329
of stomach *248, 249, *251, *267
with perforation 249
tubal *145

UNDERSTUDIES 411

UNDERWEIGHT 280
as a symptom 401, 92

URIC ACID
increase in blood 241, 633, 31

URINE
and feces, lack of control of 273
pH of *558, 586
pus in *89

UTERINE
discharge, purulent 285, 318, 139, *144
relieved by removal of dental infection 144

VACCINATION
blood, *in vitro* 510, 526, *99

*Illustration or chart

†Plain face figures, Vol. I; bold face, Vol. II.

PAGE

VACCINES
a method for reinforcing deficient defense . . 526, 640, **39**
autogenous 526, **82**, **96**, **175**
organisms used in 537
used to build up defense . . . 431, 518, 528, 534, 539, 621

VASCULARIZATION
changes in, in peridental membrane and cementum of tooth . *147
destroyed *472
in sensitization rabbits *375, *376, *377

VAS DEFERENS
and cyst *140

VASOMOTOR
neurosis 69

VERTEBRAE
diseased *72, *273, *274, *190

VITALITY TESTS 62

VITAMINS 400
absence of, to produce various types of lesions 416
limitation of, in nutrition lowers defense to infection 416, *524, 638, 37

WALKER INDEX
expression of phases of blood morphology in 237

WASHINGS—See also Organisms
comparison of filtered and unfiltered *231, 325
from crushed teeth, fatal to rabbits . 215, 229, 59

WAXES
physical properties of 199, *200

WEIGHT—See also Dosage
depression of, as it relates to ionic calcium of blood . . . *257
loss of, by marasmus 401, 637, 36
of organisms 219, 223
of rabbit and size of dose as they relate to elective localization . *290
of tooth structure 216

WORRY
as a contributing overload which modifies defensive factors 265, 633, 31

XEROPHTHALMIA 365, 372, *373, *374, *376

XEROSTOMIA 365, *369, *370, 371, 372, 375
prognosis of, bad 372

YELLOW FEVER 95

ZINC
compounds used in periodontoclasia 349

*Illustration or chart

†Plain face figures, Vol. I; bold face, Vol. II.